Contents

1. History 1

2. Donor evaluation 7

3. Segment II / III graft 27

4. Left liver graft (including the caudate and the middle hepatic vein) 47

5. Right liver graft (including the middle hepatic vein) 53

6. The middle hepatic vein controversy 75

7. Biliary complications of right liver LDLT 89

8. Small-for-size graft and injury 107

9. Donor results 114

10. Recipient results 124

Index 136

Abbreviations

ALT	Alanine aminotransferase
AST	Aspartate aminotransferase
BMI	Body mass index
CT	Computed tomography
DDLT	Deceased donor liver transplantation
ERCP	Endoscopic retrograde cholangiopancreatography
ESLV	Estimated standard liver volume
ESLW	Estimated standard liver weight
HBcAb	Hepatitis B core antibody
HBIG	Hepatitis B immunoglobulin
HBsAb	Hepatitis B surface antibody
HCC	Hepatocellular carcinoma
HTK	Histidine-tryptophan-ketoglutarate
INR	International normalized ratio
IVC	Inferior vena cava
LDLT	Living donor liver transplantation
LHA	Left hepatic artery
LHD	Left hepatic duct
LHV	Left hepatic vein
LPV	Left portal vein
MRI	Magnetic resonance imaging
MELD	Model for End-stage Liver Disease
MHV	Middle hepatic vein
MPV	Main portal vein
MRCP	Magnetic resonance cholangiopancreatography
PELD	Pediatric End-stage Liver Disease
PTBD	Percutaneous transhepatic biliary drainage
RHA	Right hepatic artery
RHD	Right hepatic duct
RHV	Right hepatic vein
RPV	Right portal vein
VEGF	Vascular endothelial growth factor

Acknowledgement

The establishment of liver transplantation in Hong Kong owes enormous support to Professor John Wong, Head of Department of Surgery of the University of Hong Kong, and the Hospital Authority, Hong Kong. We are grateful for the world leaders of liver transplantation, who allowed us to observe and learn from their experience. They are Professor Russell Strong of the University of Queensland, Australia, Professor Nancy Ascher, Professor John Roberts and Professor Robert Lim of the University of California, San Francisco, USA, Professor Ronald Busuttil of the University of California, Los Angeles, USA, Professor Kazue Ozawa, Professor Yoshio Yamaoka and Professor Koichi Tanaka of Kyoto University, Japan, and Professor Masatoshi Makuuchi and Professor Hideo Kawarasaki of the University of Tokyo, Japan. We are also grateful for Professor P. Gertsch, who helped us in the initiation of our liver transplant program.

This book could not have been completed without the editing of Ms. Maggie Ho, drawings of Mr. T. T. Ng and, most importantly, our patients, from whom we have learned so much.

Contact

Professor Sheung Tat Fan
Department of Surgery
The University of Hong Kong
Queen Mary Hospital
102 Pokfulam Road
Hong Kong

Tel: (852) 2855 4703
Fax: (852) 2818 4407
Email: stfan@hku.hk
Website: http://www.ldlt.hk/

Contributors

John CHAN
MBBS, DMRD (UK), FRCR (UK), FHKCR, FHKAM (Radiol)
Honorary Consultant Radiologist, Hong Kong Sanatorium & Hospital, Hong Kong; Honorary Assistant Professor, Department of Diagnostic Radiology, Queen Mary Hospital, The University of Hong Kong, Hong Kong

Kwong Leung CHAN
MBBS, MS, FRCS (Glasg), FACS, FHKAM, FCSHK
Senior Medical Officer and Honorary Associate Professor, Department of Surgery, Queen Mary Hospital, The University of Hong Kong, Hong Kong

See Ching CHAN
MS, FRACDS, FRCS
Consultant and Honorary Clinical Associate Professor, Department of Surgery, Queen Mary Hospital, The University of Hong Kong, Hong Kong

Siu Tim CHEUNG
BSc (Hon), PhD
Assistant Professor, Department of Surgery, The University of Hong Kong, Hong Kong

Barbara CHIK
MBBS, FRCS (Edin), FCSHK, FHKAM (Gen Surg)
Associate Consultant, Department of Surgery, Queen Mary Hospital, Hong Kong

Alex CHIU
MB, FHKAM (Med)
Associate Consultant, Adult Intensive Care Unit, Queen Mary Hospital, Hong Kong

Vanessa DE VILLA
BS, MD (Philippines), PhD (Navarre), FPCS
Assistant Professor, Department of Surgery, Queen Mary Hospital, The University of Hong Kong, Hong Kong

Amy FUNG
BSocSc (First Class Hons), PGCert (Psychol), MSocSc (Clin Psychol), PhD
Head of Hong Kong West Cluster (Clinical Psychology) of Hospital Authority, Hong Kong; Head and Senior Clinical Psychologist, Department of Clinical Psychology, Queen Mary Hospital, Hong Kong

Wendy FONG
BNurs
Nurse Specialist, Operation Theatre Services, Queen Mary Hospital, Hong Kong

Theresa W.C. HUI
MBBS, FANZCA, FHKCA, FHKAM (Anesthesiol)
Consultant and Honorary Clinical Associate Professor, Department of Anesthesiology, Queen Mary Hospital, The University of Hong Kong, Hong Kong

Ching Lung LAI
MBBS (Hons), MD, FRCP (Lond), FRCP (Edin), FRCP (Glasg), FRACP, FHKAM (Med), FHKCP
Professor of Medicine and Hepatology, Department of Medicine, Queen Mary Hospital, The University of Hong Kong, Hong Kong

Banny LAM
BSc (Kinesiol)
Liver Transplant Coordinator, Department of Surgery, Queen Mary Hospital, The University of Hong Kong, Hong Kong

Brenda LAM
MSocSc (Clin Psychol)
Clinical Psychologist, Department of Clinical Psychology, Queen Mary Hospital, Hong Kong

Lai Kun LAM
MBBS, FRCSEd, FRACS, FCSHK, FHKAM (Surg)
Honorary Clinical Associate Professor, Department of Surgery, The University of Hong Kong, Queen Mary Hospital, Hong Kong

George K.K. LAU
MBBS, MRCP (UK), FHKCP, FHKAM (Gastroenterol & Hepatol), MD, FRCP (Edin), FRCP (Lond)
Assistant Dean, Faculty of Medicine, The University of Hong Kong, Hong Kong; Clinical Professor in Gastroenterology and Hepatology and Honorary Consultant, Department of Medicine, Queen Mary Hospital, The University of Hong Kong, Hong Kong

Evelyn LEE
RN, MSN
Transplant Coordinator, USC Liver Transplant Program and Center for Liver Disease, University of Southern California, USA

Libby LEE
MBBS, FHKCA, FHKAM, FANZCA, Dip Pain Mgt
Associate Consultant and Honorary Assistant Professor, Department of Anesthesiology, Queen Mary Hospital, The University of Hong Kong, Hong Kong

Peter W.H. LEE
PhD, AFBPsS, FHKPS, JP
Professor and Consultant Clinical Psychologist, Department of Psychiatry, Queen Mary Hospital, The University of Hong Kong, Hong Kong

Chi Leung LIU
MBBS, MS, MD, FRCS (Edin), FACS, FCSHK, FHKAM (Surg)
Honorary Professor, Department of Surgery, Queen Mary Hospital, The University of Hong Kong, Hong Kong

Chung Mau LO
MBBS, MS, FRCS (Edin), FRACS, FHKAM (Surg), FCSHK
Chin Lan Hong Professor in Hepatobiliary and Pancreatic Surgery, Department of Surgery, Queen Mary Hospital, The University of Hong Kong, Hong Kong

Ying LUO
MS, PhD
Associate Professor, Division of Hepatobiliary Surgery, Department of Surgery, General Hospital of P.L.A, Beijing, China

Kwan MAN
MBBS, MS, PhD
Assistant Professor, Department of Surgery, The University of Hong Kong, Hong Kong

Irene Oi-Lin NG
MBBS, MD, PhD, FRCPath (UK), FHKAM (Pathol), FHKCPath
Professor and Director of Liver Cancer and Hepatitis Laboratory, Department of Pathology, Queen Mary Hospital, The University of Hong Kong, Hong Kong

Kelvin Kwok-Chai NG
MBBS, MS, PhD, FRCSEd (Gen), FHKAM (Surg)
Consultant and Honorary Clinical Associate Professor, Department of Surgery, Queen Mary Hospital, The University of Hong Kong, Hong Kong

Wai Man NG
MBBS, FRCSEd, FCSHK, MMedSc, FHKAM (Surg), FACS
Consultant and Honorary Clinical Associate Professor, Department of Surgery, Queen Mary Hospital, The University of Hong Kong, Hong Kong

Tony W.H. SHEK
MBBS, FRCPA, FHKCPath, FHKAM (Pathol)
Consultant Pathologist and Honorary Clinical Assistant Professor, Department of Pathology, Queen Mary Hospital, The University of Hong Kong, Hong Kong

Paul K.H. TAM
MBBS, ChM (Liverpool), FRCS ad eundem (Eng), FRCS (Edin, Glasg & Ire), FHKAM (Surg), FCSHK, FRCPCH
Chair Professor of Pediatric Surgery and Chief of Division of Pediatric Surgery, Department of Surgery, Queen Mary Hospital, The University of Hong Kong, Hong Kong

Wai Kuen TSO
MBBS, DMRD (Lond), FRCR (UK), FHKCR, FHKAM (Radiol)
Consultant Radiologist, Chief of Service and Honorary Clinical Associate Professor, Department of Diagnostic Radiology, Queen Mary Hospital, The University of Hong Kong, Hong Kong

Nai Shun TSOI
MBBS, MRCP (UK), DCH (Lond), FRCP (Edin & Glasg), FRCPCH (UK), FHKAM (Ped), FHKCPed
Consultant Pediatrician and Director of Pediatric and Neonatal Intensive Care Unit, Department of Pediatrics and Adolescent Medicine, Queen Mary Hospital, Hong Kong

William Ignace WEI
MBBS, MS, FRCS, FRCSE, FRACS (Hon), FACS, FHKAM (Surg), FHKAM (ORL)
Li Shu Pui Professor of Surgery and Chair in Otorhinolaryngology, Division of Head and Neck Surgery, Department of Surgery, Queen Mary Hospital, The University of Hong Kong, Hong Kong

Yik WONG
MBChB, FRCR (UK), FHKAM (Radiol)
Associate Consultant and Honorary Assistant Professor, Department of Diagnostic Radiology, Queen Mary Hospital, The University of Hong Kong, Hong Kong

Zhen Fan YANG
MBBS, MS, PhD
Assistant Professor, Department of Surgery, The University of Hong Kong, Hong Kong

Boon Hun YONG
MBBS, FRCP (Edin), FANZCA, FHKCA, FHKCA (Intensive Care), FHKAM
Consultant Anesthetist, Team Head and Honorary Clinical Associate Professor, Liver Transplantation Anesthesia, Department of Anesthesiology, Queen Mary Hospital, The University of Hong Kong, Hong Kong

Karl YOUNG
MBBS, FKHCA (Intensive Care), FHKCA (Anesthesia), FJFICM
Consultant, Adult Intensive Care Unit, Queen Mary Hospital, Hong Kong

Kwok Yung YUEN
MBBS, FRCS (Glasg), FRCP (Lond, Edin & Ire), FRCPath, MD
Henry Fok Professor of Infectious Disease, Head and Chair of Microbiology, Department of Microbiology, Queen Mary Hospital, The University of Hong Kong, Hong Kong

Man Fung YUEN
MBBS, MD, PhD, FRCP (Lond), FRCP (Edin), FHKCP, FHKAM
Associate Professor, Division of Gastroenterology and Hepatology, Department of Medicine, Queen Mary Hospital, The University of Hong Kong, Hong Kong

Wai Key YUEN
MBBS, FRCS (Glasg), FRACS (Gen Surg), FACS, FHKAM (Surg)
Consultant and Honorary Associate Professor, Department of Surgery, Queen Mary Hospital, The University of Hong Kong, Hong Kong

Nomenclature

The nomenclature of liver anatomy follows that of C. Couinaud (Surgical Anatomy of the Liver Revisited, C. Couinaud, 1989, ISBN 2-903672-01-6) and the Japanese Society of Biliary Surgery (Nimura Y, Surgical anatomy of the biliary ducts. In: Rossi P, ed. Biliary Tract Radiology. Berlin, New York: Springer Verlag, 1997: 21-30).

Living Donor Liver Transplantation

Sheung Tat FAN, SBS
MBBS, MS, MD, PhD, DSc
FRCS (Glasgow), FRCS ad hominem (Edinburgh), FACS, FCSHK, FHKAM (Surg)
Doctor of Humane Letters (honoris causa)
Academician, Chinese Academy of Engineering (Medicine and Health)

Fan, Sheung Tat
Living donor liver transplantation / Sheung Tat FAN

ISBN 962-582-115-5

© 2007 Sheung Tat FAN

All rights reserved. No part of this publication may be reproduced, stored in a retrieval system, or transmitted in any form or by any means, electronic, mechanical, photocopying, recording, or otherwise, without prior permission in writing of the author.

Printed in China

Preface

Eleven years have lapsed since we performed the world's first successful adult-to-adult right liver living donor liver transplantation (LDLT). Over these years, many innovations and improvements have been made to render the operation design perfect and results comparable with, and even better than, that of deceased donor liver transplantation. By now, vast experiences have been accumulated in many leading liver transplant centers and most of the queries about the role and technical design of LDLT have been largely solved. It would be the most appropriate time to review and disseminate our experience and that of other researchers, hopefully, to benefit more patients in the future.

In this book, I present my views on the technical aspects of LDLT. My views may or may not be concordant with many researchers in the field. Nevertheless, they serve as a platform for further discussion and improvement in the results of LDLT.

Apart from the technical aspects, there are many issues of LDLT that are not yet covered fully in this book. However, I consider that technical success is of prime importance before any other issues could be discussed. Hopefully, in the future edition, issues other than the technical aspects will be elaborated in greater detail.

S.T. Fan, MS, MD, PhD, DSc
Sun C.Y. Chair Professor of Hepatobiliary Surgery
Chief of Liver Transplantation and Hepatobiliary Surgery
Department of Surgery
The University of Hong Kong
Queen Mary Hospital
Hong Kong

September 2007

1. History

The idea of using a living donor liver graft for orthotopic liver transplantation started in 1966[1] and 1969.[2] It had taken more than 20 years before the idea was materialized in clinical practice. The surge of living donor liver transplantation (LDLT) was a response to an increased demand for organs in the late 80's when liver transplantation was increasingly successful. The demand for liver grafts has been high, especially in countries without deceased organ donation.

On 8 December 1988, Raia et al[3] made their first attempt on a 4½-year-old girl with biliary atresia. The donor who donated the liver segments II and III survived, but the recipient succumbed on postoperative day 6 during hemodialysis. They made the second attempt on 21 July 1989. The recipient suffered from hepatic fibrosis and Caroli's disease. The donor recovered from the operation uneventfully, whereas the recipient had delayed graft function and remained jaundiced on postoperative day 24. The outcome of this recipient was not reported subsequently. In the same month, Strong et al[4] performed the first successful adult-to-child LDLT using the segment II and III graft. Both the donor and recipient were Japanese and they traveled to Brisbane for the possibility of deceased donor liver transplantation. In the same year, Singer et al[5] at the University of Chicago, USA conducted a research-ethics consultation for establishing the consensus and guideline for informed consent. Thereafter, Broelsch et al[6] refined the technique and rendered LDLT as a valuable salvage procedure for pediatric patients.

Adult-to-child LDLT was adopted rapidly in Asia where deceased liver donation was virtually absent. In Japan, Nagasue et al[7] performed the first of its kind in 1989. The recipient survived for 285 days before he succumbed to graft rejection and multi-organ failure. Subsequently, Ozawa et al[8] performed the first successful operation in Japan in June 1990. After experiencing four cases of hepatic artery thrombosis, they advocated a routine microvascular surgery technique for hepatic artery reconstruction, which revolutionized the practice of LDLT and rendered the results remarkable.[9] In Hong Kong, Yeung et al[10] performed the first of such operation in their region in 1993. In Korea, Lee et al[11] performed the first of such operation in 1994. In Taiwan, Chen et al[12] performed their first operation in 1994. In China, Dou et al[13] performed the first successful operation in 1997. By 2002, 509 adult-to-child LDLT had been performed in five major liver transplant centers in Asia with Kyoto University, Japan heading the largest experience.[14] In all of these operations, segment II and III grafts,



Figure 1.1. Left liver donation from a large body size donor (husband) to a small body size recipient (wife). They are the first adult left liver living donor liver transplantation donor and recipient in Hong Kong. The operation was performed on 12 July 1994. The couple are still alive and well.

sometimes extending to segment IV and left liver grafts, were used except in one operation. In that operation, Yamaoka et al[15] performed an unplanned adult-to-child LDLT using the right liver graft [without the middle hepatic vein (MHV)]. The donor operation was changed from left hepatectomy to right hepatectomy because of the finding of unfavorable anatomy of the left hepatic artery. In the subsequent years, LDLT was extended to infants using monosegment grafts[16] and to neonates using reduced monosegment grafts.[17]

The pediatric LDLT was rapidly adopted in Europe. The first case was performed by Broelsch et al in October 1991. Then Boillot et al from Lyon[18] and Otte et al from Belgium performed the second and third operations in July 1992 and July 1993, respectively.

Since there were many more adult than pediatric patients with terminal liver disease, LDLT was extended to adults soon after the initial success in pediatric patients. In 1991, Haberal et al[19] made the first attempt in adult recipients using the left liver grafts, but the result was unsatisfactory. In 1993, Makuuchi[20] and his team at Shinshu University, Japan performed the first successful adult-to-adult LDLT using the left liver graft. The recipient was a 53-year-old woman suffering from primary biliary cirrhosis and the donor was her son. The left liver graft (containing the MHV) was 45% of the ideal liver volume of the recipient. On 12 July 1994, we performed a similar operation between a married couple in Hong Kong.[21,22] The recipient suffered from fulminant hepatic failure during pregnancy. The husband weighing 82 kg was the donor to his wife, weighing 57 kg (Figure 1.1). The graft was 42% of the recipient's estimated standard liver volume (ESLV). In both cases, the operations were possible because the donors were heavier than the recipients.

However, despite the initial success using the left liver graft, the number of adult-to-adult LDLT had not increased, primarily because of the graft size limitation. In Asia, the majority of chronic hepatitis B patients are male. Their wives who are willing to donate are usually smaller in body size and could not be the donors.

To provide a larger graft for an adult recipient, we designed the right liver LDLT in Hong Kong in 1996.[23,24] The first operation was performed on 9 May 1996 and the patient suffered from fulminant Wilson disease. He weighed 90 kg, whereas the donor (his elder brother) weighed 74 kg. The right liver graft including the MHV weighed 910 gm and was about 39% of the patient's ESLV. Both donor



Figure 1.2. Right liver donation from a small body size donor to a large body size recipient. They are the No. 12 donor/recipient pair of the series of right liver living donor liver transplantation in Hong Kong. The operation was performed on 4 May 1998. They are still alive and well.



Figure 1.3. The first six right liver living donor liver transplantation recipients in the world. All of their right liver grafts contained the middle hepatic vein. All except one are currently alive and well.

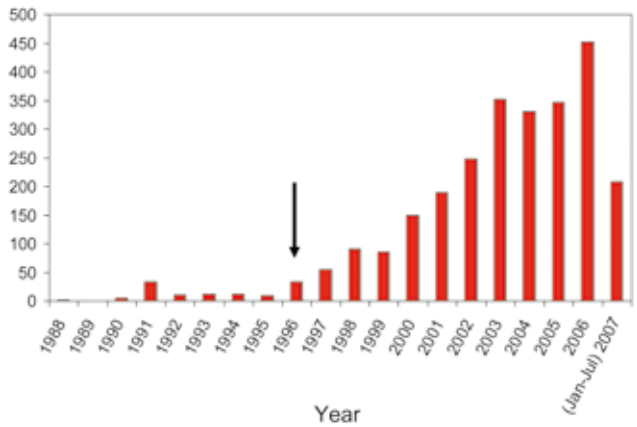

Figure 1.4. The graph shows the number of publications on living donor liver transplantation (LDLT) since 1988. Arrow indicates the year when the world's first adult-to-adult right liver LDLT was performed. Thereafter, the number of publications on LDLT has increased remarkably.

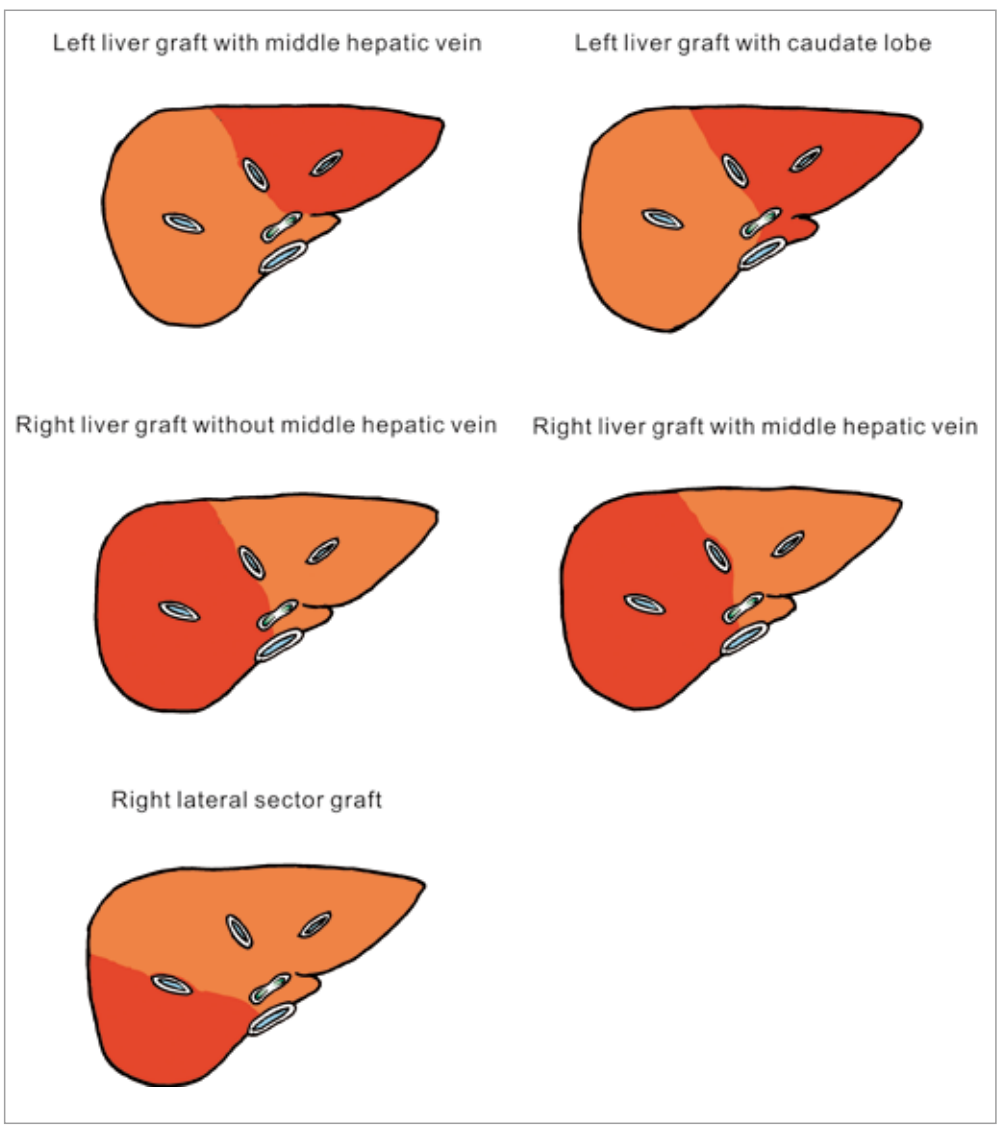

Figure 1.5. The available graft types for adult-to-adult living donor liver transplantation. The shaded area represents the graft portion of the liver.

and recipient had uneventful recovery and are currently alive and well. Including the MHV in the graft allows donation from a person of similar size as or even smaller than the recipient (Figures 1.2 and 1.3). Since then, the applicability of LDLT, especially for high urgency cases, has been much widened.[25-28] The right liver LDLT has been adopted by many other liver transplant centers. Research interest on LDLT has also been much enhanced (Figure 1.4). LDLT is now extended to Jehovah's Witness patients successfully.[29]

The first right liver LDLT in Europe was performed in Essen by Broelsch's team in 1998.[30] The first right liver LDLT in the USA was reported by Wachs et al[31] in 1998. Subsequently, Marcos et al[32] and others in the world employed the right liver graft as the predominant mode in LDLT in adults. However, in nearly all of these operations, the MHV was not included in the graft for fear of hepatic failure in the donor. The controversy of including the MHV in the right liver graft has continued up to now, but nowadays many centers have adopted a flexible approach and would include the MHV if the graft is relatively small, has a relatively small right hepatic vein, the anticipated congested volume of segment V/VIII is large, and the recipient has a poor premorbid condition or severe portal hypertension.[33-37]

Donor safety has been the major concern ever since the development of LDLT. To reduce the risk to the donor, use of the right lateral sector graft, the size of which is

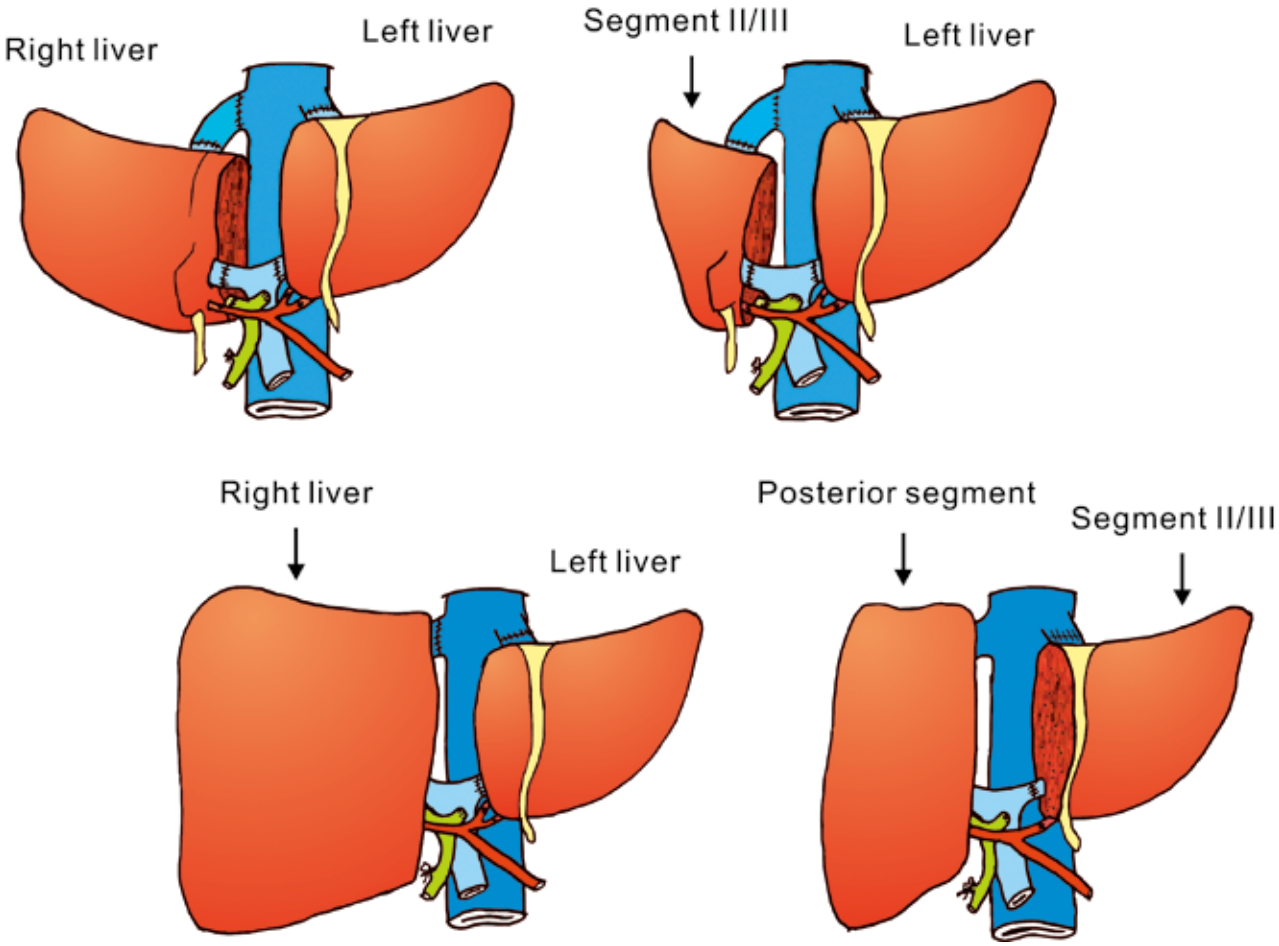

Figure 1.6. Types of dual-graft design advocated by S.G. Lee.[40]

intermediate between the right and left livers, was developed by Makuuchi's team.[38] The technical demand of this operation is high and could only be performed at a specialized center. Up till now, the right lateral sector graft has not been adopted as a common type of liver graft in LDLT (Figure 1.5).

In Korea, where fatty liver is common among the local population, Lee et al[39,40] designed the dual-graft operation mainly from the left liver to reduce the risk to the donors and to utilize suboptimal grafts with disproportionate volumes or excessive fatty change (Figure 1.6). The demand for resources and the technical complexity is much higher than that of the other graft types. This technique definitely expands the applicability of LDLT, but the risk to the donors is arguable.

In 2002, Cherqui et al[41] designed the technique of laparoscopic donor hepatectomy. The donation was initially confined to liver segments II and III, but was extended to the right liver by Koffron et al[42] and Kurosaki et al[43] in 2006. The major advantage of laparoscopic donor hepatectomy is reduced wound pain and shortened hospital stay, but donor safety and graft quality have not been ascertained. For donor safety and recipient benefit, donor selection in terms of hilar anatomy has to be more stringent in laparoscopic hepatectomy than open surgery.

The technique of LDLT has continued to evolve in recent years. Undoubtedly, LDLT saves lives. Some of the technical and ethical controversies identified in the early years have been resolved but not totally. Hopefully, with unbiased publication and open discussion of the results, consensus will be reached in the near future.

References

1. Dagradi A, Munari PF, Gamba A, Zannini M, Sussi PL, Serio G. Problems of surgical anatomy and surgical practice studied with a view to transplantation of sections of the liver in humans [in Italian]. Chir Ital 1966; 18: 639-659.

2. Smith B. Segmental liver transplantation from a living donor. J Pediatr Surg 1969; 4: 126-132.
3. Raia S, Nery JR, Mies S. Liver transplantation from live donors. Lancet 1989; 2: 497.
4. Strong RW, Lynch SV, Ong TH, Matsunami H, Koido Y, Balderson GA. Successful liver transplantation from a living donor to her son. N Engl J Med 1990; 322: 1505-1507.
5. Singer PA, Siegler M, Whitington PF, Lantos JD, Emond JC, Thistlethwaite JR, Broelsch CE. Ethics of liver transplantation with living donors. N Engl J Med 1989; 321: 620-622.
6. Broelsch CE, Whitington PF, Emond JC, Heffron TG, Thistlethwaite JR, Stevens L, Piper J, Whitington SH, Lichtor JL. Liver transplantation in children from living related donors. Surgical techniques and results. Ann Surg 1991; 214: 428-437.
7. Nagasue N, Kohno H, Matsuo S, Yamanoi A, Uchida M, Takemoto Y, Nakamura T. Segmental (partial) liver transplantation from a living donor. Transplant Proc 1992; 24: 1958-1959.
8. Ozawa K, Uemoto S, Tanaka K, Kumada K, Yamaoka Y, Kobayashi N, Inamoto T, Shimahara Y, Mori K, Honda K, Kamiyama Y, Kim HJ, Morimoto T, Tanaka A. An appraisal of pediatric liver transplantation from living relatives. Initial clinical experiences in 20 pediatric liver transplantations from living relatives as donors. Ann Surg 1992; 216: 547-553.
9. Mori K, Nagata I, Yamagata S, Sasaki H, Nishizawa F, Takada Y, Moriyasu F, Tanaka K, Yamaoka Y, Kumada K, et al. The introduction of microvascular surgery to hepatic artery reconstruction in living-donor liver transplantation – its surgical advantages compared with conventional procedures. Transplantation 1992; 54: 263-268.
10. Yeung CK, Ho JK, Lau WY, Liu K, Cho A, Buckley T, Aun C, Li AK. Institution of a pediatric liver transplantation program with living-related orthotopic liver transplantation: initial experience in Hong Kong. Transplant Proc 1994; 26: 2215-2217.
11. Lee SG, Lee YJ, Kwon TW, Kim KM, Choi KM, Park KM, Hong SJ, Kim IK, Kim SK, Min PC, Ko KS, Lee MG, Lee YM, Lee C. Liver transplantation from a living donor to his daughter. J Korean Transplant Soc 1995; 9: 187-192.
12. Chen CL, Concejero A, Wang CC, Wang SH, Lin CC, Liu YW, Yong CC, Yang CH, Lin TS, Chiang YC, Jawan B, Huang TL, Cheng YF, Eng HL. Living donor liver transplantation for biliary atresia: a single-center experience with first 100 cases. Am J Transplant 2006; 6: 2672-2679.
13. Dou KF, Guan WY, Li KZ, Tao KS, Zhu QS, Yue SQ, Zhao QC, Wang DS, Wang XH, An JZ. Surgical technique of recipient operation in living partial liver transplantation [in Chinese]. Zhonghua Qi Guan Yi Zhi Za Zhi 1998; 19: 69-70.
14. Lo CM. Complications and long-term outcome of living liver donors: a survey of 1,508 cases in five Asian centers. Transplantation 2003; 75(3 Suppl): S12-S15.
15. Yamaoka Y, Washida M, Honda K, Tanaka K, Mori K, Shimahara Y, Okamoto S, Ueda M, Hayashi M, Tanaka A, et al. Liver transplantation using a right lobe graft from a living related donor. Transplantation 1994; 57: 1127-1130.
16. Bonatti H, Muiesan P, Connelly S, Baker A, Mieli-Vergani G, Gibbs P, Heaton N, Rela M. Hepatic transplantation in children under 3 months of age: a single centre's experience. J Pediatr Surg 1997; 32: 486-488.
17. Ogawa K, Kasahara M, Sakamoto S, Ito T, Taira K, Oike F, Ueda M, Egawa H, Takada Y. Living donor liver transplantation with reduced monosegments for neonates and small infants. Transplantation 2007; 83: 1337-1340.
18. Boillot O, Dawahra M, Porcheron J, Houssin D, Boucaud C, Gille D, Kopp C, Bodnar D, Sann L, Paliard P, Stamm D, Lachaux A, Voiglio E, Cloix P, Mion F. Pediatric liver transplantation and related live donor. Technical and ethical considerations [in French]. Ann Chir 1993; 47: 577-585.
19. Haberal M, Buyukpamukcu N, Telatar H, Bilgin N, Arslan G, Simsek H, Ekici E, Karamehmetoglu M. Segmental living liver transplantation in children and adults. Transplant Proc 1992; 24: 2687-2689.
20. Ichida T, Matsunami H, Kawasaki S, Makuuchi M, Harada T, Itoh S, Asakura H. Living related-donor liver transplantation from adult to adult for primary biliary cirrhosis. Ann Intern Med 1995; 122: 275-276.
21. Lo CM, Gertsch P, Fan ST. Living unrelated liver transplantation between spouses for fulminant hepatic failure. Br J Surg 1995; 82: 1037.
22. Fan ST, Lo CM. Live donation for liver transplantation in Hong Kong – ethical issues. Asian J Surg 1994; 17: 331-333.
23. Lo CM, Fan ST, Liu CL, Lo RJW, Lau GKK, Wei W, Li HHC, Ng IOL, Wong J. Extending the limit on the size of adult recipient in living donor liver transplantation using extended right lobe graft. Transplantation 1997; 63: 1524-1528.
24. Fan ST, Lo CM, Liu CL. Transplantation of the right hepatic lobe. N Engl J Med 2002; 347: 615-618.
25. Lo CM, Fan ST, Liu CL, Wei WI, Chan JK, Lai CL, Lau GK, Wong J. Applicability of living donor liver transplantation to high-urgency patients. Transplantation 1999; 67: 73-77.
26. Liu CL, Fan ST, Lo CM, Yong BH, Fung AS, Wong J. Right-lobe live donor liver transplantation improves survival of patients with acute liver failure. Br J Surg 2002; 89: 317-322.
27. Liu CL, Fan ST, Lo CM, Wei WI, Yong BH, Lai CL, Wong J. Live-donor liver transplantation for acute-on-chronic hepatitis B liver failure. Transplantation 2003; 76: 1174-1179.
28. Liu CL, Lam B, Lo CM, Fan ST. Impact of right-lobe live donor liver transplantation on patients waiting for liver transplantation. Liver Transpl 2003; 9: 863-869.
29. Jabbour N, Gagandeep S, Mateo R, Sher L, Strum E, Donovan J, Kahn J, Peyre CG, Henderson R, Fong TL, Selby R, Genyk Y. Live donor liver transplantation without blood products: strategies developed for Jehovah's Witnesses offer broad application. Ann Surg 2004; 240: 350-357.
30. Testa G, Malago M, Valentin-Gamazo C, Lindell G, Broelsch CE. Biliary anastomosis in living related liver transplantation using the right liver lobe: techniques and complications. Liver Transpl 2000; 6: 710-714.
31. Wachs ME, Bak TE, Karrer FM, Everson GT, Shrestha R, Trouillot TE, Mandell MS, Steinberg TG, Kam I. Adult living donor liver transplantation using a right hepatic lobe. Transplantation 1998; 66: 1313-1316.
32. Marcos A, Ham JM, Fisher RA, Olzinski AT, Posner MP. Single-center analysis of the first 40 adult-to-adult living donor liver transplants using the right lobe. Liver Transpl 2000; 6: 296-301.
33. Kasahara M, Takada Y, Fujimoto Y, Ogura Y, Ogawa K, Uryuhara K, Yonekawa Y, Ueda M, Egawa H, Tanaka K. Impact of right lobe with middle hepatic vein graft in living-donor liver transplantation. Am J Transplant 2005; 5: 1339-1346.
34. Kokudo N, Sugawara Y, Imamura H, Sano K, Makuuchi M. Tailoring the type of donor hepatectomy for adult living donor liver transplantation. Am J Transplant 2005; 5: 1694-1703.
35. Hwang S, Lee SG, Lee YJ, Sung KB, Park KM, Kim KH, Ahn CS, Moon DB, Hwang GS, Kim KM, Ha TY, Kim DS, Jung JP, Song GW. Lessons learned from 1,000 living donor liver transplantations in a single center: how to make living donations safe. Liver Transpl 2006; 12: 920-927.
36. de Villa VH, Chen CL, Chen YS, Wang CC, Lin CC, Cheng YF, Huang TL, Jawan B, Eng HL. Right lobe living donor liver transplantation – addressing the middle hepatic vein controversy. Ann Surg 2003; 238: 275-282.
37. Asakuma M, Fujimoto Y, Bourquain H, Uryuhara K, Hayashi M, Tanigawa N, Peitgen HO, Tanaka K. Graft selection algorithm based on congestion volume for adult living donor liver transplantation. Am J Transplant 2007; 7: 1788-1796.
38. Sugawara Y, Makuuchi M, Takayama T, Mizuta K, Kawarasaki H, Imamura H, Hashizume K. Liver transplantation using a right lateral sector graft from a living donor to her granddaughter.

Hepatogastroenterology 2001; 48: 261-263.
39. Lee SG, Hwang S, Park KM, Kim KH, Ahn CS, Lee YJ, Cheon JY, Joo SH, Moon DB, Joo CW, Min PC, Koh KS, Han SH, Choi KT, Hwang KS. Seventeen adult-to-adult living donor liver transplantations using dual grafts. Transplant Proc 2001; 33: 3461-3463.
40. Lee SG, Park KM, Hwang S, Lee YJ, Kim KH, Ahn CS, Choi DL, Joo SH, Jeon JY, Chu CW, Moon DB, Min PC, Koh KS, Han SH, Park SH, Choi GT, Hwang KS, Lee EJ, Chung YH, Lee YS, Lee HJ, Kim MH, Lee SK, Suh DJ, Kim JJ, Sung KB. Adult-to-adult living donor liver transplantation at the Asan Medical Center, Korea. Asian J Surg 2002; 25: 277-284.
41. Cherqui D, Soubrane O, Husson E, Barshasz E, Vignaux O, Ghimouz M, Branchereau S, Chardot C, Gauthier F, Fagniez PL, Houssin D. Laparoscopic living donor hepatectomy for liver transplantation in children. Lancet 2002; 359: 392-396.
42. Koffron AJ, Kung R, Baker T, Fryer J, Clark L, Abecassis M. Laparoscopic-assisted right lobe donor hepatectomy. Am J Transplant 2006; 6: 2522-2525.
43. Kurosaki I, Yamamoto S, Kitami C, Yokoyama N, Nakatsuka H, Kobayashi T, Watanabe T, Oya H, Sato Y, Hatakeyama K. Video-assisted living donor hemihepatectomy through a 12-cm incision for adult-to-adult liver transplantation. Surgery 2006; 139: 695-703.

2. Donor evaluation

Introduction

Never in the history of liver surgery is a person operated for a disease that he/she does not have. Unlike living kidney donation operation, living liver donation surgery is much more risky and complicated. To protect the altruistic donor and to avoid unnecessary morbidity and mortality, vigilant evaluation based on an established protocol is mandatory.

By definition, a living donor is a completely healthy person physically, psychologically and mentally.[1] Although many patients with underlying medical diseases have undergone major hepatectomy successfully, the same acceptance threshold could not be applied to a healthy person donating a part of the liver to another person. Even though major hepatectomy could be performed with zero per cent hospital mortality,[2-4] concomitant morbid illness accounts for the majority of potentially fatal complications.[5] Since the donor must recover from the donor operation speedily and uneventfully, any error in the preoperative evaluation is not acceptable. The workup of the potential donor is no less a serious procedure than the donor operation itself. Therefore, there should not be any compromise in the evaluation process and acceptance of a donor. Any volunteer with concomitant medical illness should not be allowed to donate.

Steps in donor evaluation

The donors have to go through the evaluation step by step to avoid unnecessary trauma and complications (Table 2.1). In general, elderly donors are not accepted. Some centers accept donors up to the age of 65.[6] In Hong Kong, the upper age limit is arbitrarily set at 55. Since the incidence of hidden medical diseases increases with age (particularly in those who are over-weight), acceptance of donors beyond the upper age limit must be exercised with caution.[7] The lower donor age limit depends on the local legal requirement, ranging from 16–20.[8] In Hong Kong, friends or distant relatives of the recipients are accepted, but prior approval of the Human Organ Transplant Board must be obtained. In Korea, liver donor paired exchange programs, as in kidney transplantation, have started.

Donor evaluation starts only when a person explicitly expresses his decision to donate and is already informed fully about the nature of the operation, risk and benefit involved. The salient information about the operation is given during an interview and via an information pamphlet (an example is seen in Appendix I). This includes the side and portion of the liver to be donated and the need for cholecystectomy. The information should also include an estimated recipient hospital mortality rate of 5% and a 5-year overall survival rate of 75%–80%. The estimated donor mortality of 0.5%–1% and a complication rate of 15%–20% should be explained. The cumulative experience of living donor liver transplantation (LDLT) of the center and globally should be available in the pamphlet. The rationale of carrying out LDLT should be explained. For example, in Hong Kong, due to the scarcity of deceased organs, a 50% mortality of potential recipients on the waiting list[9] and a 90% mortality rate for those who require organ support are expected.[10] The waiting list mortality rates vary from region to region depending on the availability of deceased organs. The lack of deceased organs should be stated, but it should not be viewed as coercion to the family.

The main purpose of donor evaluation is to determine whether the volunteer is suitable for donation. Thus, there are three important aspects of evaluation: detection of medical or transmissible disease, which, whether obvious or hidden, may increase the risk of both the donor and recipient, assessment of the psychological status including motivation of donation, and study of the suitability of the intended liver graft in terms of anatomy, volume and function. In some centers, an independent assessor or donor advocate and a social worker are also involved. The former supports and helps the donor and the family in their decision making. The latter

Table 2.1. Steps in donor evaluation.

Step 1
Medical history:
Diabetes mellitus, hypertension, ischemic heart disease, malignancy, peptic ulcer, asthma, and mental illness.
Drug, alcohol, smoking, and allergy history.
Contraceptive practice for women of reproductive age (pregnancy test if sexually active).
Physical examination:
Body weight, body height, blood pressure, heart, lung, and abdominal examination. Urinalysis.
Hematology:
Blood type and screen.
Complete blood picture, international normalized ratio, activated partial thromboplastin time.
Biochemistry:
Liver and renal biochemistry, amylase, testing of glucose and lipid profiles.
Serology:
HBsAg, HBsAb, HBcAb, antiHCV, HIV I/II, cytomegalovirus, varicella zoster virus.
Step 2a
Clinical psychological assessment.
Step 2b
Chest radiograph, electrocardiogram.
Computed tomography of liver under sodium bicarbonate cover.
Volumetric analysis (right, left & caudate lobe; for pediatric recipients, segments II and III).
Maximum intensity projections of hepatic veins and portal veins.
Three-dimensional reconstruction of hepatic artery.
Step 3
Liver biopsy.
Visceral angiogram if computed tomography angiographic features are not informative.
Step 4
Informed consent of LDLT from donor and recipient.
Consent from a relative of the potential donor.
Human leukocyte antigen typing.
Cross match.

HBsAg, hepatitis B surface antigen; HBsAb, hepatitis B surface antibody; HBcAb, hepatitis B core antibody; antiHCV, hepatitis C antibody; HIV, human immunodeficiency virus; LDLT, living donor liver transplantation.

assesses the donor's social support, financial status, health insurance and relationship to the recipient.[11] Arrangements for the potential donors to meet past donors are also advocated in some centers.[12]

The potential donor will have a close liaison with the transplant coordinator throughout the evaluation process. Results of investigation are only disclosed to the potential donor directly by the transplant coordinator. Freedom of withdrawal must be allowed at any stage of the donor workup. A technical reason can be provided by the medical staff on behalf of the potential donor if he/she chooses to withdraw. A medical reason is less desirable as it may stigmatize the donor and jeopardize his/her insurance coverage in the future, especially when such medical reason is recorded.[13]

Step 1

A detailed medical history is taken. History of malignancy, diabetes mellitus, hypertension, ischemic heart disease, kidney disease, asthma, and psychological or psychiatric disorders preclude donation. Allergy, drug and alcohol history are noted. Smokers may stand a higher chance of pulmonary infection after hepatectomy. Heavy smokers who are productive of sputum should not be accepted for donation. Women of reproductive age and who are sexually active must undergo a pregnancy test. The use of oral contraceptive pills indicates perioperative deep vein thrombosis prophylaxis by subcutaneous heparin in addition to physical means. Persons with peptic ulcer may need upper endoscopy to exclude active ulcer pathology before deciding for further evaluation. Potential donors with ongoing infection are definitely not suitable for donation.[14,15] Persons with history of hepatitis must have serological tests before further evaluation. Those with past tuberculosis may be acceptable provided that the infection has been adequately treated and is dated back many years ago, but the risk of transmitting

an occult infection to the recipient is real.[16] More importantly, the donor may have reactivation of tuberculosis after the hepatectomy and possibly liver failure as the anti-tuberculosis drugs are potentially toxic to the small liver remnant. Though the possibility of such occurrence is low or remote, the donor must be informed of such possibility.

Physical examination includes the usual parameters. Body weight and height are measured for calculating the body mass index (BMI). It is generally agreed that obese patients (BMI > 30) have a higher risk of operative complications.[17-19] If an alternative donor is available, one should avoid operating on obese donors. If an obese donor is the only person available, he/she must be free of medical disease, free from sleep apnea, and has normal liver biochemistry and minimum degree of fatty liver. He/she must be warned of a higher wound infection rate and sometimes the wound infection could be serious, e.g. in the form of necrotizing fasciitis.[11]

It is worth noting that Asians may have a higher percentage of body fat per gram body weight and cardiovascular risk factors at lower BMI levels than Westerners.[20] A lower index of BMI is employed to define overweight (BMI > 23) and obesity (BMI > 27.5).[21] Based on our data, those with BMI > 27.5 had significantly higher complication rates (31%, including deep vein thrombosis in one donor) than those with BMI < 27.5 (13.6%). There is no difference in the morbidity rate between the donors with BMI < 23 and those with BMI > 23. Therefore, overweight donors (with BMI 23.1–27.5) are acceptable, but it is preferred that they lose weight before the operation, if the recipient operation could be deferred.

Urinary tests for protein and sugar should not be omitted. Blood tests should include the blood type, hemoglobin level, white blood cell count, platelet count, international normalized ratio, renal and liver biochemistry, fasting blood sugar and lipid profile, and serological tests for hepatitis virus, human immunodeficiency virus, and cytomegalovirus.

Not infrequently, the potential female donors have hemoglobin levels lower than the normal range. Menstrual disorder may account for the anemia, but detailed history including bowel habit changes, per rectal bleeding, and investigations, including upper endoscopy or virtual colonoscopy, may be needed to exclude occult source of bleeding. Unless the situation is urgent, correction of anemia is mandatory before consideration of donor operation.

Hepatitis B surface antigen positivity and hepatitis C antibody positivity preclude donation. Persons with hepatitis B core antibody (HBcAb) in the serum are acceptable for donation, but the potential donors need testing for HBV DNA and the recipients may require lifelong cover by lamivudine.[22] However, there are suggestions that recipients with hepatitis B surface antibody positivity[23] and donors with HBV DNA negativity[24] may have anti-viral prophylaxis terminated after the transplant. There are also suggestions that short-term lamivudine treatment is sufficient for patients who have developed de-novo hepatitis B infection after receiving HBcAb-positive liver grafts.[25] Despite the optimistic views, we maintain that long-term lamivudine coverage is needed because living donor liver grafts are too precious to lose. In general, the HBcAb status does not adversely affect the postoperative recovery of the donors, but HBcAb-positive donors may have delayed normalization of serum bilirubin levels compared with HBcAb-negative donors. In our experience, three HBcAb-positive donors had cholestasis (serum bilirubin > 100 μmol/L on postoperative day 7) and they all had mild fatty liver and were older than 45 years. Therefore, for HBcAb-positive donors > 45 years old, a large liver remnant is preferred.

Persons with hyperlipidemia or hypercholesterolemia have a higher risk of premature atherosclerotic cardiovascular disease. It is arguable whether they should be subject to major hepatectomy even if screening for cardiovascular disorder is negative. It is not known how many asymptomatic hyperlipidemic donors have undergone donor hepatectomy uneventfully, but at least three donors who died after liver donor operation had hyperlipidemia or lipid disorder.[26-28] It is therefore safer to avoid donors with hyperlipidemia.

Extensive blood tests are considered necessary by some centers[8] for occasional cases of hidden chronic liver disease,[29] malignancy, congenital abnormalities of coagulation,[30] or lipid disorder[31] (Table 2.2). Whether such extensive tests are cost-effective is not known. Completing all these tests may defer the operation and is undesirable for needy recipients. Probably the indications for such tests

depend on the local prevalence of a certain condition or within the family.

Step 2a

While the initial screening for the genuineness of a potential donor is done by the surgeon or physician at the time of interview, a more comprehensive and a third party psychological assessment is performed by a dedicated clinical psychologist. In our center, we have the privilege of full support of clinical psychologists who are always available for emergency cases.

The clinical psychology evaluation is mandatory to ensure that the voluntarism is genuine and to fulfill the local legal requirement. A potential donor showing signs of ambivalence should not be allowed to undergo the donor operation.[32] Similarly, persons with history of anxiety, depression, and drug abuse should be viewed with caution. The clinical psychologist will interview the donor and recipient independently and collect the following information:

1. Clinical observation of the potential donor.
2. Relevant background.
3. Events leading to the proposed organ transplant.
4. The psychological condition of the intended donor.
5. The intended donor's reason for his/her decision to donate the organ.
6. The relationship and/or emotional ties between the intended donor and intended recipient.

Based on the information, the clinical psychologist makes an independent recommendation as to whether the donor is suitable for undergoing donation. To comply with the regulations set by the Human Organ Transplant Board of the Hong Kong Special Administrative Region Government, the clinical psychologist has to verify in his/her assessment and indicate in his/her report that:

1. The intended donor's decision to donate the organ is made voluntarily and there is no monetary or other gain from the donation.
2. The intended donor is psychologically prepared for both the removal and transplant operations.
3. The intended donor has adequate ability to understand what is involved in donating the organ.
4. There are no specific difficulties in communicating with the intended donor.
5. The intended donor has understood that he/she has given his/her consent to removal of the organ without coercion or offer of inducement.
6. The intended donor understood his/her entitlement to withdraw consent at any time.
7. The intended donor has received the relevant information pamphlet about organ donation and transplantation.
8. The doctor-in-charge of the intended donor has explained to him/her the nature of the procedures.
9. The doctor-in-charge of the intended donor has explained to him/her the implications of the procedures.
10. The doctor-in-charge of the intended donor has

Table 2.2. List of laboratory tests for exclusion of latent chronic liver disease, malignancy, coagulation disorder and lipid disorder.

Chronic liver disease
Serum transferrin saturation
Ferritin
Ceruloplasmin
Alpha1-antitrypsin
Antinuclear antibody
Smooth muscle antibody
Antimitochondrial antibody
Indocyanine green clearance test
Coagulation disorder
Antithrombin III
Protein C, protein S
Antiphospholipid antibodies
Factor V Leiden
Factor II gene mutation
Von Willebrand factor activity
Activated protein C resistance
Lipid disorder
Triglycerides
Cholesterol, total
Cholesterol, high density lipoprotein
Cholesterol, low density lipoprotein
Cholesterol, non-high density lipoprotein
Apolipoprotein A1
Apolipoprotein B
Hormonal disorder
T3, T4, TSH
Malignancy
Carcino embryonic antigen
Alpha-fetoprotein
CA 19-9

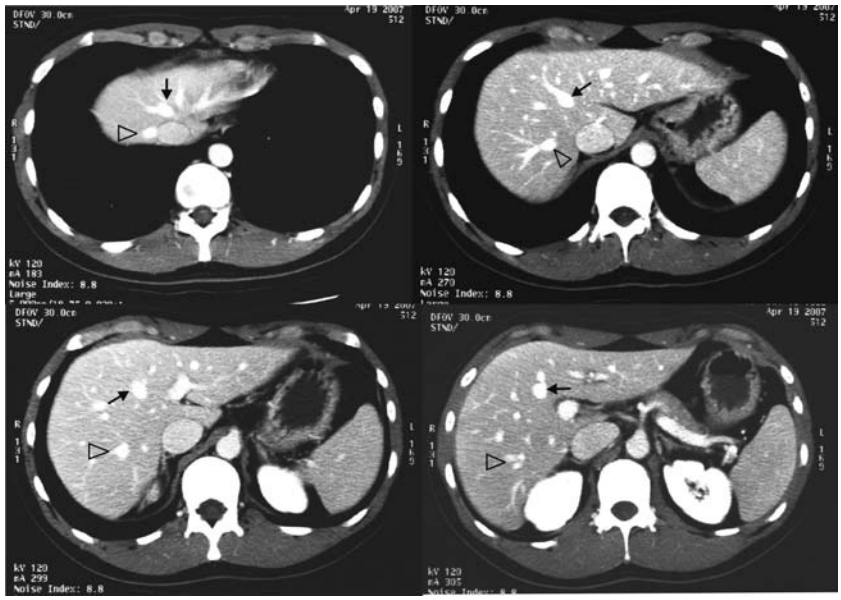

Figure 2.2. Computed tomography scan shows that the middle hepatic vein (arrow) is larger than the right hepatic vein (▷). A dominant middle hepatic vein may preclude the donor if the middle hepatic vein is not planned to be included in the graft. Routine inclusion will expand the applicability of adult-to-adult living donor liver transplantation.

explained to him/her the possible postoperative complications of the removal surgery.

11. The doctor-in-charge of the intended donor has explained to him/her the possible long-term effects of the removal surgery.
12. The doctor-in-charge of the intended donor has explained to him/her the mortality rate of the removal surgery for the donor would be 0.5%–1%.
13. The doctor-in-charge of the intended donor has explained to him/her the mortality rate of the transplant surgery for the recipient would be 5%–10%.

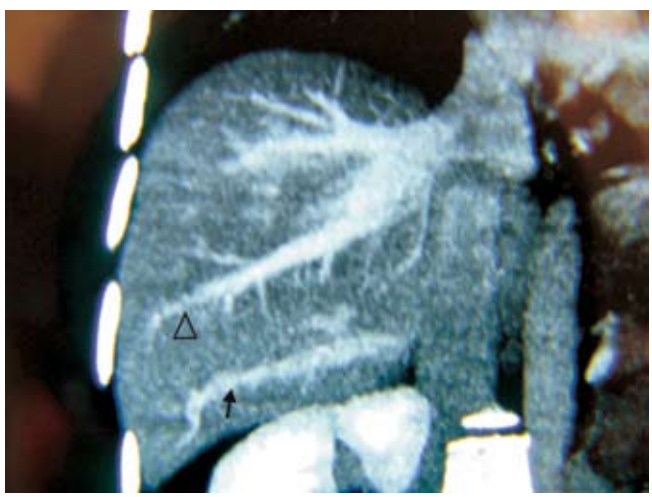

Figure 2.1. Computed tomography scan shows a large inferior right hepatic vein draining segment VI (arrow) and middle right hepatic vein draining segment VII (△).

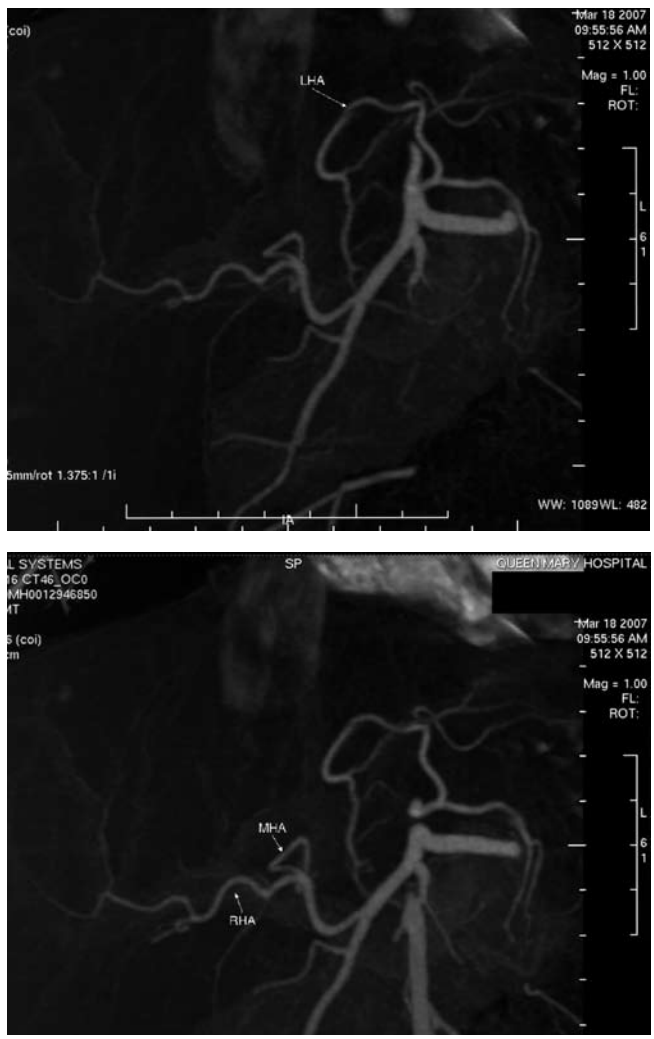

Figure 2.3A,B. Computed tomography scan reconstruction of hepatic arteries. The left hepatic artery (LHA) arises from the left gastric artery. This pattern is favorable for segment II/III liver donation **(A)**; The right hepatic artery (RHA) arises from the common hepatic artery and the celiac axis. The middle hepatic artery (MHA) arises from the proper hepatic artery. The length of the RHA is sufficient for a right liver graft **(B)**.

Step 2b

Chest radiograph and electrocardiogram are included in this stage of evaluation. If normal, the potential donor will undergo computed tomography (CT) under hydration and sodium bicarbonate cover.[33]

The anatomy of the hepatic vein is studied on the axial cuts in the venous phase and maximum intensity projection. Presence of the inferior (draining segment VI)[34] or middle right hepatic vein (draining segment VII) is noted (Figure 2.1). For left or right liver graft operation, the middle hepatic vein (MHV) is studied thoroughly with regard to the course and the hepatic veins draining into it. To increase the safety margin, the segment IVb hepatic vein should be preserved with the liver remnant for right liver donation that includes the MHV. The site of segment IVb hepatic vein joining the MHV should be studied carefully.[35] For centers with a selective policy of including the MHV in the right liver graft, the size of the MHV may be a determining factor of whether it will be included in the right liver graft or not (Figure 2.2). A dominant MHV may exclude the candidacy of the right liver donor in some centers, but by including the MHV routinely, the number of potential donors thereby increases.

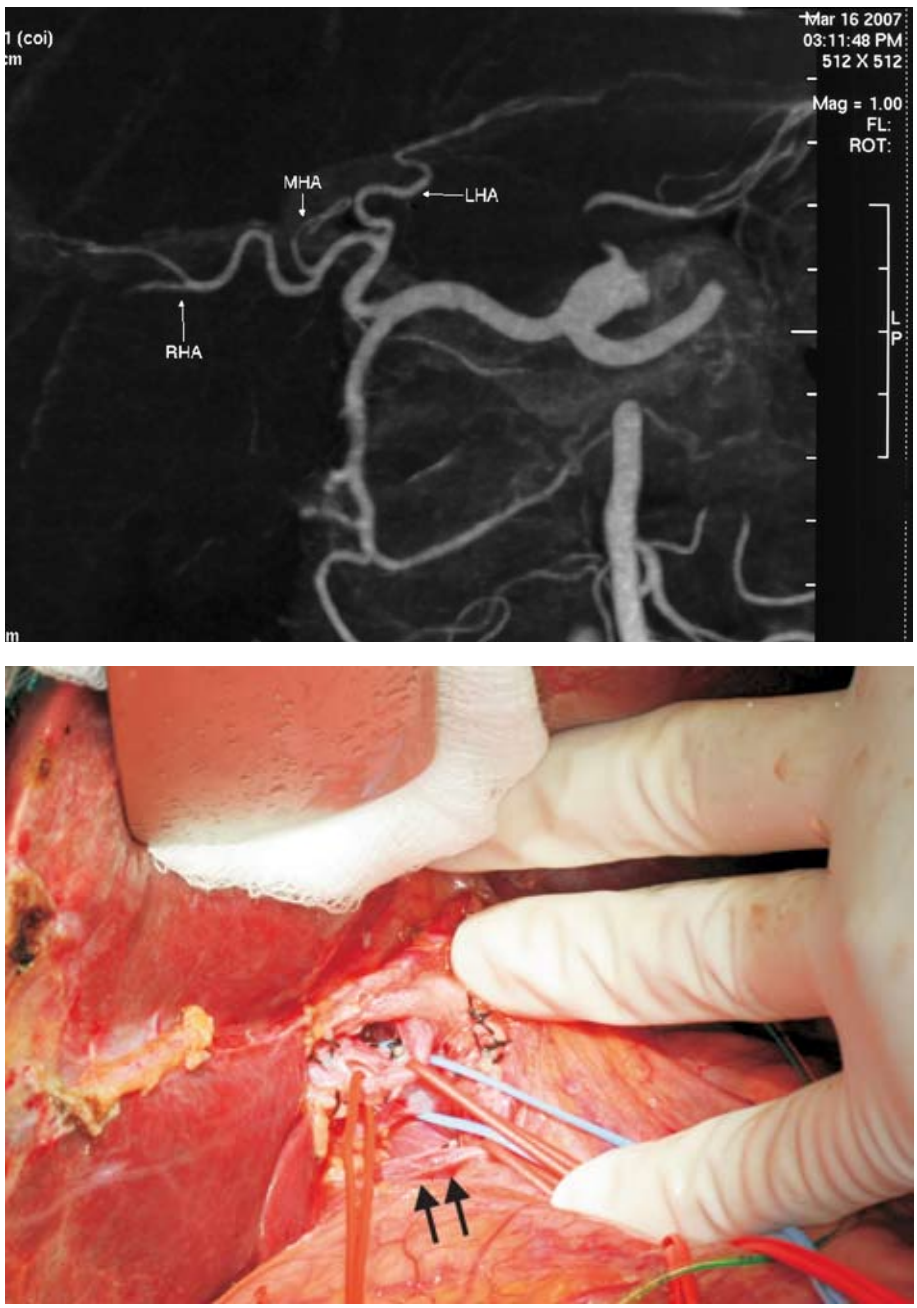

Figure 2.4A,B. Computed tomography (CT) scan shows a display of the hepatic artery anatomy. The middle hepatic artery (MHA), right hepatic artery (RHA), and left hepatic artery (LHA) are clearly shown. However, in this CT scan, an additional RHA was missed **(A)**; Photo showing an additional right hepatic artery (arrows), which was missed by CT scan **(B)**.

By three-dimensional reconstruction, the course of the right hepatic artery (RHA) and left hepatic artery (LHA) is outlined (Figures 2.3–2.5). An RHA from the superior mesenteric artery or a LHA arising from the left gastric artery is favorable for donor operation (Figure 2.3). The origin of the segment IV hepatic artery is noted (Figure 2.4). It must be protected during the operation to prevent infarction of segment IV in a right liver donor. However, on some occasions, the segment IV hepatic artery communicates with the segment II/III hepatic artery. It is demonstrated by intraoperative Doppler study when flow signal is seen within the intrahepatic segment IV hepatic artery after the extrahepatic portion is temporarily occluded. In this situation, the

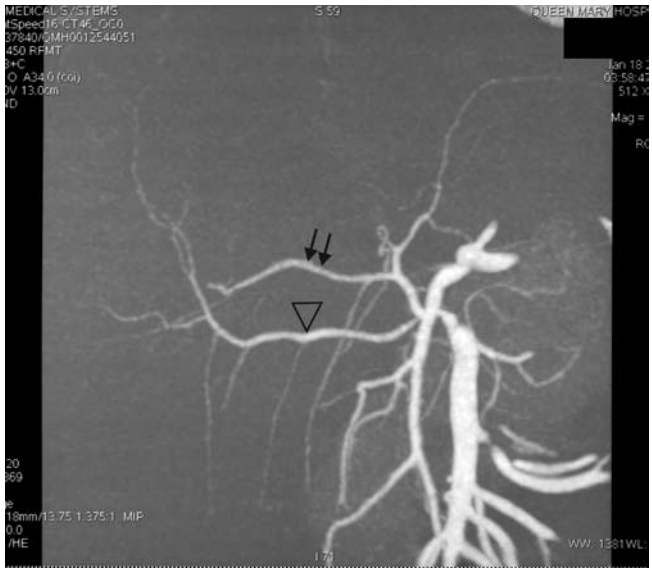

Figure 2.5. In this donor, the right anterior hepatic artery (arrows) was derived from the proper hepatic artery at the umbilical fissure. This artery was found to be running across the hilar plate and was isolated at the time of right hepatic duct division. The right posterior hepatic artery (▽) was derived from the superior mesenteric artery. On computed tomography scan, these two arteries appeared independent, but at laparotomy, good backflow was observed on dividing the right anterior hepatic artery. Communication between the two right hepatic arteries was also shown on Doppler ultrasonography. In the recipient, only the right posterior hepatic artery was used for reconstruction.

segment IV hepatic artery could be sacrificed for a right liver graft if it originates at a position near to the right liver hilum. There may be two RHA (Figure 2.5). Similar to the LHA, communication between the two branches of the RHA may exist, rendering anastomosis of either one sufficient and it is not contraindicated for donation. However, more than two hepatic arteries impose technical difficulty (the artery is smaller) and uncertainty about the intrahepatic communication. In this situation, the other graft side or another donor has to be considered.

The portal vein anatomy could also be ascertained on CT scan. The length of the right or left portal vein (LPV) could be measured. A common anomaly is trifurcation of the portal vein, but it is not a contraindication to donation[36] (Figures 2.6 and 2.7). Sometimes, the segment V/VIII portal vein arises from the LPV. This vein is usually extrahepatic and would be identified readily during hilar dissection. A rare but dangerous anomaly is the situation when the segment V/VIII portal vein arises from the LPV within the umbilical fissure. This vein would be intrahepatic and encountered during liver transection (Figures 2.8 and 2.9). Early identification by careful study of the CT scan will prevent damage or occlusion during liver transection. Absent right portal vein has been described by Couinaud,[37] but not yet encountered in our practice (Figure 2.8). Such anomaly precludes donation.

CT volumetry[38] is also performed. It is generally believed that a remnant liver volume of 30%–35% of the total liver volume is safe for donor operation and a graft that provides 40% of the estimated standard liver volume (ESLV)[39] or 0.8% of the body weight of the recipient[40] is necessary for recipient survival. Such numbers were suggested by the earlier researchers without much data support,[41] but they appear to stand the test of time.[8,42,43]

Estimation of graft weight or volume in terms of the estimated standard liver weight (ESLW) or

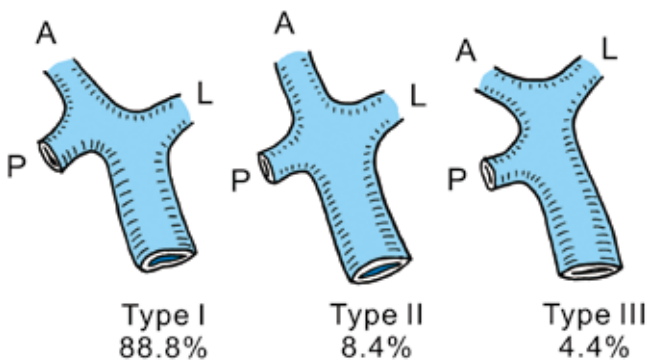

Figure 2.6. Three common types of portal vein pattern at the liver hilum.[37] A, anterior; P, posterior; L, left.

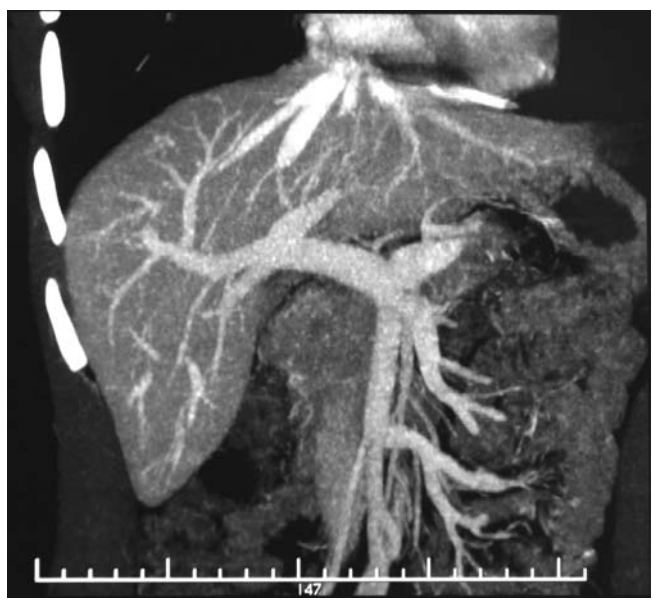

Figure 2.7. Computed tomography scan shows trifurcation of the portal vein. This is not a contraindication to donor operation. The right anterior and posterior portal veins may have to be incorporated into a single orifice by venoplasty.

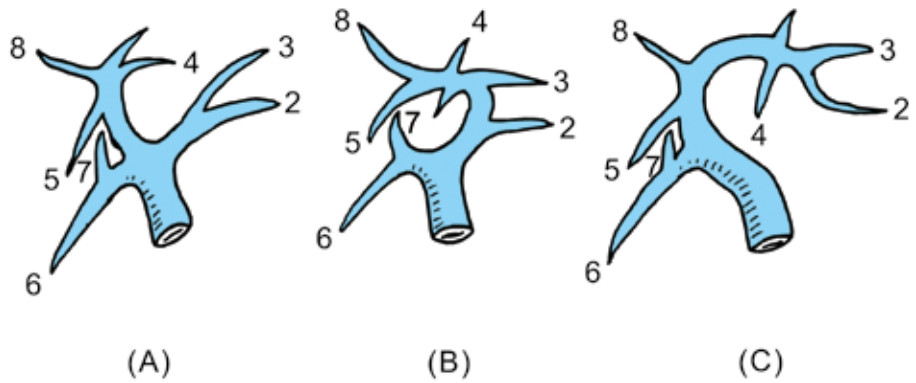

Figure 2.8. Rare anatomical anomaly that may preclude safe donation.[37] Type (B) is still feasible for right liver donation, but it must be recognized preoperatively to avoid ligation or injury during liver transection. Types (A) and (C) are contraindicated for right liver living donor liver transplantation. The numerical numbers refer to the liver segments.

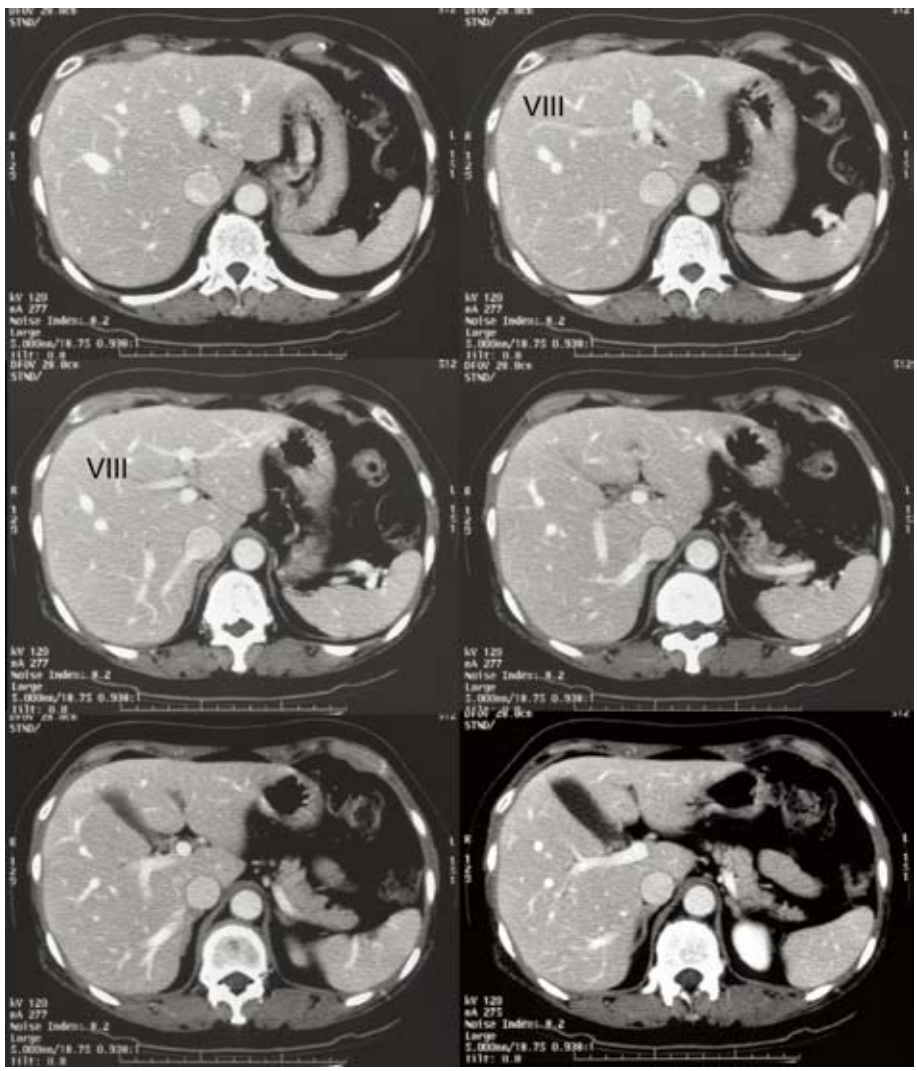

Figure 2.9. A large branch of portal vein comes from the left portal vein at the umbilical fissure. This is the segment VIII portal vein. This donor had a successful operation. The segment VIII portal vein was joined to the right posterior portal vein at the back table into a single orifice.

ESLV is necessary to avoid serious graft size mismatch and small-for-size syndrome. The accuracy, however, depends much on how the formula of ESLW or ESLV is derived. Previous studies based on post-mortem liver specimen provided weight (gm) as an end-product,[44] whereas studies that utilized imaging of liver provided volume (mL) as an end-product.[45] It has been assumed that weight and volume of the liver are equivalent, but in our study based on CT volumetry and graft weight measured at back table, a conversion factor of 1.19 mL/g is needed.[46] Moreover, formulae derived from different races may not be applicable to each other.[47,48] The liver size is also affected by the age and sex of the population[49,50] with older females having smaller liver size. The scientific value of some of the formulae is doubtful because they are based on the study of DuBois and DuBois[51] in 1916, which included nine subjects spanning a wide age range. It would be logical to deduce from the above consideration that a formula should be established for each race or local population based on the latest local data. Errors using the ESLW could be reduced by using the patient's own body weight as the denominator. However, if the patient has massive ascites or fluid retention, the demand for the size of the liver graft would be over-estimated. Finally, there is a possibility that CT volumetry may over- or underestimate the graft size, depending on how the line between the right and left livers is drawn. On this issue, the surgeon himself must ascertain that the line is correctly drawn by following the course of the MHV from the inferior vena cava to

the gallbladder fossa.

For right liver graft including the MHV, sacrifice of the MHV means congestion of the segment IV and results in less functional volume of the liver remnant. In our experience, a remnant of 30% of the total liver volume (without the MHV) in a donor is safe, especially when the segment IVb hepatic vein is retained in the remnant. To increase the safety margin, the volume of the congested segment IV could be estimated by three-dimensional reconstruction of CT scan using the MeVis software (MeVis Technology, Bremen, Germany). In some centers, if the congestion-free remnant volume is more than 30%–35% of the total liver volume, liver donation is considered safe and permissible.[8]

Hepatic angiography is no longer performed nowadays. It carries the risk of contrast-induced nephropathy and intimal injury of the hepatic artery. The potential morbidity outweighs the benefit of providing a clear "road-map" of the hepatic artery. CT three-dimensional reconstruction of the hepatic artery provides a clear delineation and makes hepatic angiography obsolete for donor evaluation. Even if the CT is not totally correct (Figure 2.4), careful hilar dissection will identify abnormal hepatic artery anatomy.

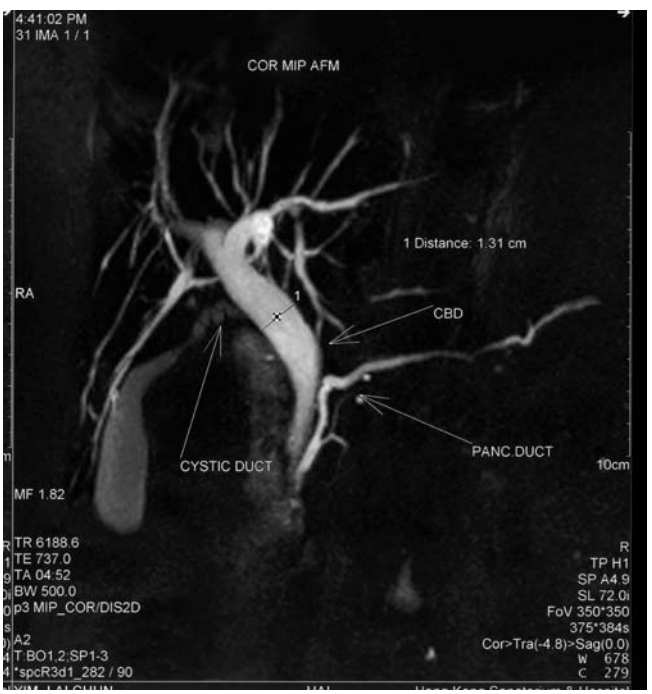

Figure 2.10. A high-quality magnetic resonance cholangiopancreatography shows a segmental biliary anatomy clearly. The prerequisite is a fairly large-size biliary tract, which is not frequently present in a normal person.

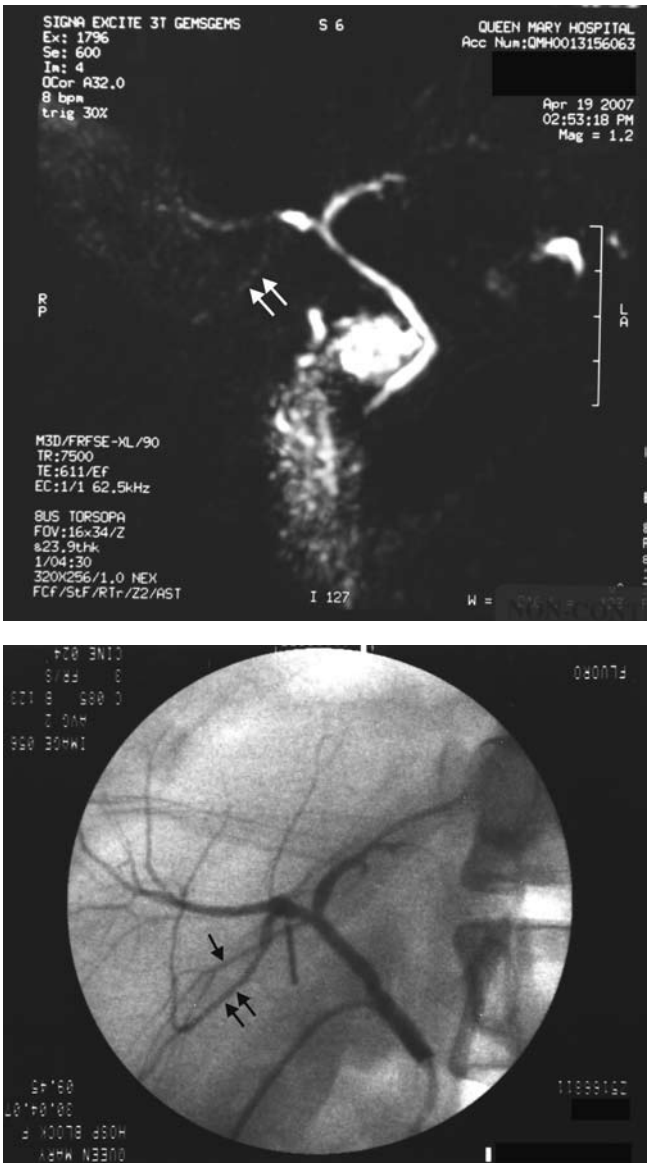

A

B

Figure 2.11A,B. Magnetic resonance cholangiopancreatography (MRCP) of a donor shows two right hepatic duct branches close to the confluence. The vaguely identified duct (arrows) was probably a right posterior duct. A single right hepatic duct was thought to be present **(A)**; Operative cholangiogram of the same donor shows that the duct shown by the MRCP was actually a segment VI/VII hepatic duct (double arrows), but the segment V duct (single arrow) was missed by MRCP. Thus, the graft contained two hepatic duct orifices instead of one as delineated by MRCP **(B)**.

Magnetic resonance imaging (MRI) is the alternative to CT scan.[52] It is more advantageous in that the incidence of anaphylaxis and nephrotoxicity is lower than CT scan. It provides all the functions of CT scan. In addition, magnetic resonance cholangiopancreatography (MRCP) can be done in the same setting.[53] If a good quality MRI facility is available, it is preferred to CT scan (Figures 2.10 and 2.11).

Since biliary tract anomaly may preclude a donor from operation, preoperative imaging of the biliary tract by endoscopic retrograde cholangiopancreatography (ERCP) has been suggested.[54] The risk of ERCP complications is probably too high for a normal person. Instead, CT cholangiography and MRCP have been used. However, both types of methods are not sufficiently accurate in defining the second or third order branch of the common hepatic duct in every case. A very high quality CT cholangiogram could be obtained by the MeVis software (MeVis Technology, Bremen, Germany) after intravenous injection of Bilioscopin, but occasional case of allergic reaction to the intravenous contrast is observed.[55] Nowadays, we rely on a properly performed intraoperative cholangiography. Preoperative cholangiography is probably indicated only for occasional case of potential living-related donor for children with Alagille syndrome.[56]

Step 3

Liver biopsy may be necessary at this stage, but the indication varies amongst centers in the world. Recognizing that donor deaths were due to unrecognized lipid disorder, unexpected liver pathology could be unveiled (as high as 21%–67%) by liver biopsy,[31,57-59] BMI is an inaccurate indicator of steatosis,[57,60] and imaging may miss moderate steatosis, many centers advocate liver biopsy routinely[61] or at a much lower threshold[31] in the donor evaluation protocol. Unlike liver biopsy for a diseased liver, liver biopsy for a normal liver probably carries a lower risk, but the cost benefit ratio of routine liver biopsy compared with selective policy of liver biopsy based on abnormal biochemical or radiological tests is not known. Perhaps liver biopsy should be done more liberally to preclude donation if a routine biopsy policy is not adopted or if the liver disease of the potential recipient has genetic predisposition.[58] In our center, we perform liver biopsy when the potential donor has a BMI of 27–30 (when fatty change is not obvious on CT scan), CT scan suggests abnormal pathology, the donor has unexplained hyperbilirubinemia with normal serum alanine aminotransferase (ALT) and aspartate aminotransferase (AST) levels, or unexplained transient elevation of serum ALT or AST. In Hong Kong, not infrequently, donors take herbal medicine as a "tonic" in preparation for the donor operations. If stopping the herbal medicine leads to normalization of serum liver enzymes, then liver biopsy is not done. Persons with isolated hyperbilirubinemia may have Gilbert's syndrome. They are diagnosed by genome DNA study showing mutations of uridine diphosphate glucuronosyltransferase 1. They are suitable for donor operation.[62]

Fatty liver is risky for both donors and recipients. Although fatty liver may not have serious liver function impairment, fatty livers are probably more vulnerable to injury by general anesthesia[63,64] and ischemia-reperfusion.[65] Moreover, fatty liver has a negative influence on liver regeneration. Fatty liver is suspected on ultrasonography or CT scan.[57] If the abnormality is serious, we do not perform liver biopsy and preclude the donor from further evaluation. It is noteworthy that the degree of fatty change varies throughout the liver and thus the biopsy result is subject to sampling errors.

Based on the histopathology finding, the percentage of fatty change acceptable for donation varies amongst centers, ranging from 10%–60%.[6,29,57,66] In our center, we accept liver grafts with macrovesicular steatosis up to 10%. However, many transplant centers have different view points. For example, a deceased donor graft of up to 30% steatosis is acceptable. For LDLT, liver grafts of up to 50% fatty change (or 60% for dual-graft operation)[67] have been used. The rationale of loosening the criteria for LDLT is that, despite a smaller graft size, the cold ischemic time could be shortened to the minimum. Rapid clearing of fat after graft implantation has been reported, probably a result of rapid utilization of fat in the early postoperative period.[67] Although the survival rates of such grafts are comparable with non-steatotic grafts, the recipients may have higher serum bilirubin levels after transplantation and an arduous clinical course.

The degree of fatty change may be factored into the liver graft size and remnant liver estimation. A large graft size is therefore needed to eliminate the ill-effect of fatty change.[61] Whether such assumption is correct is not known because ischemia-reperfusion injury in a fatty graft is generalized and the extent of injury is related to the degree of fatty change. Similar consideration may have to be made

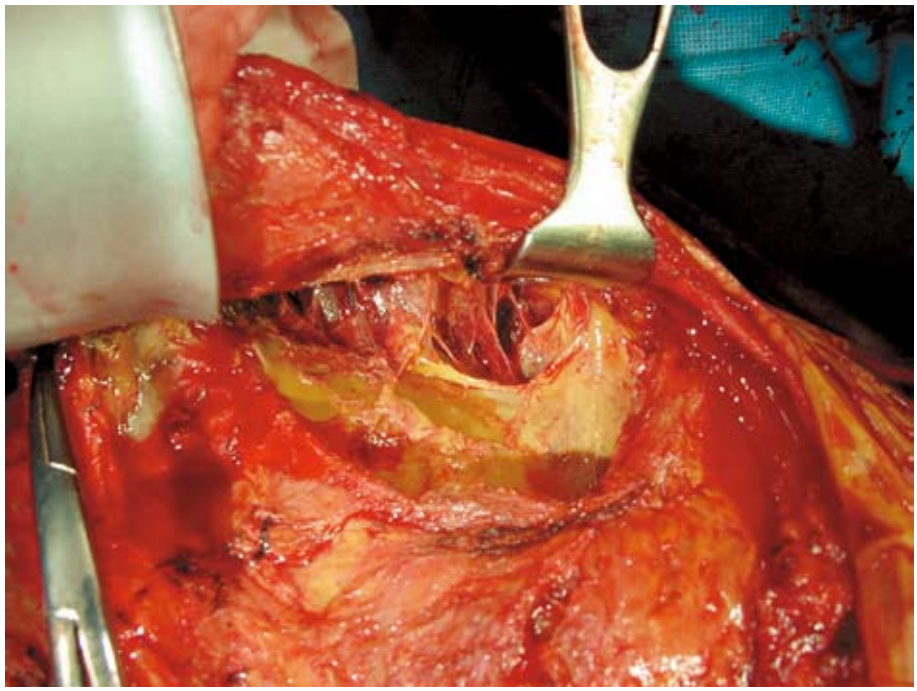

Figure 2.12. A recipient was found to have numerous vascular adhesions and purulent collection at the time of transplant operation. He had several episodes of spontaneous bacterial peritonitis prior to the laparotomy. The operation was terminated after several hours of attempted adhesiolysis. However, her daughter, the donor, was already half-way through the operation. Fortunately, the right hepatic duct had not been divided. Nevertheless, the family brought the case to the court after the recipient had died. The family complained that they had not been informed explicitly of the possibility of abortion of the donor or recipient operation.

on the remnant liver in the donor. A donor with a small liver remnant and moderate steatosis may not survive the operation.[31] In our practice, when fatty change of 10% or more is found and when the liver remnant is less than 30% of the total liver volume, right liver donor hepatectomy is not allowed. If the transplant is not urgent, it would be preferred to encourage the potential donor with fatty liver to reduce body weight and to perform vigorous exercises. Successful reduction of liver steatosis is possible and donation acceptable.[68,69] Additional measures include omega-3 polyunsaturated fatty acid supplementation[70] and benzafibrate.[69] However, one must distinguish between steatosis and steatohepatitis.[71] In the latter situation, the liver is chronically damaged and is not suitable for donation, irrespective of the percentage of fatty change. Exercise, diet control and drugs are less likely to reverse the pathology of steatohepatitis.

Step 4

This is the last step of the donor evaluation. The donor and recipient are individually interviewed again. In the consent form, the risk of operation, morbidity and mortality are clearly spelled out (Appendix II). The chance of not completing the operation is also explicitly stated in the consent form. The next-of-kin should sign on the consent form as well.

Obtaining an informed consent is the most important task before the operation. While the donor and recipient families have full trust on the transplant team, untoward events during or after the operation may change their attitudes. Exact documentation of the information released during the interview must be made to avoid future dispute. Unusual circumstances, such as the possibility of termination of donor or recipient operation, must also be explained fully and clearly. The most embarrassing situation occurs when the recipient dies on table,

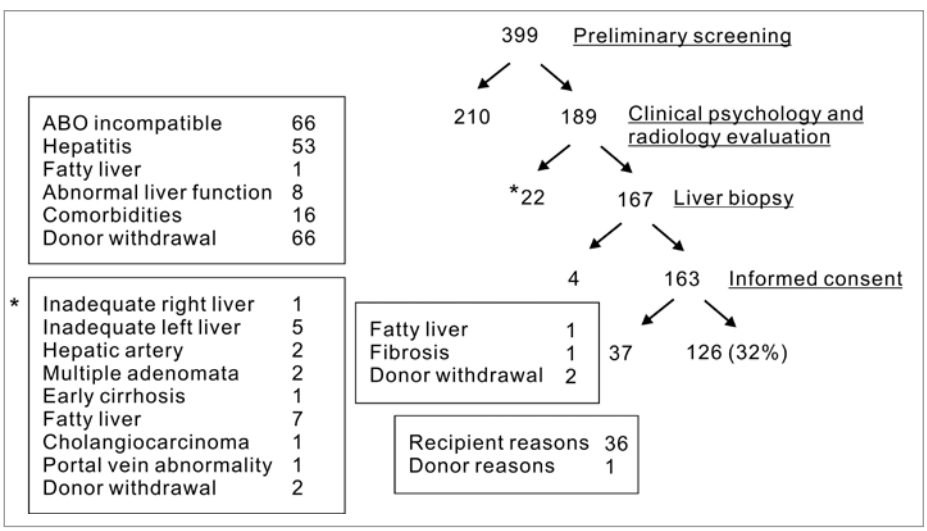

Figure 2.13. Steps in evaluation of 399 potential donors and reasons for exclusion.

but the liver graft is already partly or fully detached from the donor. Whether the graft should be sutured back to the donor, donated to an unrelated person, or discarded is arguable.[72,73] To avoid such situation, the donor team must liaise with the recipient team closely, especially when irreversible steps such as division of the right or left hepatic duct is going to be performed in the donor. Before the operation, the transplant team may have to obtain the consent from the family and relevant government organization or hospital ethics committee about the best way of disposal of the "orphan" graft if the recipient preoperative condition is precarious, e.g. suspected myocardial disease, previous multi-laparotomies, or numerous episodes of spontaneous bacterial peritonitis, which may lead to torrential bleeding or termination of the operation (Figure 2.12).

Outcome of donor evaluation

Based on the aforementioned steps of donor evaluation, about one-third of volunteers eventually underwent the donor operation in our center[74] (Figure 2.13). About 52% of potential donors dropped out in Step 1. Dropouts from Step 2a onward were few. The ultimate donation rate varies from center to center. It is 14% in Germany,[75] 17% in Spain,[76] and 40% in the USA.[77] The ultimate donation rate depends on the acceptance criteria of individual centers, but is also dependent on prior knowledge of the volunteer's blood type and hepatitis B status. In Hong Kong, many female potential donors who have given birth to children know their blood types and hepatitis B status. This accounts for the relatively high ultimate donation rate in our region.

High urgency versus elective LDLT

It is generally accepted that sufficient time must be provided to the donor for their reconsideration of decision to donate. It would be the ideal situation for a patient who is not critically ill. However, for patients with acute, acute-on-chronic or chronic liver failure and on life-support (equivalent to the United Network for Organ Sharing priority status I and IIA categories), rapid deterioration of the patients could be a constant source of pressure forcing the donor to make a quick decision. It is arguable whether, ethically, LDLT should be carried out for the high urgency patients.[78,79] However, in Asia, there are many patients with reactivation of hepatitis B lapsing into liver failure. In the absence of readily available deceased organ supply, LDLT is the only option to salvage them. With coordinated effort, it is not impossible to complete donor evaluation within 24 hours (including psychological evaluation and application to the Human Organ Transplant Board) in our center. Our recent study showed that the time for commencement of donor workup to transplant operation was 0.33 (range, 0.33–31) days for high urgency cases, whereas that for elective cases was 24 (range, 2–453) days ($P<0.001$).[74] It may be argued that donors are more ready to undergo emergency LDLT because of situational coercion. However, in this study, the ultimate donation rate of high urgency cases was actually lower than that of elective LDLT (28.4% vs 36.5%, $P=0.049$).[74] Whether donors operated in the emergency cases are more likely to regret their decisions is not yet known. One study suggested that donors operated for recipients with acute liver failure might have transient impairment of mental quality of life.[79] We have not observed such phenomenon yet. At our center, the results of emergency right liver LDLT are comparable with elective LDLT. Judging from the recipient outcome, LDLT for high urgency cases is justified, but expeditious donor workup, especially step 1, is required before the patient lapses into a stage beyond salvage.

Complications of donor evaluation

Complications related to donor evaluation may occur in steps 2b and 3 when CT and liver biopsy are performed. The incidence of contrast-induced nephropathy in intensive care unit patients is about 1%.[80] It may be much less in normal persons. Anaphylaxis to the radiographic contrast is another risk. MRI may be safer, but the imaging quality of MRI could be unpredictable. Similar to any procedure, informed consent for the contrast study is mandatory.

The risk of liver biopsy is bleeding, hemobilia and arterio-venous fistula. Similar to patients with liver diseases, the incidence of bleeding after liver

biopsy in donors is about 1%. However, liver biopsy could be associated with a complication rate of as high as 11% if the underlying medical problems are not detected.[81] The mortality related to liver biopsy is 0.01%.[82] Though the incidence is low, serious bleeding is life-threatening, requires intervention and defers the recipient operation. Occasionally, the recipient may never survive long enough to receive the operation.[31] Careful scrutiny of the donor is necessary before the liver biopsy.

Summary

Meticulous donor evaluation is the most important aspect of LDLT. Donor morbidity and mortality are not excusable, given the current medical care standard. Serious donor morbidity and mortality will have a major negative impact and loss of trust of the community with the transplant surgeons. Any center embarking on LDLT should establish a protocol and adhere to it. The donor will suffer from the donor operation. He/she should not have additional trauma and suffering out of negligence during evaluation.

References

1. Abecassis M, Adams M, Adams P, Arnold RM, Atkins CR, Barr ML, Bennett WM, Bia M, Briscoe DM, Burdick J, Corry RJ, Davis J, Delmonico FL, Gaston RS, Harmon W, Jacobs CL, Kahn J, Leichtman A, Miller C, Moss D, Newmann JM, Rosen LS, Siminoff L, Spital A, Starnes VA, Thomas C, Tyler LS, Williams L, Wright FH, Youngner S; Live Organ Donor Consensus Group. Consensus statement on the live organ donor. JAMA 2000; 284: 2919-2926.
2. Fan ST, Lo CM, Liu CL, Lam CM, Yuen WK, Yeung C, Wong J. Hepatectomy for hepatocellular carcinoma: toward zero hospital deaths. Ann Surg 1999; 229: 322-330.
3. Fan ST. Hepatectomy for hepatocellular carcinoma without hospital mortality. HK Practitioner 1999; 21: 51-54.
4. Torzilli G, Makuuchi M, Inoue K, Takayama T, Sakamoto Y, Sugawara Y, Kubota K, Zucchi A. No-mortality liver resection for hepatocellular carcinoma in cirrhotic and noncirrhotic patients: is there a way? A prospective analysis of our approach. Arch Surg 1999; 134: 984-992.
5. Wei AC, Poon RT, Fan ST, Wong J. Risk factors for perioperative morbidity and mortality after extended hepatectomy for hepatocellular carcinoma. Br J Surg 2003; 90: 33-41.
6. Soejima Y, Shimada M, Suehiro T, Kishikawa K, Yoshizumi T, Hashimoto K, Minagawa R, Hiroshige S, Terashi T, Ninomiya M, Shiotani S, Harada N, Sugimachi K. Use of steatotic graft in living-donor liver transplantation. Transplantation 2003; 76: 344-348.
7. Adams KF, Schatzkin A, Harris TB, Kipnis V, Mouw T, Ballard-Barbash R, Hollenbeck A, Leitzmann MF. Overweight, obesity, and mortality in a large prospective cohort of persons 50 to 71 years old. N Engl J Med 2006; 355: 763-778.
8. Hwang S, Lee SG, Lee YJ, Sung KB, Park KM, Kim KH, Ahn CS, Moon DB, Hwang GS, Kim KM, Ha TY, Kim DS, Jung JP, Song GW. Lessons learned from 1,000 living donor liver transplantations in a single center: how to make living donations safe. Liver Transpl 2006; 12: 920-927.
9. Liu CL, Lam B, Lo CM, Fan ST. Impact of right-lobe live donor liver transplantation on patients waiting for liver transplantation. Liver Transpl 2003; 9: 863-869.
10. Liu CL, Fan ST, Lo CM, Yong BH, Fung AS, Wong J. Right-lobe live donor liver transplantation improves survival of patients with acute liver failure. Br J Surg 2002; 89: 317-322.
11. Moss J, Lapointe-Rudow D, Renz JF, Kinkhabwala M, Dove LM, Gaglio PJ, Emond JC, Brown RS Jr. Select utilization of obese donors in living donor liver transplantation: implications for the donor pool. Am J Transpl 2005; 5: 2974-2981.
12. Fisher RA. Enabling altruism: evaluating the adult living liver donor. Liver Transpl 2007; 13: 478-479.
13. Florman S, Miller CM. Live donor liver transplantation. Liver Transpl 2006; 12: 499-510.
14. Obed A, Schnitzbauer AA, Bein T, Lehn N, Linde HJ, Schlitt HJ. Fatal pneumonia caused by Panton-Valentine Leucocidine-positive methicillin-resistant Staphylococcus aureus (PVL-MRSA) transmitted from a healthy donor in living-donor liver transplantation. Transplantation 2006; 81: 121-124.
15. Fan ST. Transmission of infection from live donor to recipient. Transplantation 2006; 81: 16.
16. Kiuchi T, Inomata Y, Uemoto S, Satomura K, Egawa H, Okajima H, Yamaoka Y, Tanaka K. A hepatic graft tuberculosis transmitted from a living-related donor. Transplantation 1997; 63: 905-907.
17. Smith RL, Bohl JK, McElearney ST, Friel CM, Barclay MM, Sawyer RG, Foley EF. Wound infection after elective colorectal resection. Ann Surg 2004; 239: 599-607.
18. Kabon B, Nagele A, Reddy D, Eagon C, Fleshman JW, Sessler DI, Kurz A. Obesity decreases perioperative tissue oxygenation. Anesthesiology 2004; 100: 274-280.
19. von Ungern-Sternberg BS, Regli A, Schneider MC, Kunz F, Reber A. Effect of obesity and site of surgery on perioperative lung volumes. Br J Anaesth 2004; 92: 202-207.
20. He M, Tan KC, Li ET, Kung AW. Body fat determination by dual energy X-ray absorptiometry and its relation to body mass index and waist circumference in Hong Kong Chinese. Int J Obes Relat Metab Disord 2001; 25: 748-752.
21. WHO Expert Consultation. Appropriate body-mass index for Asian populations and its implications for policy and intervention strategies. Lancet 2004; 363: 157-163.
22. Lo CM, Fan ST, Liu CL, Yong BH, Wong Y, Ng IO, Wong J. Safety and outcome of hepatitis B core antibody-positive donors in right-lobe living donor liver transplantation. Liver Transpl 2003; 9: 827-832.
23. Nery JR, Nery-Avila C, Reddy KR, Cirocco R, Weppler D, Levi DM, Nishida S, Madariaga J, Kato T, Ruiz P, Schiff E, Tzakis AG. Use of liver grafts from donors positive for antihepatitis B-core antibody (anti-HBc) in the era of prophylaxis with hepatitis-B immunoglobulin and lamivudine. Transplantation 2003; 75: 1179-1186.
24. Fabrega E, Garcia-Suarez C, Guerra A, Orive A, Casafont F, Crespo J, Pons-Romero F. Liver transplantation with allografts from hepatitis B core antibody-positive donors: a new approach. Liver Transpl 2003; 9: 916-920.
25. Umeda M, Marusawa H, Ueda M, Takada Y, Egawa H, Uemoto S, Chiba T. Beneficial effects of short-term lamivudine treatment for de novo hepatitis B virus reactivation after liver transplantation. Am J Transplant 2006; 6: 2680-2685.
26. Malago M, Testa G, Frilling A, Nadalin S, Valentin-Gamazo C, Paul A, Lang H, Treichel U, Cicinnati V, Gerken G, Broelsch CE. Right living donor liver transplantation: an option for adult patients: single institution experience with 74 patients. Ann

Surg 2003; 238: 853-863.
27. Miller C, Florman S, Kim-Schluger L, Lento P, De La Garza J, Wu J, Xie B, Zhang W, Bottone E, Zhang D, Schwartz M. Fulminant and fatal gas gangrene of the stomach in a healthy live liver donor. Liver Transpl 2004; 10: 1315-1319.
28. Polido W Jr, Hoe LK, Siang NK, Chah TK. Acute myocardial infarction after live donor liver surgery. Liver Transpl 2007; 13: 154-156.
29. Brandhagen D, Fidler J, Rosen C. Evaluation of the donor liver for living donor liver transplantation. Liver Transpl 2003; 9(10 Suppl 2): S16-S28.
30. Durand F, Ettorre GM, Douard R, Denninger MH, Kianmanesh A, Sommacale D, Farges O, Valla D, Belghiti J. Donor safety in living related liver transplantation: Underestimation of the risks for deep vein thrombosis and pulmonary embolism. Liver Transpl 2002; 8: 118-120.
31. Nadalin S, Malago M, Valentin-Gamazo C, Testa G, Baba HA, Liu C, Fruhauf NR, Schaffer R, Gerken G, Frilling A, Broelsch CE. Preoperative donor liver biopsy for adult living donor liver transplantation: risks and benefits. Liver Transpl 2005; 11: 980-986.
32. Walter M, Papachristou C, Danzer G, Klapp BF, Frommer J. Willingness to donate: an interview study before liver transplantation. J Med Ethics 2004; 30: 544-550.
33. Merten GJ, Burgess WP, Gray LV, Holleman JH, Roush TS, Kowalchuk GJ, Bersin M, Van Moore A, Simonton CA 3rd, Rittase RA, Norton HJ, Kennedy TP. Prevention of contrast-induced nephropathy with sodium bicarbonate: a randomized controlled trial. JAMA 2004; 291: 2328-2334.
34. Imamura H, Makuuchi M, Sakamoto Y, Sugawara Y, Sano K, Nakayama A, Kawasaki S, Takayama T. Anatomical keys and pitfalls in living donor liver transplantation. J Hepatobiliary Pancreat Surg 2000; 7: 380-394.
35. Chan SC, Lo CM, Liu CL, Wong Y, Fan ST, Wong J. Tailoring donor hepatectomy per segment 4 venous drainage in right lobe live donor liver transplantation. Liver Transpl 2004; 10: 755-762.
36. Lee SG, Hwang S, Kim KH, Ahn CS, Park KM, Lee YJ, Moon DB, Chu CW, Yang HS, Cho SH, Oh KB, Ha TY, Song KW, Yu YS, Min PC. Approach to anatomic variations of the graft portal vein in right lobe living-donor liver transplantation. Transplantation 2003; 75(3 Suppl): S28-S32.
37. Couinaud C. Surgical anatomy of the liver revisited. 1989. [ISBN 2-903672-01-6]
38. Heymsfield SB, Fulenwider T, Nordlinger B, Barlow R, Sones P, Kutner M. Accurate measurement of liver, kidney, and spleen volume and mass by computerized axial tomography. Ann Intern Med 1979; 90: 185-187.
39. Fan ST, Lo CM, Liu CL, Yong BH, Chan JK, Ng IO. Safety of donors in live donor liver transplantation using right lobe grafts. Arch Surg 2000; 135: 336-340.
40. Kiuchi T, Tanaka K, Ito T, Oike F, Ogura Y, Fujimoto Y, Ogawa K. Small-for-size graft in living donor liver transplantation: how far should we go? Liver Transpl 2003; 9: S29-S35.
41. Lo CM, Fan ST, Liu CL, Wei WI, Lo RJW, Lai CL, Chan JKF, Ng IO, Fung A, Wong J. Adult-to-adult living donor liver transplantation using extended right lobe graft. Ann Surg 1997; 226: 261-270.
42. Ibrahim S, Chen CL, Wang CC, Wang SH, Lin CC, Liu YW, Yang CH, Yong CC, Concejero A, Cheng YF. Small remnant liver volume after right lobe living donor hepatectomy. Surgery 2006; 140: 749-755.
43. Sugawara Y, Makuuchi M, Takayama T, Imamura H, Dowaki S, Mizuta K, Kawarasaki H, Hashizume K. Small-for-size grafts in living-related liver transplantation. J Am Coll Surg 2001; 192: 510-513.
44. Heinemann A, Wischhusen F, Puschel K, Rogiers X. Standard liver volume in the Caucasian population. Liver Transpl Surg 1999; 5: 366-368.
45. Urata K, Kawasaki S, Matsunami H, Hashikura Y, Ikegami T, Ishizone S, Momose Y, Komiyama A, Makuuchi M. Calculation of child and adult standard liver volume for liver transplantation. Hepatology 1995; 21: 1317-1321.
46. Chan SC, Liu CL, Lo CM, Lam B, Lee E, Wong Y, Fan ST. Estimating liver weight of adults by body weight and gender. World J Gastroenterol 2006; 12: 2217-2222.
47. Yu HC, You H, Lee H, Jin ZW, Moon JI, Cho BH. Estimation of standard liver volume for liver transplantation in the Korean population. Liver Transpl 2004; 10: 779-783.
48. Chandramohan A, Eapen A, Govil S, Govil S, Jeyaseelan V. Determining standard liver volume: assessment of existing formulae in Indian population. Indian J Gastroenterol 2007; 26: 22-25.
49. Chouker A, Martignoni A, Dugas M, Eisenmenger W, Schauer R, Kaufmann I, Schelling G, Lohe F, Jauch KW, Peter K, Thiel M. Estimation of liver size for liver transplantation: the impact of age and gender. Liver Transpl 2004; 10: 678-685.
50. Hashimoto T, Sugawara Y, Tamura S, Hasegawa K, Kishi Y, Kokudo N, Makuuchi M. Estimation of standard liver volume in Japanese living liver donors. J Gastroenterol Hepatol 2006; 21: 1710-1713.
51. DuBois D, DuBois EF. A formula to estimate the approximate surface area if height and weight be known. Arch Intern Med 1916; 17: 863.
52. Fulcher AS, Szucs RA, Bassignani MJ, Marcos A. Right lobe living donor liver transplantation: preoperative evaluation of the donor with MR imaging. AJR Am J Roentgenol 2001; 176: 1483-1491.
53. An SK, Lee JM, Suh KS, Lee NJ, Kim SH, Kim YJ, Han JK, Choi BI. Gadobenate dimeglumine-enhanced liver MRI as the sole preoperative imaging technique: a prospective study of living liver donors. AJR Am J Roentgenol 2006; 187: 1223-1233.
54. Wietzke-Braun P, Braun F, Muller D, Lorf T, Ringe B, Ramadori G. Adult-to-adult right lobe living donor liver transplantation: comparison of endoscopic retrograde cholangiography with standard T2-weighted magnetic resonance cholangiography for evaluation of donor biliary anatomy. World J Gastroenterol 2006; 12: 5820-5825.
55. Schroeder T, Malago M, Debatin JF, Testa G, Nadalin S, Broelsch CE, Ruehm SG. Multidetector computed tomographic cholangiography in the evaluation of potential living liver donors. Transplantation 2002; 73: 1972-1973.
56. Gurkan A, Emre S, Fishbein TM, Brady L, Millis M, Birnbaum A, Kim-Schluger L, Sheiner PA. Unsuspected bile duct paucity in donors for living-related liver transplantation: two case reports. Transplantation 1999; 67: 416-418.
57. Limanond P, Raman SS, Lassman C, Sayre J, Ghobrial RM, Busuttil RW, Saab S, Lu DS. Macrovesicular hepatic steatosis in living related liver donors: correlation between CT and histologic findings. Radiology 2004; 230: 276-280.
58. Hasegawa Y, Kawachi S, Shimazu M, Hoshino K, Tanabe M, Fuchimoto Y, Obara H, Shinoda M, Shimizu H, Yamada Y, Akatsu T, Irie R, Sakamoto M, Morikawa Y, Kitajima M. Discontinuation of living donor liver transplantation for PSC due to histological abnormalities in intraoperative donor liver biopsy. Am J Transplant 2007; 7: 2204-2207.
59. Tran TT, Changsri C, Shackleton CR, Poordad FF, Nissen NN, Colquhoun S, Geller SA, Vierling JM, Martin P. Living donor liver transplantation: histological abnormalities found on liver biopsies of apparently healthy potential donors. J Gastroenterol Hepatol 2006; 21: 381-383.
60. Ryan CK, Johnson LA, Germin BI, Marcos A. One hundred consecutive hepatic biopsies in the workup of living donors for right lobe liver transplantation. Liver Transpl 2002; 8: 1114-1122.
61. Marcos A, Ham JM, Fisher RA, Olzinski AT, Posner MP. Single-center analysis of the first 40 adult-to-adult living donor

liver transplants using the right lobe. Liver Transpl 2000; 6: 296-301.
62. Kaneko J, Sugawara Y, Maruo Y, Sato H, Tamura S, Imamura H, Kokudo N, Makuuchi M. Liver transplantation using donors with Gilbert syndrome. Transplantation 2006; 82: 282-285.
63. Hui AM, Kawasaki S, Makuuchi M, Nakayama J, Ikegami T, Miyagawa S. Liver injury following normothermic ischemia in steatotic rat liver. Hepatology 1994; 20: 1287-1293.
64. Hakamada K, Sasaki M, Takahashi K, Umehara Y, Konn M. Sinusoidal flow block after warm ischemia in rats with diet-induced fatty liver. J Surg Res 1997; 70: 12-20.
65. Friedman LS, Maddrey WC. Surgery in the patient with liver disease. Med Clin North Am 1987; 71: 453-476.
66. Rinella ME, Alonso E, Rao S, Whitington P, Fryer J, Abecassis M, Superina R, Flamm SL, Blei AT. Body mass index as a predictor of hepatic steatosis in living liver donors. Liver Transpl 2001; 7: 409-414.
67. Moon D, Lee S, Hwang S, Kim K, Ahn C, Park K, Ha T, Song G. Resolution of severe graft steatosis following dual-graft living donor liver transplantation. Liver Transpl 2006; 12: 1156-1160.
68. Hwang S, Lee SG, Jang SJ, Cho SH, Kim KH, Ahn CS, Moon DB, Ha TY. The effect of donor weight reduction on hepatic steatosis for living donor liver transplantation. Liver Transpl 2004; 10: 721-725.
69. Nakamuta M, Morizono S, Soejima Y, Yoshizumi T, Aishima S, Takasugi S, Yoshimitsu K, Enjoji M, Kotoh K, Taketomi A, Uchiyama H, Shimada M, Nawata H, Maehara Y. Short-term intensive treatment for donors with hepatic steatosis in living-donor liver transplantation. Transplantation 2005; 80: 608-612.
70. Alwayn IP, Andersson C, Zauscher B, Gura K, Nose V, Puder M. Omega-3 fatty acids improve hepatic steatosis in a murine model: potential implications for the marginal steatotic liver donor. Transplantation 2005; 79: 606-608.
71. Yamamoto K, Takada Y, Fujimoto Y, Haga H, Oike F, Kobayashi N, Tanaka K. Nonalcoholic steatohepatitis in donors for living donor liver transplantation. Transplantation 2007; 83: 257-262.
72. Nadalin S, Malago M, Testa G, Schaffer R, Sotiropoulos GC, Frilling A, Broelsch CE. "Hepar divisum" – as a rare donor complication after intraoperative mortality of the recipient of an intended living donor liver transplantation. Liver Transpl 2006; 12: 428-434.
73. Siegler J, Siegler M, Cronin DC 2nd. Recipient death during a live donor liver transplantation: who gets the "orphan" graft? Transplantation 2004; 78: 1241-1244.
74. Chan SC, Fan ST, Liu CL, Lo CM, Lam BKY, Lee EWM. Working up donors for high-urgency and elective adult-to-adult live donor liver transplantation. Liver Transpl 2007; 13: 509-515.
75. Valentin-Gamazo C, Malago M, Karliova M, Lutz JT, Frilling A, Nadalin S, Testa G, Ruehm SG, Erim Y, Paul A, Lang H, Gerken G, Broelsch CE. Experience after the evaluation of 700 potential donors for living donor liver transplantation in a single center. Liver Transpl 2004; 10: 1087-1096.
76. Rimola A, Llovet JM, Navasa M, Bruix J, Londono MC, Fuster J, Garcia-Valdecasas JC. Applicability of adult-to-adult living donor liver transplantation. J Hepatol 2005; 43: 104-109.
77. Trotter JF, Wisniewski KA, Terrault NA, Everhart JE, Kinkhabwala M, Weinrieb RM, Fair JH, Fisher RA, Koffron AJ, Saab S, Merion RM; A2ALL Study GroupThis is publication number 5 of the Adult-to-Adult Living Donor Liver Transplantation Cohort Study. Outcomes of donor evaluation in adult-to-adult living donor liver transplantation. Hepatology 2007; 46: 1476-1484.
78. Hertl M, Cosimi AB. Primum nil nocere. Transplantation 2003; 76: 1539-1540.
79. Erim Y, Beckmann M, Kroencke S, Valentin-Gamazo C, Malago M, Broering D, Rogiers X, Frilling A, Broelsch CE, Schulz KH. Psychological strain in urgent indications for living donor liver transplantation. Liver Transpl 2007; 13: 886-895.
80. Haveman JW, Gansevoort RT, Bongaerts AH, Nijsten MW. Low incidence of nephropathy in surgical ICU patients receiving intravenous contrast: a retrospective analysis. Intensive Care Med 2006; 32: 1199-1205.
81. Terjung B, Lemnitzer I, Dumoulin FL, Effenberger W, Brackmann HH, Sauerbruch T, Spengler U. Bleeding complications after percutaneous liver biopsy. An analysis of risk factors. Digestion 2003; 67: 138-145.
82. Piccinino F, Sagnelli E, Pasquale G, Giusti G. Complications following percutaneous liver biopsy. A multicentre retrospective study on 68,276 biopsies. J Hepatol 1986; 2: 165-173.

Appendix I

Information for patients (and their families) waiting for liver transplantation at Queen Mary Hospital, The University of Hong Kong

What is liver transplantation?
Liver transplantation is the best treatment for end-stage liver disease in both adults and children. In this operation, the diseased liver is removed and replaced by a healthy one. The success rate for the operation is high and terminally ill patients can return to normal lives. The liver transplant service at Queen Mary Hospital was initiated in 1991. Until now, over 580 liver transplants have been performed and the success rate is over 90% in recent years.

Who needs a liver transplant?
The following diseases are common indications for liver transplantation:

1. Cirrhosis due to chronic hepatitis B, hepatitis C or other causes
2. Acute liver failure
3. Metabolic diseases, e.g. Wilson disease
4. Selected patients with early liver cancer and poor liver function
5. Biliary atresia

When should a liver transplant be performed?
When your liver is severely damaged and cannot function properly, the following complications may develop and liver transplantation should be considered:

1. Hepatic coma
2. Massive upper gastrointestinal bleeding
3. Abdominal distension from fluid collection and ankle edema
4. Infection of fluid in the abdomen
5. Bleeding tendency
6. Jaundice (yellowing of the eye balls)
7. General weakness and malaise resulting in poor quality of life
8. Liver cancer best treated by complete removal of the liver
9. Failure to grow in children

In general, when you need a new liver, the earlier the operation, the higher is the success rate.

What will happen after a liver transplant?
The overall success rate of a liver transplant is over 90% and the majority of liver transplant recipients can return to normal activities. Since your body may reject the new liver, it is essential for you to take immunosuppressive medications and continue follow-up at our Liver Transplant Clinic. You may need to continue these medications for a very long period of time, but at a reducing amount.

Where does the liver graft come from?
Your new liver can come from either of the two sources: a brain-dead deceased donor or a living donor.

1. Brain-dead deceased donor:
You will be put on a waiting list for a brain-dead deceased donor liver and receive a liver graft according to the following criteria:

1. Your blood group matching
2. The urgency of your operation
3. Severity of your liver disease according to the Model for End-stage Liver Disease (MELD) score (for adult patients and pediatric patients aged 12 to 17) or Pediatric End-stage Liver Disease (PELD) score (for patients under age 12)
4. Your waiting time

MELD stands for Model for End-stage Liver Disease. It is a scoring system used for liver allocation in adult patients. The score predicts a patient's risk of dying within 3 months without transplantation. It is calculated by a formula based on the patient's serum total bilirubin, creatinine, and international normalized ratio readings. The scores range from a minimum of 6 to a maximum of 40 (patients with a score higher than 40 are not given extra priority). The score is updated regularly as the patient may deteriorate while waiting. The scoring system makes sure that the liver is allocated to the most critical patient with the highest score at that time on the waiting list.

PELD stands for Pediatric End-stage Liver Disease. It is a scoring system used for liver allocation in pediatric patients (under age 12). The score predicts a patient's risk of dying within 3 months without transplantation. It is calculated by a formula based on the patient's serum total bilirubin, albumin, international normalized ratio readings, growth failure (based on sex, body weight, and body height), and age at listing. The scores range from –10 to 40 or higher. The score is updated regularly as the patient may deteriorate while waiting. The scoring system makes sure that the liver is allocated to the most critical patient with the highest score at that time on the waiting list.

Patients suffering from metabolic diseases are given extra 2 points every 3 months after waitlisted. No extra points will be given to patients with hepatocellular carcinoma. In cases where patients have the same scores, waiting time will be considered for prioritization. Organ donation requires consent from the donor's family and there is no monetary reward. The timing of such donation is unpredictable and the operation usually starts at night. You may be called into the hospital at any time and on any day once you are put on list. It is therefore necessary for you to carry a pager/mobile phone and be prepared to report to the hospital within 2 hours of receiving the call.

Unfortunately, the supply of deceased donor livers in Hong Kong is limited and for the past few years, an average of 20 liver grafts only are available each year. Depending on your blood group, you may have to wait for 12 to 36 months before you get a new liver. During this waiting period, you may develop complications and your condition may deteriorate. One of the complications is called spontaneous bacterial peritonitis which, if repetitive, may produce severe adhesion in your abdomen rendering liver transplantation difficult or impossible to proceed. Overall, the complications of liver disease would adversely affect the success rate of the transplant. In fact, at Queen Mary Hospital, about 40% of patients die before getting a new liver and for those acutely ill patients waiting in the Intensive Care Unit, less than 10% will be able to receive a new liver in time.

When a potential deceased donor liver graft is allocated to you, you will be called to admit to the hospital by our liver transplant coordinator. You should inform your family members of the situation and start fasting immediately. It will be useful to bring along all your prescribed medications to the hospital. A series of tests and investigations (i.e. blood tests, cultures, electrocardiography, and chest X-ray) and assessment by the anesthetist will be performed on you promptly after admission. You will be explained on the nature, purpose, and risks of the operation by our transplant surgeons in the ward. You are also required to sign a consent form referring to the success rate, complication rate, a chance that the operation cannot be accomplished, and a risk of transmission of cancer or diseases from the cadaveric organ. For an adult patient who is comatose or mentally incapacitated, the patient's guardian or next-of-kin should sign the consent form. For a minor patient (age under 18 years) who is unfit or unable to sign the form, the patient's parent, guardian or next-of-kin should sign the form.

It is important for you and your family to understand that assessments and investigations on the potential deceased

donor are on-going and unexpected changes may happen to the donor's medical conditions. There are certain circumstances that may render the donor unsuitable for donation even when you have been admitted to the hospital:

1. Hepatitis B or hepatitis C or human immunodeficiency virus positivity of the donor
2. Unstable hemodynamics of the donor
3. Unhealthy, abnormal or doubtful appearance or pathology of the liver graft on examination by the harvesting surgeons during the donor operation
4. Suspected malignant tumor(s) found during donor operation

In case the transplant operation is unable to proceed, a transplant surgeon will explain to you the reason for the abortion of the operation. You will then be discharged from the hospital. The next available potential graft will be allocated to the patient with the highest MELD / PELD score on the waiting list at that time.

2. Living donor

It is now technically feasible to remove part of the liver from a living person and transplant it to a patient who needs a new liver. The operation has been developed for children since 1989 and for adult patients since 1994. Depending on the size matching of the donor and recipient, either the left side (about 35%) or the right side (65%) of the liver will have to be removed. The liver remnant in the donor will grow to its original size in 2 to 3 months' time.

In considering the option of living donor liver transplantation, you should carefully balance the benefits for the recipient against the risk for the living donor.

Benefits for the recipient:

- Earlier transplantation before the recipient's condition deteriorates
- Avoid the risk of death while waiting for a deceased donor liver graft (40% overall and 90% for patients in the Intensive Care Unit)
- Good-quality liver graft from a living donor
- A 1-year survival rate of about 90%

Risks for the donor:

- Pain, discomfort, and complications of the investigations and surgical procedure
- Average hospital stay of 7–14 days
- Average loss of work of 6–8 weeks
- A permanent surgical scar
- Complication rate of about 20% (wound infection, hernia, bleeding, bile leakage, bile duct problems, infection, pneumonia, liver failure which may require liver transplant, etc)
- Possibility of death (estimated death rate of 0.5%–1%). Seventeen donor deaths have been reported in Brazil, Egypt, Europe, Hong Kong, India, Japan, and USA.

Who can be a suitable living donor?

The most important criterion for a living liver donor is true voluntarism without any element of coercion. Anyone who would consider acting as a living liver donor should understand clearly:

1. That the donor operation carries suffering and risks (complication rate of 20% and the possibility of death).
2. That the recipient operation may not be successful (average success rate 90%).
3. That his decision for donation should be out of his own wish without any external pressure from the hospital staff or other family members.
4. That there is and will not be any financial gain related to the act of donation.
5. That he has the right to withdraw at any time without the need of giving any reason to do so.

The liver transplant team will consider anyone who understands the above criteria and who has demonstrated true voluntarism as a potential living donor. This potential donor will then undergo evaluation including blood tests, CT scan, hepatic arteriogram and percutaneous liver biopsy if necessary. Depending on the clinical situation, these procedures will usually take half a day to a week. In certain cases, the Law requires that an approval be obtained from the Human Organ Transplant Board before the transplant can be performed. If you have any questions, please contact the Liver Transplant Clinical Coordinator.

Description of donor operation

Depending on the size and requirement of the recipient, the donor may donate the left lateral segment (about 20%), left liver (about 35%), or right liver (about 65%) of the liver. On the day before the operation, the donor will have her bowel cleared by laxative. He/she is not allowed to eat or drink for about 8 hours before the operation. The operation is done under general anesthesia. If there is suspicion of the suitability for liver donation, the surgeon may perform a laparoscopy through a tiny umbilical wound. Otherwise, a long skin incision will be made. Please see Figure 1 for the usual location and approximate length of the incision. After deciding the liver is normal and suitable for donation, the surgeon will remove the gallbladder and cannulate the cystic duct for operative cholangiography. The gallbladder is removed because it lies in the midplane of the liver and will interfere with the liver transection. The absence of the gallbladder in the donor will not affect the quality of life afterward. Next, the relevant inflow and outflow blood vessels and bile duct are freed. The liver is then transected at the plane depending on the type of liver donation. Finally, the donated part of the liver is removed after all the relevant inflow and outflow blood vessels are divided and ligated. The wound is then sutured.

The duration of the operation is approximately 6 hours, but it may be longer. There are possibilities that the donor operation is stopped because of the following reasons:

1. The donor liver is found to be abnormal and not suitable for donation.
2. The recipient is found for various reasons not suitable for liver transplantation after laparotomy is performed.

Members of the Transplant Team at Queen Mary Hospital are meticulous in preoperative assessment of the donor and recipient for the suitability of transplantation, but there is always possibility of unexpected findings at laparotomy that deter the transplant operation. In this situation, the donor may have an abdominal wound, although he/she has not gone through the donor hepatectomy.

The donor operation is performed simultaneously with the recipient operation in order to match the time of removal of the diseased liver and implantation of the new liver.

Description of recipient operation

Skin incision similar to that of the donor (usually longer) will be made. On entering the abdomen, the surgeon will decide whether it is feasible to proceed with the operation. The operation may have to stop if:

1. fluid inside the abdominal cavity is infected;
2. severe adhesion that prevents dissection of the liver and its inflow and outflow blood vessels is present. Severe adhesion is usually due to recurrent infection and previous operation in the abdominal cavity; or
3. cancer spread is found.

Despite meticulous effort to rule out the above possibilities, there is still a chance of inability of preoperative assessment diagnosing the condition that makes the transplant unfeasible.

After excluding the condition that contraindicates liver transplantation, the surgeon will free the liver inflow and outflow blood vessels and remove the diseased liver. The liver graft is then implanted into the original position of the diseased liver. By connecting the relevant blood vessels and bile duct, the operation is completed. The whole operation may take about 12 hours or longer, depending on the patient's condition.

After the operation, the recipient will be treated in the Intensive Care Unit. The duration of stay in the Intensive Care Unit depends on the rapidity of recovery.

The recipient operation carries a possibility of death. The estimated complication rate of the recipient operation is about 15%–20% for cadaveric liver transplantation and 30% for living donor liver transplantation.

Some major complications include:
- thrombosis of the hepatic artery, hepatic vein, or portal vein
- primary graft non-function
- delayed graft function
- bile duct complication
- graft failure due to hepatitis, recurrent disease, or rejection
- intra-abdominal bleeding
- sepsis
- renal failure
- recurrence of liver cancer

Some minor complications include:
- wound infection
- chest problem (i.e. infection, pleural effusion or pulmonary edema)
- diabetes mellitus
- hypertension

It is emphasized that standard clinical history and necessary evaluations are taken for the potential cadaveric and living donors before the donation. Despite our best effort to rule out the possibility of cancer or disease transmission to the recipients through organ donation, there is still a chance of inability of diagnosing them. The risk of transmission is low yet cannot be totally eliminated.

Recipients are required to take long-term immunosuppressive medications after transplantation. The current immunosuppressive protocol consists of FK506 (Tacrolimus) and prednisolone double-drug therapy for pediatric patients, and FK506 and MMF (Cellcept) double-drug therapy for adult patients. The dosage of the medications varies among patients. Other commonly used medications include: 1) lamivudine for prevention of reinfection of hepatitis B, 2) fluconazole or nystatin for prevention of candida infection, 3) acyclovir for prevention of cytomegalovirus (CMV) infection, and 4) septrin for prevention of pneumonia.

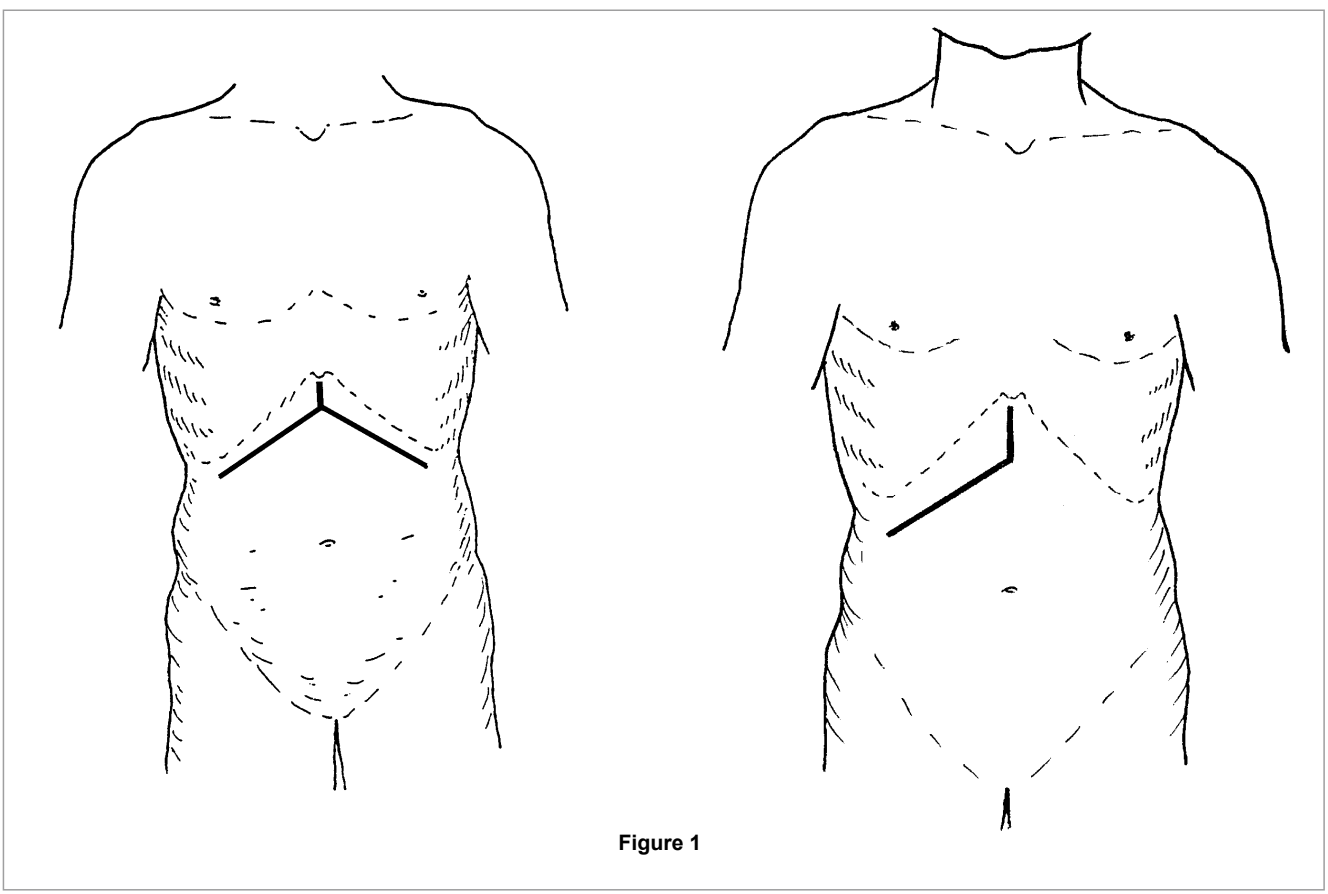

Figure 1

Appendix II

The University of Hong Kong
Department of Surgery
Division of Liver Transplantation

CONSENT

Living Donor Liver Transplantation

I, (ID No. _____), hereby consent to undergo the operation of donor hepatectomy to donate the _____ of my liver to _____ (ID No._____). I have read the information on the nature, purpose and risks of the operation. I have been informed that the operation may carry a complication rate of 15%, a death rate of 0.5%, and a possibility of liver failure requiring liver transplant. The success rate of the recipient operation is _____%. I also understand that the chance of not having the donor operation completed is about 5%. These have been explained to me by Dr. _____ (Staff No._____) and Dr._____ (Staff No._____).

My decision for donation is truly voluntary and there has not been any external pressure from the hospital staff or other family members. I understand that there will not be any financial gain related to the act of donation and I have the right to withdraw at any time without the need to give any reason of doing so.

_____	_____	_____
Name of patient (in block letters)	Signature of patient	Date
_____	_____	_____
Name of next-of-kin (in block letters)	Signature of next-of-kin	Date
_____	_____	_____
Name of doctor (in block letters)	Signature of doctor	Date
_____	_____	_____
Name of witness (in block letters)	Signature of witness	Date

The University of Hong Kong
Department of Surgery
Division of Liver Transplantation

CONSENT

Living Donor Liver Transplantation

I, _____ (ID No. _____), hereby consent to undergo the operation of total hepatectomy and living donor liver transplant to receive the _____ of liver from _____(ID No. _____).

I have read the information on the nature, purpose and risks of the operation, including the risk of transmission of cancer or diseases from the living donor organ through the transplantation, and these were also explained to me by Dr. _____ (Staff No. _____) and Dr. _____ (Staff No. _____). I have been informed that the donor operation may carry a complication rate of 15%, a death rate of 0.5%–1%, and a possibility of liver failure requiring liver transplant. The recipient operation may carry a complication rate of 30% and a death rate of 5%–10%. The recipient operation may take 8–12 hours or longer and the chance that the operation cannot be accomplished is about 5%. I understand that there will not be any financial gain for the donor related to the act of donation.

_____	_____	_____
Name of patient (in block letters)	Signature of patient	Date
_____	_____	_____
Name of next-of-kin (in block letters)	Signature of next-of-kin	Date
_____	_____	_____
Name of doctor (in block letters)	Signature of doctor	Date
_____	_____	_____
Name of witness (in block letters)	Signature of witness	Date

3. Segment II / III graft

Donor operation

The donor is placed in a position to avoid ankle and occiput pressure sores and brachial plexus injury. Devices to prevent hypothermia and deep vein thrombosis are provided. Prophylactic antibiotic and H_2-receptor antagonist are given at the time of induction of general anesthesia. Bilateral subcostal incision with upward midline extension is employed. A midline incision is sometimes feasible for a thin donor. The xiphisternum is excised so that the suprahepatic inferior vena cava (IVC) could be viewed vertically rather than from the caudal end after application of the self-retaining retractor (Bookwalter, Codman and Shurtleff, Inc, Raynham, MA, USA). Such exposure is important and necessary for liver transection at the cranial part, for safe dissection of the left hepatic vein (LHV), and for vertical application of the vascular stapler [TA30, V3 (2.5 mm), United States Surgical, CT, USA] on the LHV at the time of graft delivery (Figure 3.1).

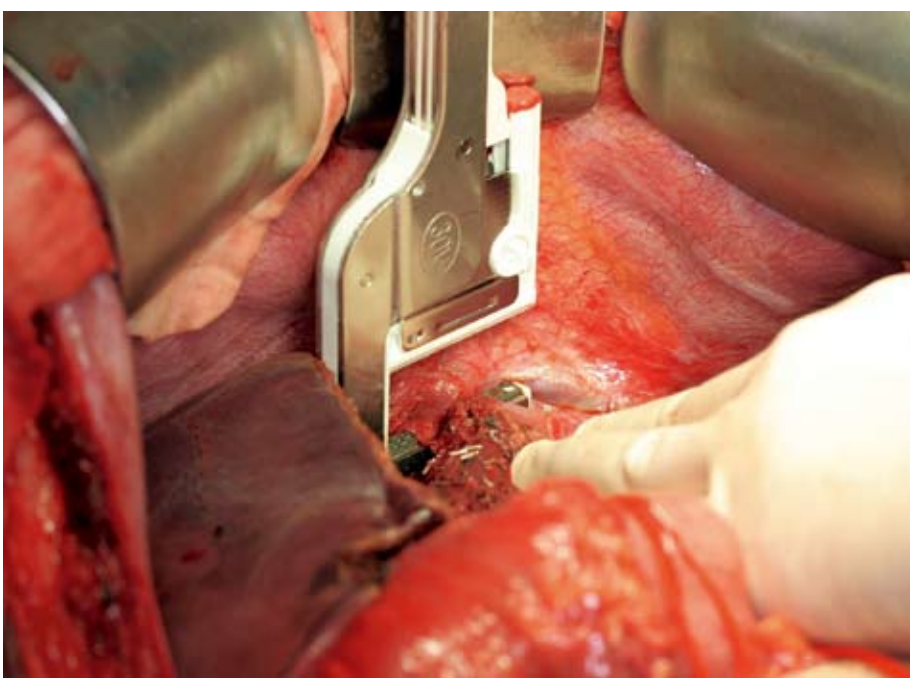

Figure 3.1. Segment II/III graft donor operation. Before delivery of the graft, the left hepatic vein is occluded by the vascular stapler. To produce the best effect, the stapler has to be applied vertically. Only a sufficiently retracted midline incision (in the cranial direction) will allow vertical application of the stapler.

Intraoperative ultrasonography and Doppler study are then performed mainly to study the anatomical arrangement of the segment II, III, and IV hepatic veins. An umbilical vein may be present at the plane of the falciform ligament (Figure 3.2). It must be preserved to improve venous drainage of the graft especially when part of segment IV is included in the graft. A branch of segment II hepatic vein may be separate from the main trunk of the LHV at the junction with the IVC (Figure 3.3). It may be superficial on the liver surface and damaged inadvertently when the left triangular ligament is divided. Prior recognition will ensure protection and incorporation into the LHV for establishing perfect venous drainage of the graft. On Doppler ultrasonography, the branches of the left hepatic artery (LHA) on the right and left sides of the umbilical fissure are identified and their locations ascertained. Doppler study at this stage will help to locate the LHA after reperfusion of the graft.

Cholecystectomy is performed and the cystic duct is cannulated by a Fr 3.5 Argyle catheter (Tyco Healthcare, Mansfield, MA, USA). It will be used for operative cholangiography and checking for bile leakage. Some surgeons suggested that cholecystectomy is not needed for segment II/III donation. However, because the gallbladder is denervated during the procedure, the likelihood of gallstone formation would override the benefit of preserving the gallbladder. Cholecystectomy is also preferred for cystic duct cannulation and cholangiography.

The liver hilum is then gently dissected to expose the left hepatic duct (LHD). A large-size Liga clip (Ethicon



Figure 3.2. Computed tomography scan shows an umbilical vein at the plane of falciform ligament (arrow). Separate segment III and II hepatic veins could be traced on serial sections of the computed tomography scan.

Ltd, Edinburgh, UK) is then applied to the liver capsule to mark the site of proposed transection of the LHD on the cholangiogram. The supraduodenal portion of the common bile duct is then mobilized for application of an atraumatic bulldog vascular clamp (Featherlight Bulldog Clamp, Geister, Inc, Tuttlingen, Germany) (Figure 3.4), which will facilitate complete filling of the intrahepatic ducts (Figure 3.5). Under fluoroscopic screening, undiluted radiographic contrast is slowly injected into the common bile duct. The sequence of filling of the intrahepatic ducts is observed. The LHD, the segment II and III ducts, and finally the segment IV duct are filled and delineated. When the intrahepatic ducts are small, magnification is needed for better delineation. Counterclockwise rotation of the X-ray tube may be needed for better delineation of the biliary tract anatomy (Figures 7.5 and 7.6). Not infrequently, the cystic duct is low in insertion into the common bile duct and the bulldog vascular clamp prevents common hepatic duct opacification. In this situation, the bulldog clamp is removed and the donor is placed in the Trendelenburg position. Even with this position, the segment IV duct may not be filled by contrast. If needed, the lower end of the common bile duct or the duodenum is compressed by fingers (protected by lead gloves) during instillation of radiographic contrast. An alternative is to use the balloon type of cholangiography catheter, which is more expensive and larger (Fr 6).

On the cholangiogram, attention is focused on the anomaly of biliary anatomy. Occasionally, the right anterior or posterior sectoral duct joins the LHD near the umbilical fissure.[1,2] It must be protected. The site where the segment IV hepatic duct joins the biliary tract is variable. It may be at the umbilical fissure, LHD or occasionally the confluence or the common hepatic duct.[2] Early recognition will facilitate identification during the hilum dissection or liver transection.

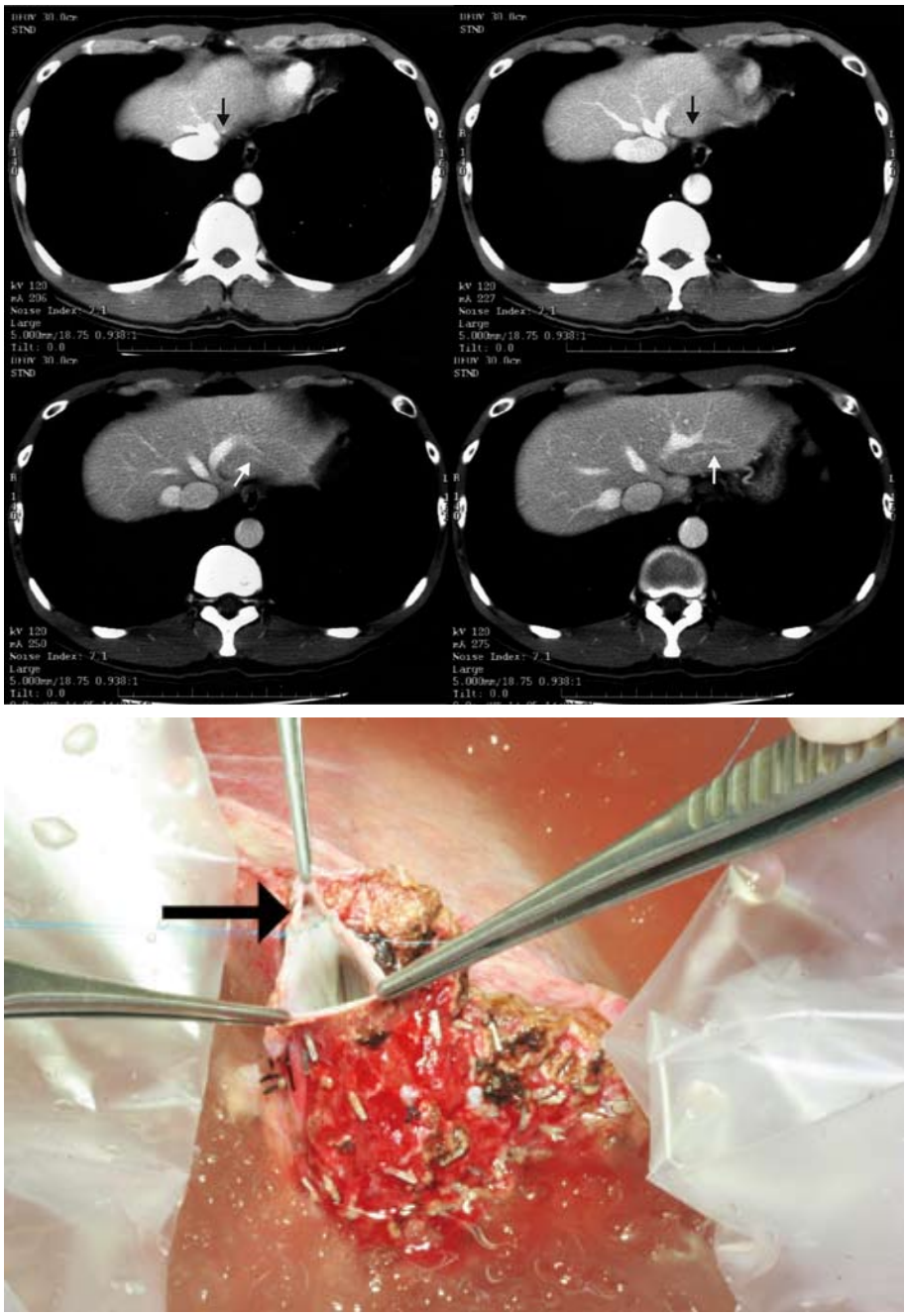

Figure 3.3A,B. Computed tomography scan of a donor shows a large left hepatic vein. Careful inspection revealed a small but significant segment II hepatic vein branch (arrow). The size of this branch could be appreciated in Figure 3.3B. It must be protected in the donor operation **(A)**; The segment II hepatic vein branch (arrow) was superficial and separate from the main trunk of the left hepatic vein at the cut surface. Venoplasty was performed to incorporate the segment II hepatic vein into a single orifice **(B)**.

Once the position of the LHD division is decided, the liver capsule above the site is marked by diathermy. It will be the lower end of the liver transection line (Figure 3.6).

Hilar dissection is then performed to expose the LHA. Care is exercised to avoid crushing the hepatic artery. Therefore, the LHA should never be picked up by the dissecting forceps. Application of electrocautery near to the hepatic artery should be cautious and minimal, and ligation of tissue should be performed as far as possible. The LHA should be freed to the junction with the main trunk. The tissue around the LHA near the umbilical fissure should not be removed in order to protect the blood supply to the LHD (Figure 3.7). The left portal vein (LPV) is then freed until the junction with the right portal vein (RPV) and main portal vein (MPV) is clearly identified. Small caudate branches coming off from the junction of the RPV and LPV should be divided and ligated to obtain sufficient length of the LPV for implantation. Similarly, the caudate branches coming off the left side of the LPV should also be ligated and divided (Figure 3.8). Ligation of the caudate branches must be performed meticulously. Since the caudate branches are located at the back of the portal vein, the ligatures may inadvertently narrow the lumen of the portal vein. Sometimes, the ligature may slip leading to major bleeding or slow oozing and hematoma compressing onto the RPV. Additional suture may be needed to secure the ligature.

The left lateral sector is then detached from the undersurface of the diaphragm by dividing the left triangular ligament. The loose tissue overlying the suprahepatic IVC is divided to expose the common trunk of the LHV and middle hepatic vein (MHV) and its junction with the IVC. The junction of the MHV and LHV is usually obvious. This point will be the upper end of the liver transection plane. The lesser omentum is then palpated for presence of





Figure 3.4. An atraumatic bulldog vascular clamp currently used by us for occluding the supraduodenal portion of the common hepatic duct.



Figure 3.5. Cholangiogram shows complete filling of the intrahepatic duct aided by cross-clamping of the common bile duct by the atraumatic vascular bulldog clamp (long arrow). The segment IV duct was filled by contrast (double arrows). A large-size Liga clip had been placed to mark the proposed site of division of the left hepatic duct (△).

the aberrant LHA and then divided if such artery is absent. The segments II and III are lifted to expose the fissure for the ductus venosum. At its junction with the IVC, the ductus venosum is encircled, ligated and divided. The liver capsule just underneath the fissure for ductus venosum is removed with an ultrasonic dissector (Cavitron Ultrasonic Surgical Aspirator, CUSA, Valley Lab, Boulder, CO, USA) to facilitate subsequent liver transection (Figure 3.8). At this point of time, attempt to encircle the LHV should not be made as it may induce severe bleeding especially when the junction between the MHV and LHV is not extrahepatic.

Liver transection is performed after the line of division has been determined. The transection plane is normally at the right side of the falciform ligament for a segment II/III graft. Near the umbilical fissure, it is deviated to the right side to meet the proposed point of division of the LHD in order to avoid damage to the segment II and III pedicles. Thus, the segment IV pedicle will be encountered along the transection plane and individual branches of segment IV pedicles are divided and ligated as they are encountered.

Liver transection is performed with an ultrasonic dissector without inflow vascular occlusion. The ultrasonic dissector is set at the amplitude of 60% of maximum, irrigation with normal saline at about 4–6 mL/minute and suction power 20% of maximum. A handpiece with fine tip and electrocautery incorporated into it is preferred for precise dissection (Figure 3.9). Exposed structures less than 1 mm are coagulated, while larger structures are clipped, ligated or sutured. When the hilar plate is reached, a second cholangiogram is performed for confirmation of the site of the LHD division. The main purpose of such meticulous step is to ensure that a single duct orifice is obtained at the transection surface (Figure 3.10). Occasionally, the segment II and III duct confluence is very near to the right hepatic duct, or if the transection is made too close to the umbilical fissure, the segment II and III ducts may be divided separately. The probability of postoperative biliary complication is expected to be higher if there are two or more hepatic duct orifices. A good-quality cholangiogram would be helpful to define the exact point of LHD division to obtain a single hepatic duct orifice in the graft. The importance of cholangiography in preventing duct injury is illustrated in Figure 3.10F.

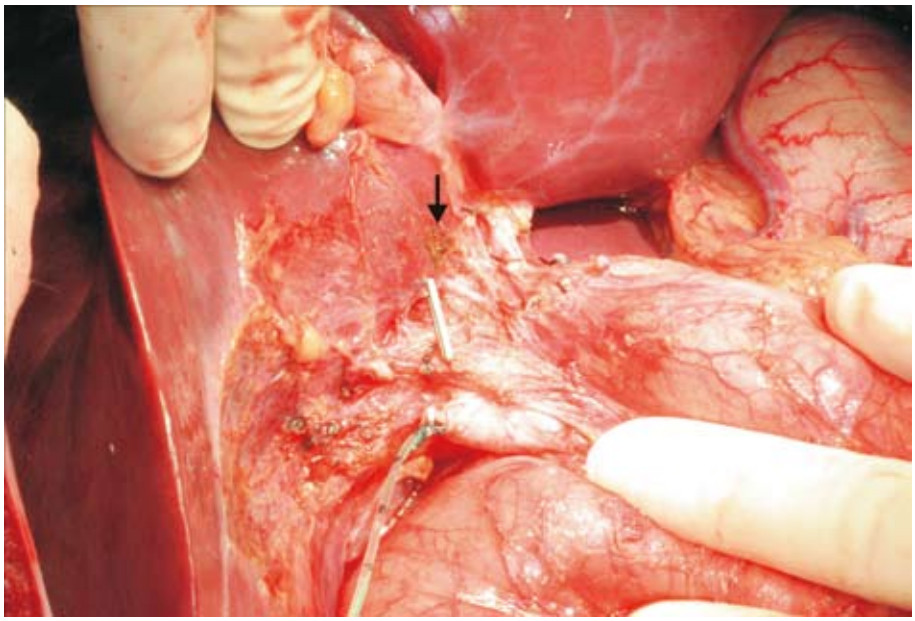

Figure 3.6. A diathermy mark (arrow) is made to locate the site of proposed division of the left hepatic duct. In this donor, the original clip was placed too near to the confluence of the hepatic ducts. The diathermy mark was then made to the left side of the clip.

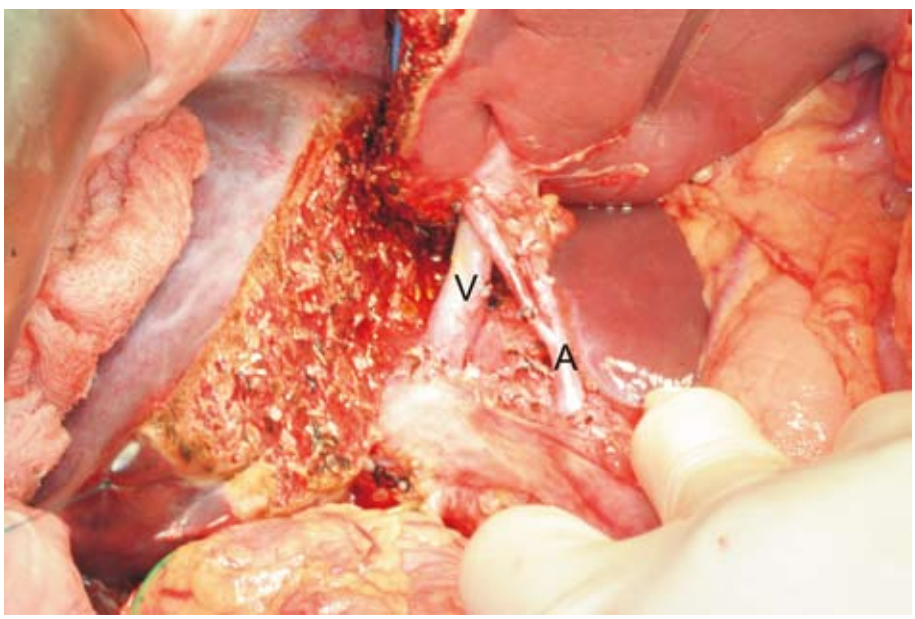

Figure 3.7. The left hepatic artery (A) and left portal vein (V) were freed. Tissue surrounding the left hepatic artery near to the umbilical fissure was not dissected to protect the blood supply to the left hepatic duct.

Once the point of LHD division is determined, the anterior wall of the LHD is divided with a pair of scissors or a knife. Brisk arterial or venous bleeding from the hilar plate and ductal wall is usual. The bleeders are controlled by 6-0 prolene sutures immediately as they are encountered before proceeding with further division to reduce blood loss and to provide a clear field. In the presence of brisk bleeding and unclear field, division of the LHD may be carried out in a hurry and may be inexact. The posterior wall of the left hepatic duct is then divided. The hilar plate is further divided before any hilar plate tissues are encircled and ligated. Ligation of the hilar plate too near to the duct orifice may sometimes narrow the lumen of the LHD and induce ischemia to the ductal wall. The ductal orifice on the common hepatic duct side is then sutured by 6-0 PDS. A third cholangiogram is performed to ascertain that the confluence of the hepatic ducts has not been occluded (Figure 3.10F). Occasionally, the segment IV duct joins the LHD near the confluence of the hepatic ducts. It may be mistaken to be the LHD because on dividing the duct it is cut open first. If in doubt, a fine catheter is inserted into the duct orifice and a cholangiogram obtained for verification (Figure 3.11).

After division of the LHD and the hilar plate, inspection is made for minute caudate bile duct orifices in the hilar plate, which must be plicated immediately to prevent bile leakage. The plane of liver division is then made toward the fissure for the ductus venosum. Lifting up the fissure by a right-angle forceps and displacing the segments II and III to the left will expedite the liver transection (Figure 3.12). However, the LHA must be protected before doing so. Forceful retraction and upward lifting may sometimes avulse the liver parenchyma. Therefore, this maneuver must be gentle. An alternative method is to have the assistant using his left thumb and index finger (Figure 3.13). The transection continues toward the cranial end until the junction of the MHV and LHV is seen. A large segment IV hepatic vein may drain into the LHV and have to be divided and sutured to provide

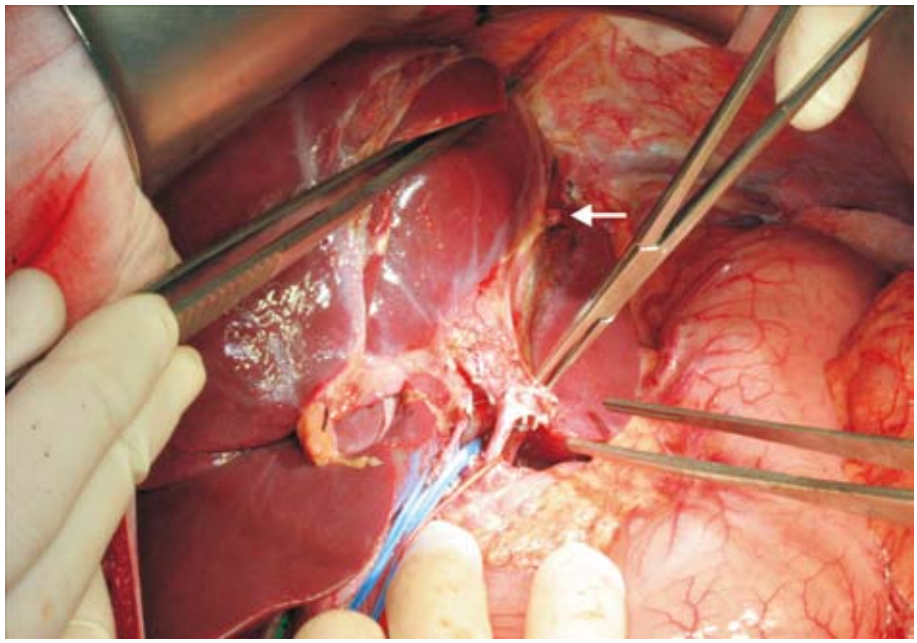

Figure 3.8. The branches of the left hepatic artery and portal vein going into the caudate lobe (pointed by the DeBakey forceps) were divided and ligated. The ductus venosum (arrow) was divided and the liver capsule beneath the ductus venosum was diathermized to facilitate subsequent liver transection.

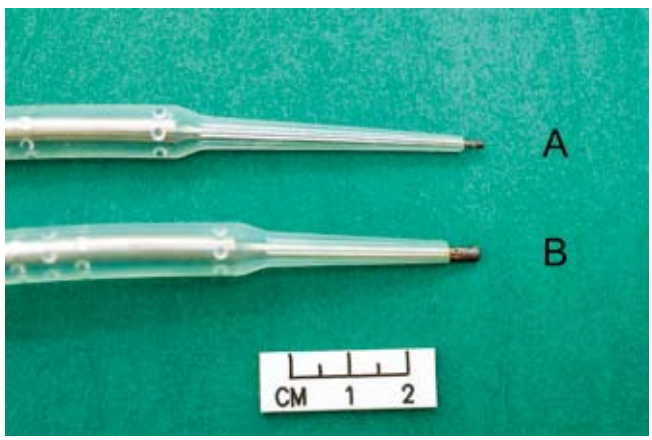

Figure 3.9. A fine tip (A) ultrasonic dissector is preferred for liver transection.

a sufficiently long LHV for subsequent implantation (Figure 3.14).

When the recipient requires a larger piece of liver graft, part of the segment IV is included and the liver transection plane is near the midplane of the liver. At the deeper part of the vertical liver transection plane, the MHV may be encountered (Figure 3.15). It must be exposed, preserved and followed until its junction with the LHV or IVC is seen. Once the MHV is seen, the liver transection plane is shifted from the vertical direction to the horizontal direction toward the fissure for the ductus venosum. Otherwise, the liver transection will go down into the segment I unnecessarily.

The retrieval of the segment II/III graft starts with clamping and dividing the LHA. Another vascular clamp is not applied on the graft side to avoid injury to the artery. The LHA stump is then ligated at this stage in order to reduce the number of instrument that may interfere with the graft retrieval later. The LPV is clamped vertically near to the junction with the main trunk. Care is exercised to leave a sufficient length of the portal vein above the clamp for subsequent suturing and to avoid occlusion of the bifurcation of the portal vein. A bulldog vascular clamp is then applied to the graft side and the LPV divided. The LHV is controlled by the vascular stapler [TA30, V3 (2.5 mm), United States Surgical, CT, USA] and divided on the liver graft side (Figure 3.1). The liver graft is then delivered to the basin containing ice sludge. The bulldog vascular clamp on the LPV is removed. A tube connected to histidine-tryptophan-ketoglutarate (HTK) solution (Dr. Franz Köhler, Chemie GmbH, Alsbach-Hähnlein, Germany) is inserted into the LPV. The tube position is secured by pinching in between the thumb and the index finger. Ligation of the LPV around the tube is not employed as it may damage the vein wall and shorten the vein available for anastomosis. About 1000 mL of HTK solution is used for complete flushing of the liver graft. The hepatic artery is then cannulated by a 23 G catheter for about 1 cm for flushing by HTK solution which is delivered by gravity. Again, the tube is secured in position by pinching or not at all if the lumen of the LHA is small. The bile duct is also rinsed by HTK solution. The graft is then transferred to a basin containing HTK solution. The hepatic vein orifice is then inspected for the necessity of venoplasty.[3] The hepatic vein orifice is pulled into a triangular shape (Figure 3.16). The horizontal axis is along the edge of segment II and the longitudinal axis is along the liver transection surface. The transverse and longitudinal axes are measured and the information relayed to

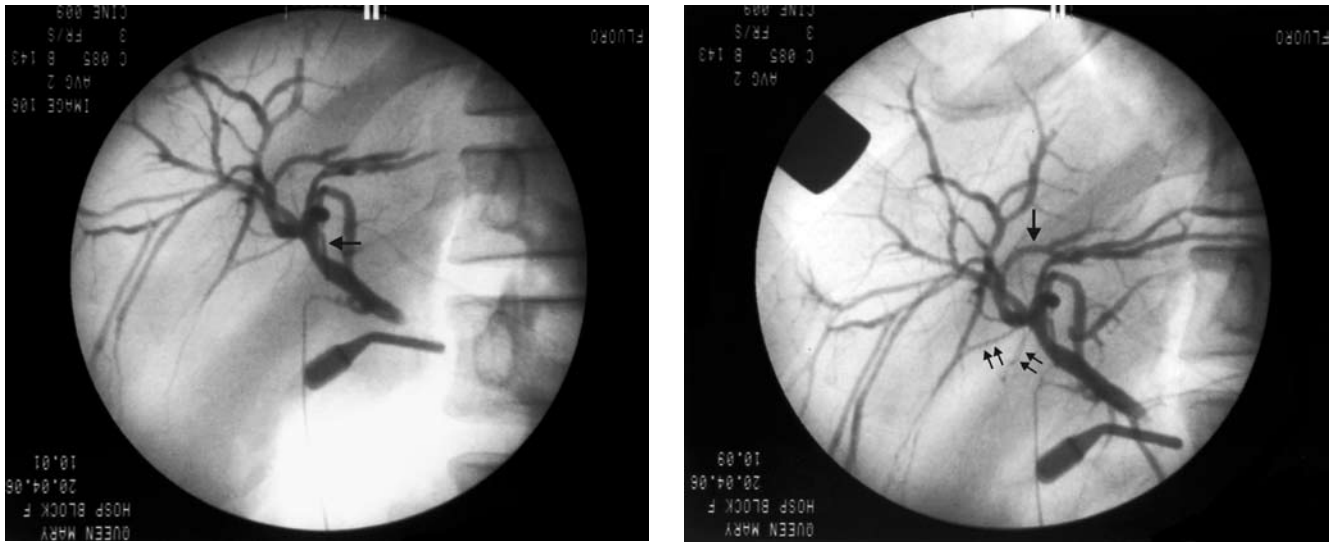

A **B**

Figure 3.10A,B. An operative cholangiogram was obtained in this segment II/III graft donor before hilar dissection and liver transection. At the liver hilum, the segmental hepatic ducts appeared to be crowded or overlapped with each other. The right and left hepatic ducts appeared not to exist. The large-size Liga clip (arrow) was also seen overlapping with the hepatic ducts **(A)**; Rotation of the X-ray tube counterclockwise did not produce a clearer picture of the ducts at the liver hilum. There was a hepatic duct crossing to the left (single arrow). It was initially interpreted to be a segment IV duct arising from the right ductal system. In retrospect, it was actually a segment VIII hepatic duct. It was more to the left side than usual because the segment IVb was very small, a fact discerned after liver transection because there was virtually no dusky liver to the right of the transection plane (falciform ligament). The segment IVa duct was identified in retrospect (double arrows). It joined near the confluence of the hepatic ducts and the orifice was seen as a pouch because of end-on projection **(B)**.

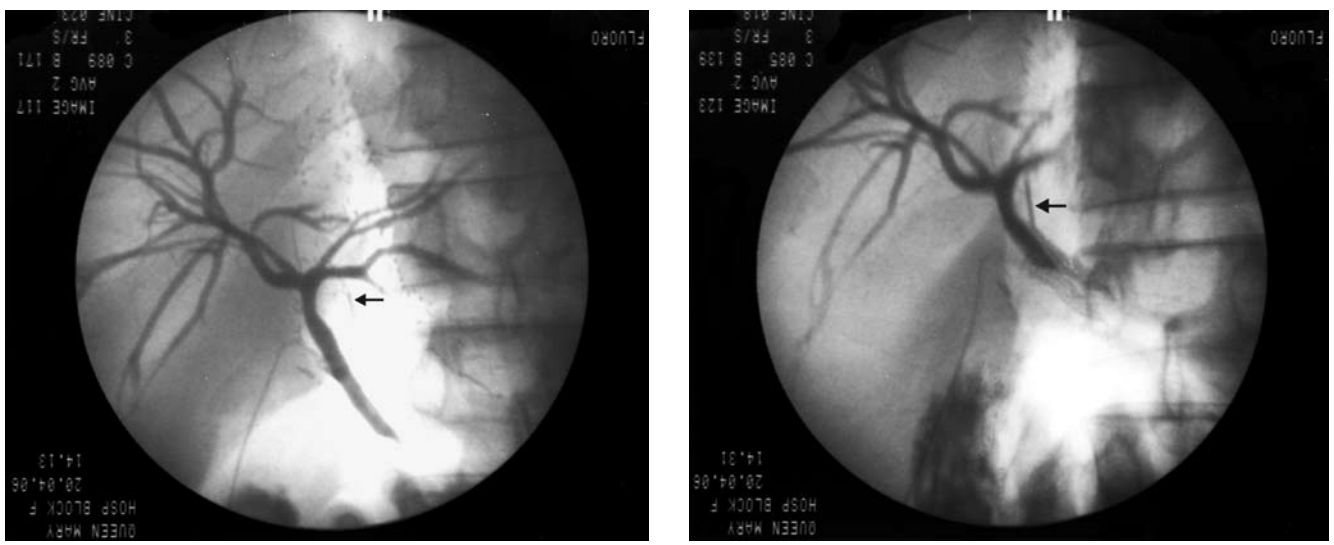

C **D**

Figure 3.10C,D. After liver transection and division of the segment IV pedicle, a second set of cholangiograms was performed. Without the segment IV duct, the right and left hepatic ducts were clearly delineated. The left hepatic duct was very short. The metal clip (arrow) was applied too far to the left **(C)**; The Liga clip (arrow) was repositioned. Again, it was not at the appropriate position **(D)**.

the recipient team. The graft is then weighed, stored in a sterile plastic bag, and immersed in an icebox.

In the donor, the LPV stump is sutured by 6-0 prolene. The vascular clamp on the LPV stump should not be removed before tying of knot is completed. Otherwise, tightening of the knot may cause purse-string narrowing of the portal vein. Dilute methylene blue is then injected into the common bile duct via the cystic duct cannula for checking of bile leakage. The likely sites of bile leakage are the LHD stump, the hilar plate, and the liver transection surface. If bile leakage is found, the site of leakage is closed meticulously by 6-0 PDS. The cystic duct cannula is removed and the cystic duct is tied below the level of the previous ligature by an absorbable material. Finally, thorough checking for bleeding

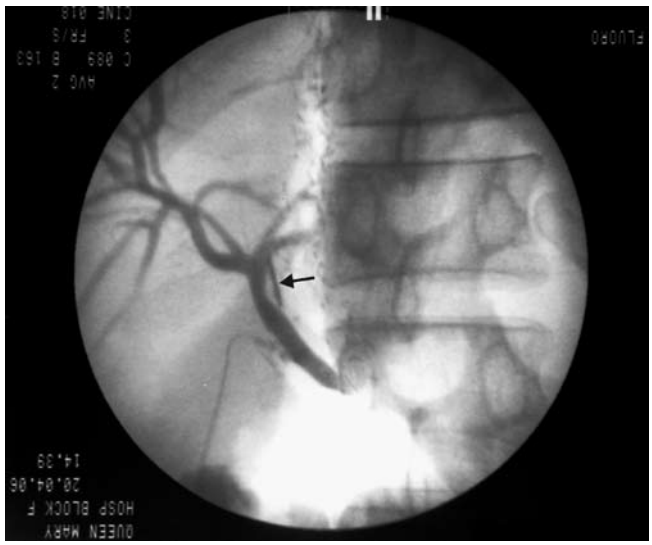

E

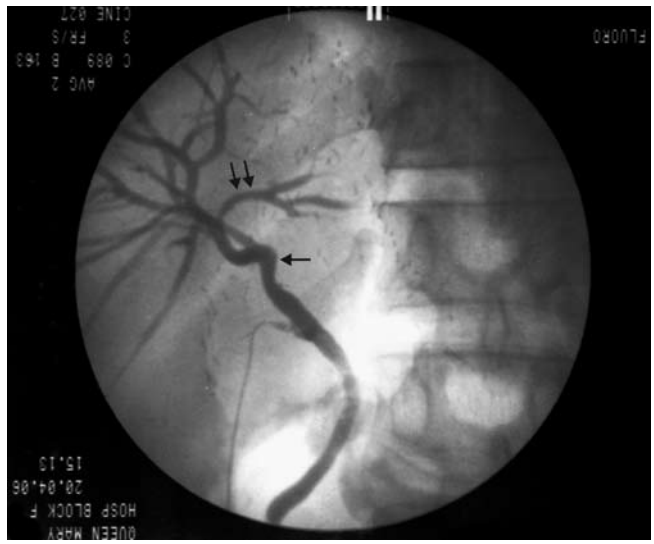

F

Figure 3.10E,F. Finally, this cholangiogram shows that the Liga clip (arrow) marked the correct or desirable position of the division of the left hepatic duct. Division at this point resulted in a single hepatic duct orifice at the transection plane **(E)**; A final cholangiogram after closure of the left hepatic duct stump (single arrow) showed that the right hepatic duct had not been narrowed. The segment VIII hepatic duct (double arrows) could be seen reaching the transection surface (marked by many small-sized Liga clips). Such an optimal result could only be achieved by meticulous cholangiography **(F)**.

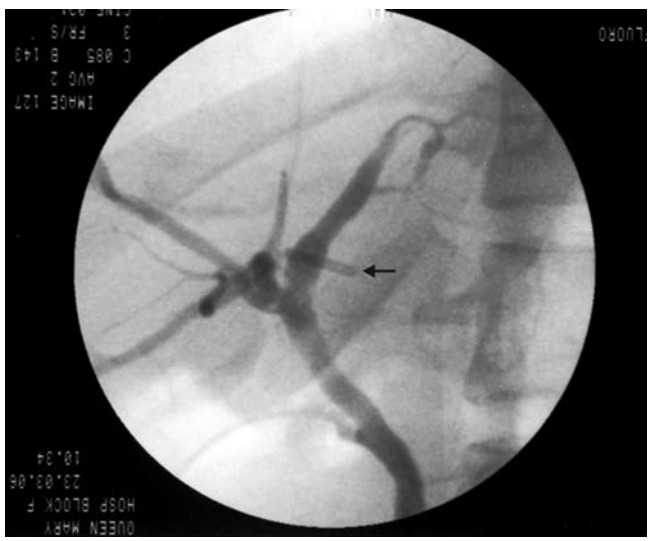

A

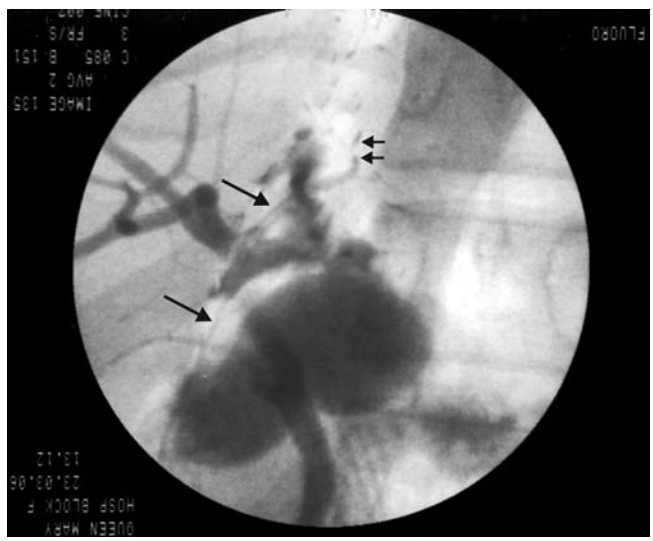

B



C

Figure 3.11A-C. Cholangiogram of a donor shows apparently normal left hepatic duct anatomy, but the segment IV duct was not well seen. At the time of left hepatic duct transection at the site marked by the Liga clip (arrow), two ductal openings were found at the cut surface **(A)**; Cholangiogram was obtained by inserting a cannula (long arrows) into one of the hepatic duct openings. There was no opacification of intrahepatic duct (double arrows). It was a segment IV duct that had been ligated at the transection surface **(B);** Cholangiogram was obtained by cannulating a second left hepatic duct opening. Opacification of the segment II/III ducts was obtained. It confirmed that the orifice was the correct one for implantation. The cholangiogram was not perfect in quality in that there was contrast extravasation. Nevertheless, it served the purpose well **(C)**.

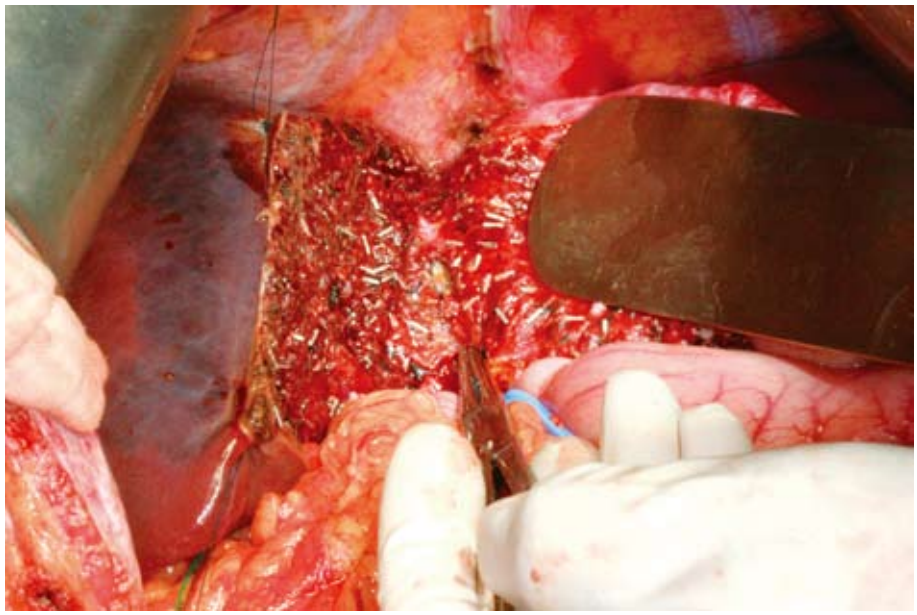

Figure 3.12. Segment II/III graft donor operation. The liver transection was approaching to the fissure for ductus venosum. Lifting up the fissure by a right-angle instrument and displacing the left side of the cut surface expedited the liver transection. Note that the segment IV was dusky.

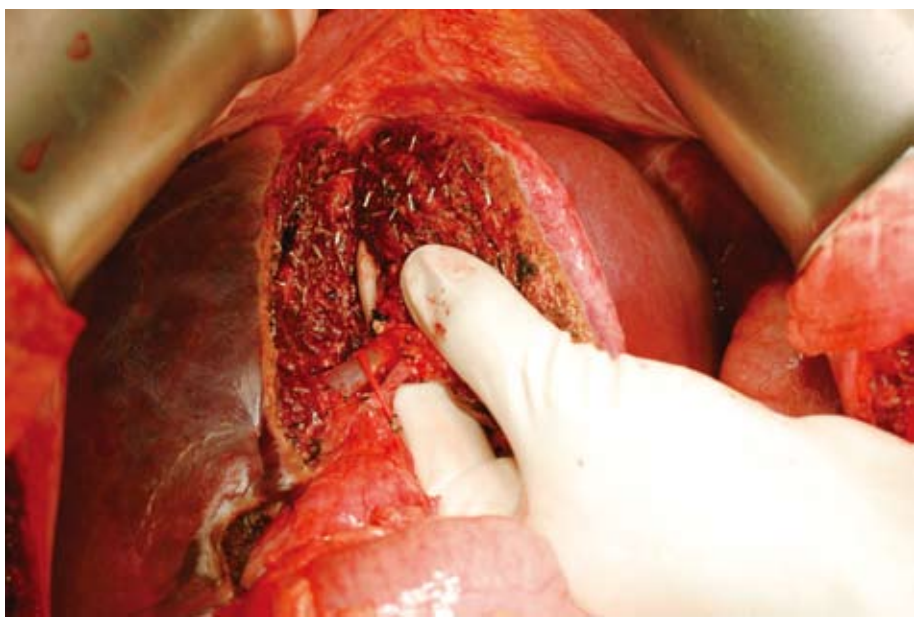

Figure 3.13. The left index finger of the assistant lifted up the fissure of the ductus venosum for guiding the liver transection. Caution must be exercised not to compress on the portal vein.



points is done. Then, the abdominal wound is closed without abdominal drainage.[4] Another dose of antibiotic is given to prevent wound infection.

In this operation, the vascular stapler is used on the LHV because it is more secure and slipping of the LHV from the vascular clamp has been observed. The latter situation is potentially fatal. How-

Figure 3.14. Computed tomography scan of a segment II/III donor. There was a prominent segment IVb hepatic vein (arrow) joining the left hepatic vein. The middle hepatic vein was also prominent. The segment IVb hepatic vein had to be sacrificed in order to obtain a sufficiently long left hepatic vein for implantation. The division of the left hepatic vein in this donor was performed proximal to its junction with the middle hepatic vein.

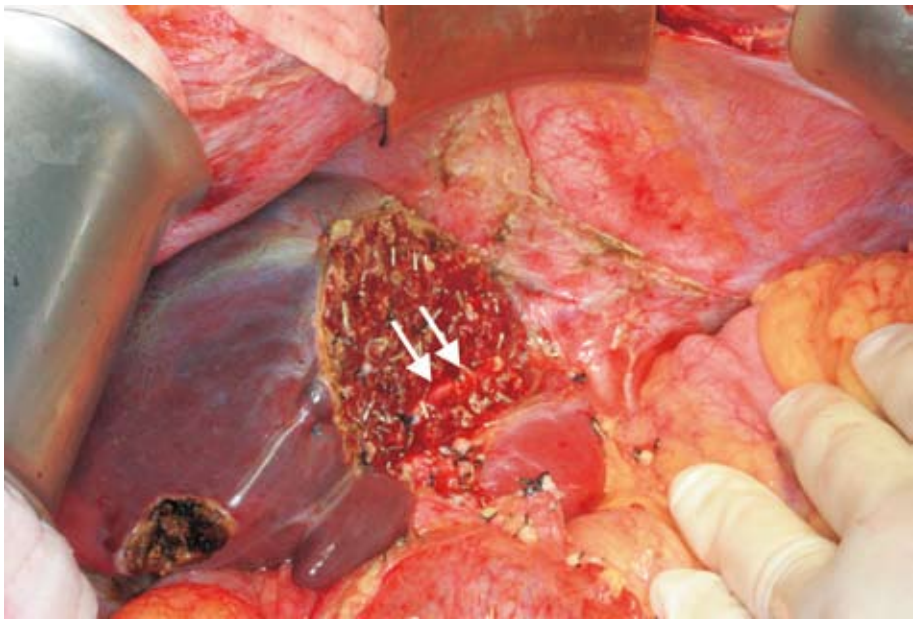

Figure 3.15. The middle hepatic vein (arrows) is encountered if the transection plane is vertical for a segment II/III graft including part of the segment IV. It must be exposed, protected and traced to the inferior vena cava.

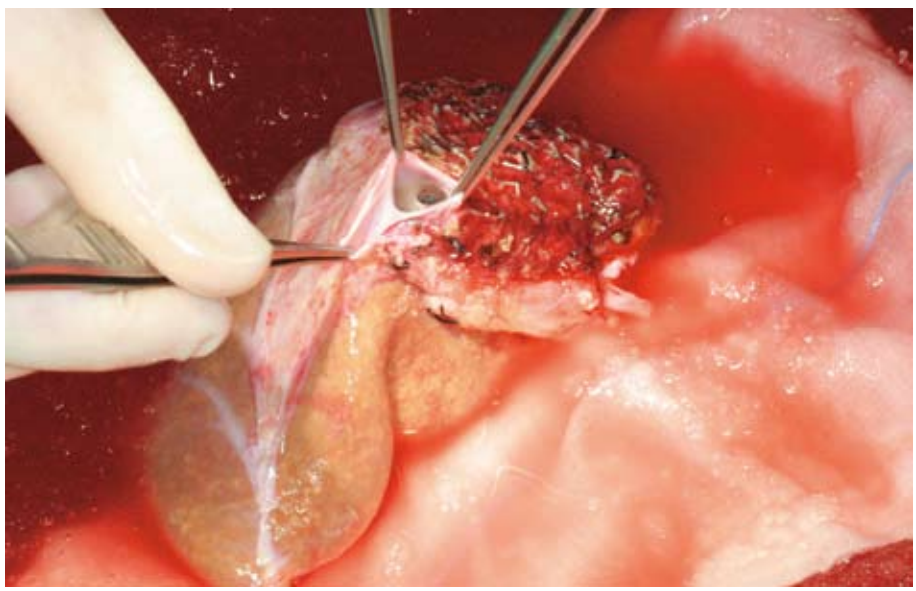

A

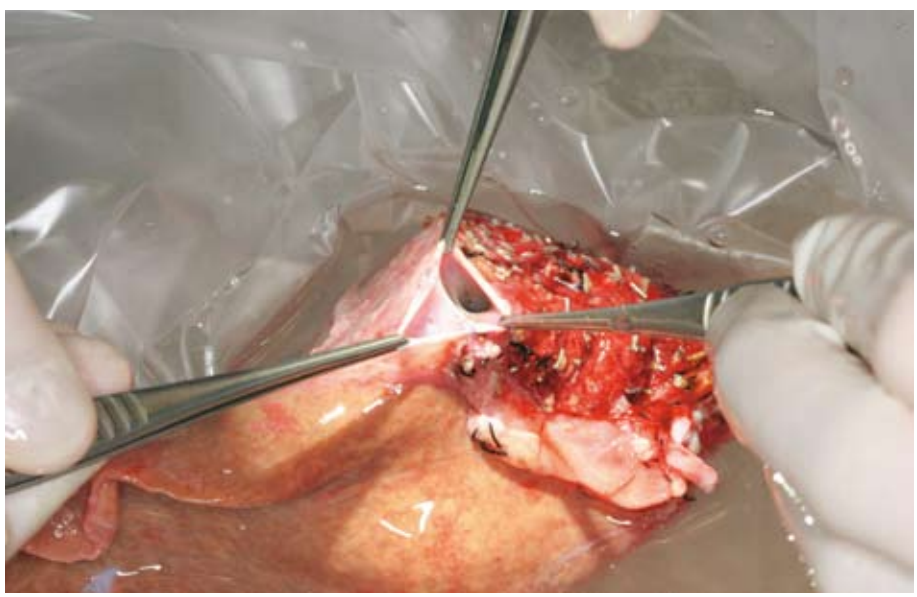

B

Figure 3.16A,B. Segment II/III graft. The segment II and III hepatic veins were examined in an ice-basin. To produce a better configuration for implantation, venoplasty was needed **(A)**; Venoplasty was completed. A large triangular orifice was formed **(B)**.

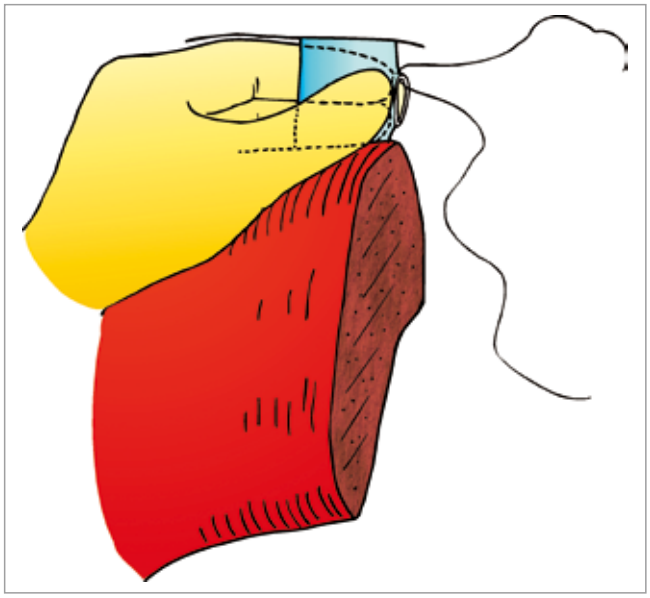

ever, minor bleeding may also occur in between staples. It happens when the liver tissues at the back of the LHV have not been cleared or when Liga clips are present on the vein wall at the site of stapling. Thus, small venous branches near to the root of the LHV are preferably sutured or ligated rather than clipped during dissection. Another potential problem of the vascular stapler is that the blade of the stapler is about 4 mm thick. After stapling, the length of the LHV in the liver graft available for anastomosis is reduced. This is not a serious problem because the length of the hepatic vein required for anastomosis needs not be long. Rather, redun-

Figure 3.17. Schematic diagram shows the technique of occlusion of the left hepatic vein orifice with the left index finger and thumb of the surgeon and application of suturing.

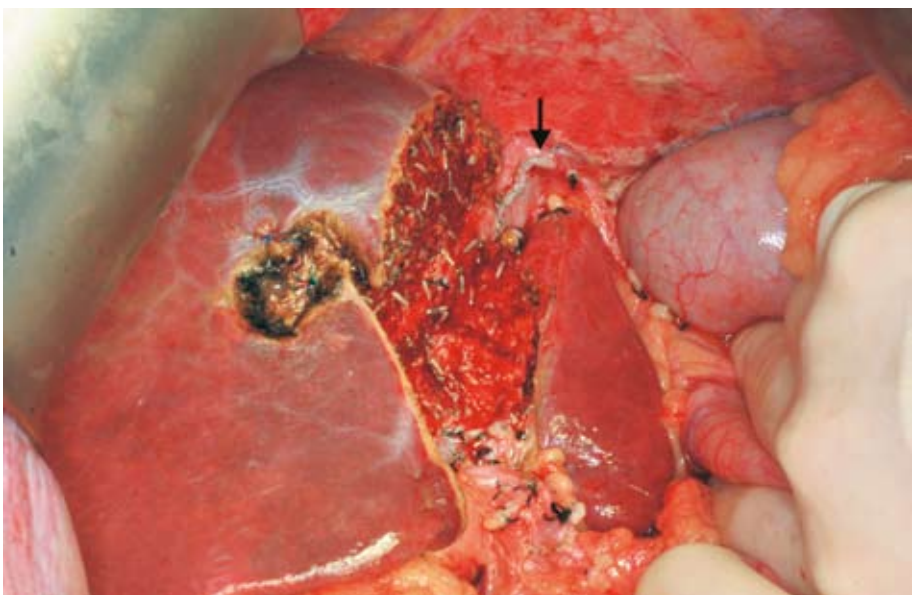

Figure 3.18. Segment II/III graft donor operation. After removal of the graft, segments IV and I were dusky. This donor had a tiny nodule in the segment IV, which was excised. The frozen section shows that it was focal nodule hyperplasia. This figure also shows the staple line of the left hepatic vein (arrow).

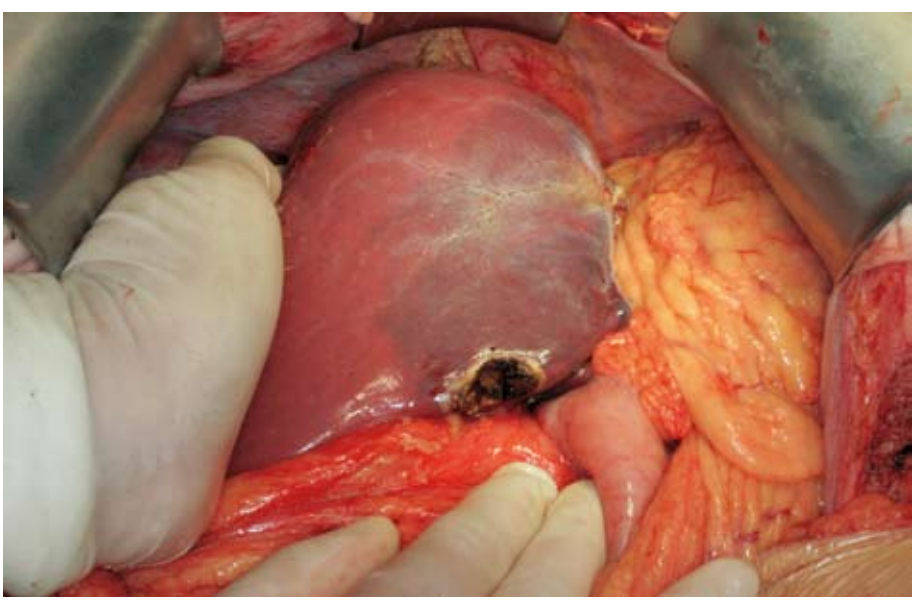

Figure 3.19. The segment IV was dusky after liver transection and was not resected. The donor was well after the operation. This part of the liver would undergo atrophy gradually.

dancy of the hepatic vein is a threat to the normal venous return of the liver graft.

If a vascular clamp has been used and slippage of the LHV stump is impending, it is preferred to apply running suture on the vein around the clamp. Then the vascular clamp is removed while the suture is pulled tight. In case of complete slippage and massive bleeding, the hepatic vein orifice must be occluded immediately with the right index finger, while the suprahepatic IVC is encircled with the left index finger (Figure 3.17). Using the left index and middle fingers and thumb occlusion, the LHV orifice could be occluded almost completely, the bleeding rate is much reduced and the hepatic vein orifice is seen clearly, allowing accurate application of sutures. Blind application of the vascular clamp or suturing may injure or occlude the IVC and MHV. In case of uncontrollable bleeding, total vascular occlusion must be employed promptly.

Occasionally, the portal vein slips underneath the vascular clamp during graft delivery. Application of another clamp beneath the original one is needed, but suturing of the vein orifice after application of the second vascular clamp is undesirable because it is likely that more portal vein wall than necessary might have been included above the clamp leading to narrowing of the portal vein after suturing. It is preferred to free and control the MPV and RPV, remove the clamp on the LPV stump, and suture the orifice transversely by fine and closely spaced stitches. In the presence of intact hepatic artery blood flow, the liver remnant will not suffer from serious ischemic injury.

Because of the ligation and division of the inflow vasculature, the segments I and IV may be dusky (Figures 3.13, 3.15, 3.18 and 3.19). It is arguable whether it is necessary to remove them. Proponents suggest that abscess formation may be devastating, but reports on such occurrence in LDLT are rare. Perhaps with intact venous drainage, the segments I and IV are still viable, being maintained by backflow from the hepatic vein. Therefore, resection of the segments I and IV is rarely necessary. These parts of the liver will undergo atrophy subsequently, but occasional case of bile leakage is observed.[5]

Recipient operation

Bilateral subcostal incision is made. For infants, upward midline extension is occasionally required. The usual indication for liver transplantation in pediatric patients is liver failure secondary to biliary atresia. Nearly all of them have undergone Kasai operation. Thus, adhesion of bowels to the wound is frequent and unrecognized injury to the bowel is the cause of postoperative bowel perforation and peritonitis. Careful dissection should be made and any suspicious perforation or serosal tear must be sutured immediately by fine prolene. The jejunal loop is then traced toward the liver hilum and freed as much as possible. Before the division of the jejunal loop by stapler, it is necessary to ensure that only the minimum length of small bowel is sacrificed as re-doing jejunojejunostomy for an exceedingly short Roux loop unnecessarily prolongs the operation, contaminates the peritoneal cavity and reduces the length of small bowel available for food absorption. After division, the part of bowel connecting to the liver hilum is necrotic and

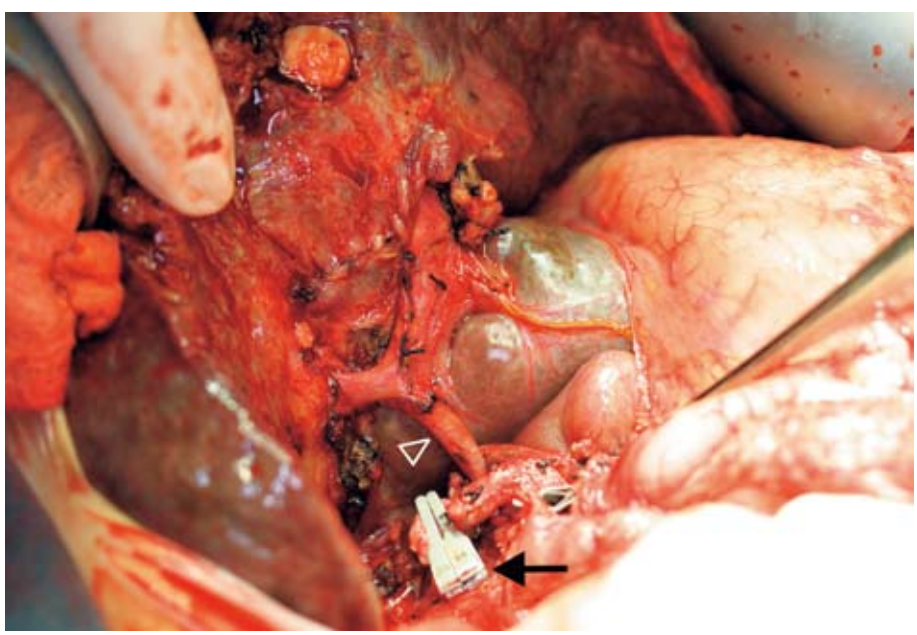

Figure 3.20. The portal vein (▷) and its two branches were dissected free. The main portal vein was small in size. The caudate lobe was hypertrophic. The hepatic artery branches were controlled by the AcLand microvascular clamp rather than by ligation (arrow).

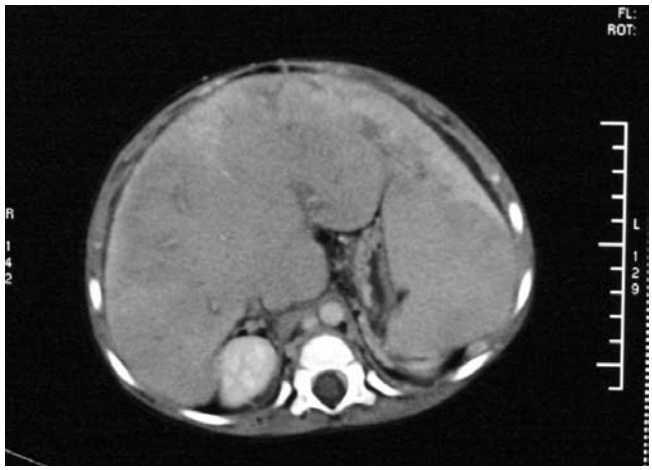

A



B

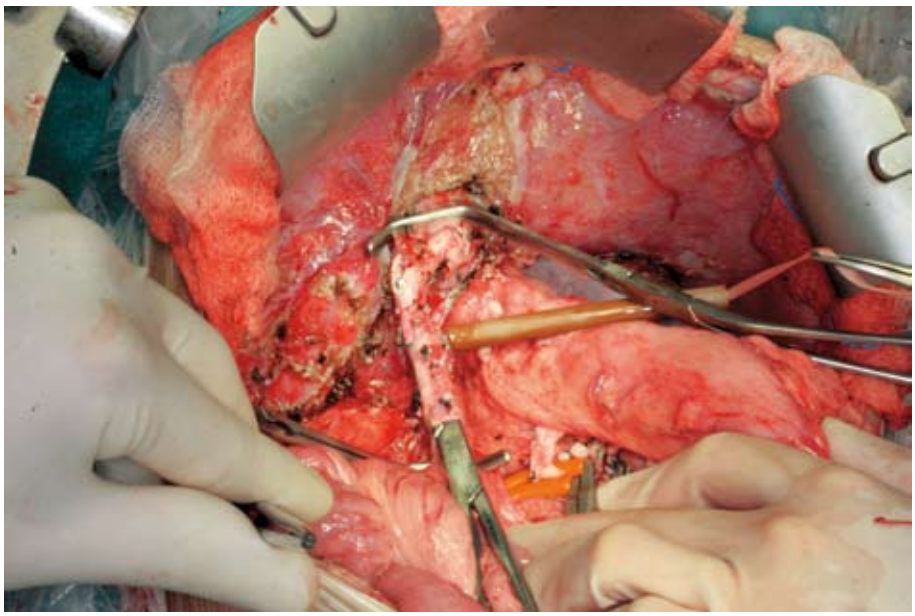

C

Figure 3.21A-C. A patient with biliary atresia. The caudate was enlarged causing inferior vena cava occlusion and thrombosis **(A)**; Computed tomography scan of the same patient in Figure 3.21A. The tortuous vascular structure (arrow) might be collateral or partially thrombosed and distorted inferior vena cava **(B)**; The inferior vena cava was opened and recannalized by passing the forceps. Recannalization was successful in this case. A Rummel tourniquet had been placed in preparation for control of the infrahepatic inferior vena cava **(C)**.

intestinal content may leak through the staples. This is undesirable as the operative field is contaminated and could be the cause of high fever during the operation. To avoid such happening, if the hilar exposure is adequate and dissection is not too difficult, the division of bowel is left to the last stage before the liver is removed.

The branches of hepatic artery are freed. They are controlled by AcLand microvascular clamps (S&T AG, Neuhausen, Switzerland) and the distal side is clamped and divided with a knife or scissors (Figure 3.20). Ligating the artery should not be done because it may crush the artery leading to intimal dissection or shortening of the length of the artery available for anastomosis. The portal vein is then identified and dissected down to the level of the pancreas and up till the right and left branches are seen. Tiny caudate branches of the portal vein have to be divided for isolation of the two branches of the portal vein. The portal vein is not divided until the liver graft is available because too early division will cause bowel congestion, making subsequent steps of the operation difficult.

The liver is then mobilized by dividing the triangular ligament on both sides. The infrahepatic IVC is mobilized and encircled. The caudate lobe of the liver is then separated from the IVC. The dissection is easier if the plane is kept close to the IVC. Otherwise, the liver capsule is entered and bleeding induced. However, dissection could be difficult when adhesion is dense secondary to recurrent cholangitis. Division of the portal vein will facilitate dissection of the liver from the IVC, but it is best left to the stage when the graft is available. Sizeable hepatic veins in between the IVC and caudate lobe are transfixed or sutured to avoid slippage of liga-

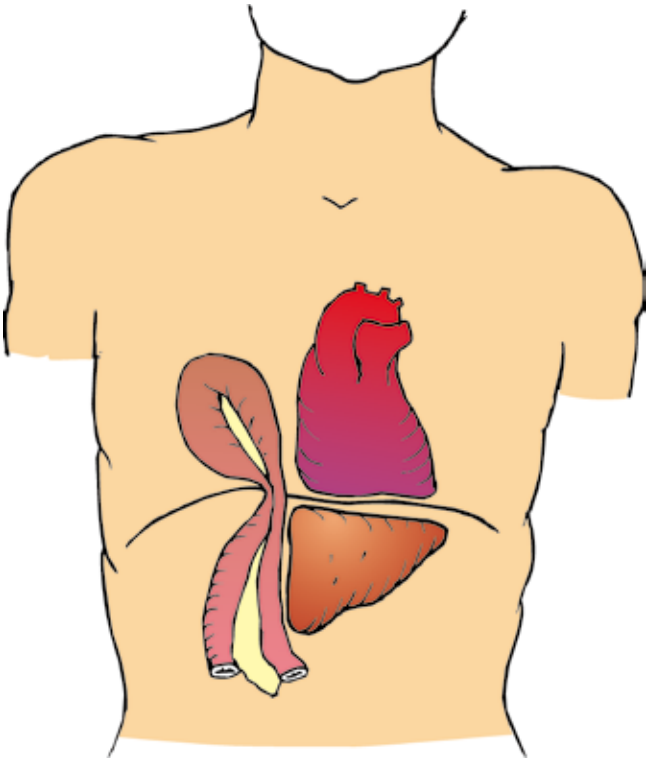

Figure 3.22. Herniation of the small bowel through the gap between the inferior vena cava and diaphragm. This was encountered in one of our patients.

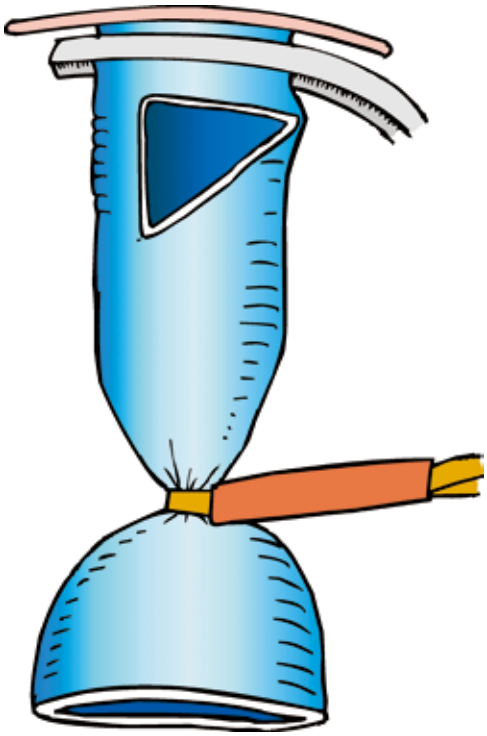

Figure 3.24. Schematic diagram shows the triangular inferior vena cava opening made by transverse and then longitudinal division of the anterior wall of the inferior vena cava.

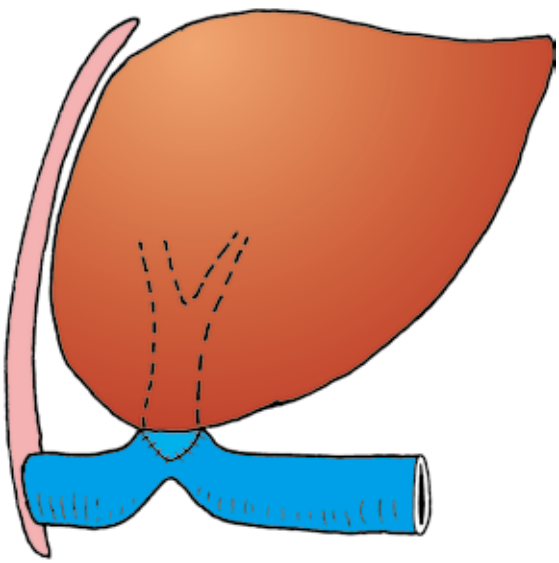

Figure 3.23. Kinking of the inferior vena cava if the right hepatic vein orifice is used for anastomoses.

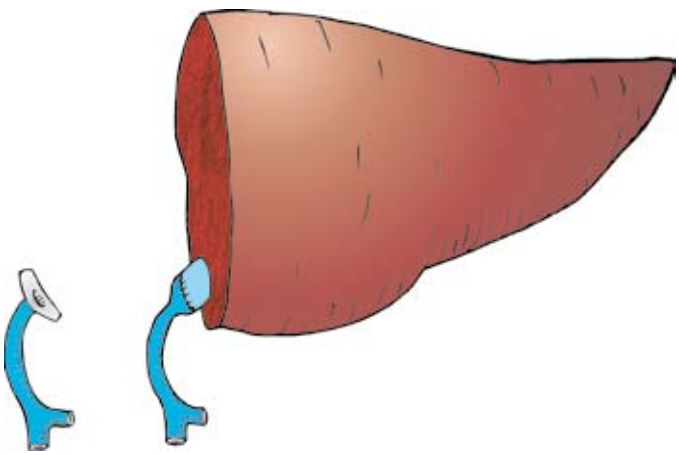

Figure 3.25. Schematic diagram showing opening of the right and left portal vein to form a cuff for subsequent anastomosis.

ture. The adrenal gland may be adherent to the liver and require careful sharp dissection. The right IVC ligament is then encircled and sutured after division. The IVC ligament may contain a hepatic vein and could be a source of postoperative bleeding if it has not been sutured properly. After division of the IVC ligament, the right hepatic vein (RHV) will be exposed. The RHV is encircled but not divided until the stage of hepatectomy. Then the caudate lobe is detached from the IVC by dividing many tiny hepatic veins. Attention is then turned to the left side of the IVC. An IVC ligament on the left side may

be present and dealt with in a similar manner as the right side. Sometimes the ligament is composed of liver tissue and surrounds the IVC on all sides. It should be divided between clamps cautiously to avoid avulsion injury to the IVC. The ductus venosum at the junction with the IVC is divided. Then the space between the IVC and LHV becomes obvious. The common trunk of the MHV and LHV is then encircled. Difficulty may be encountered at this stage of dissection especially when the caudate lobe is large (Figure 3.21). The dissection may be deferred until the liver graft is available and be made easier by dividing the portal vein. Dissection at the back of the caudate lobe is also made easier by dividing the RHV. To prevent congestion of the liver before the liver graft is available, the RPV has to be ligated. However, too early and prolonged clamping of the portal vein or its right branch may induce portal vein thrombosis because the portal vein is small and blood flow is sluggish. Therefore, in case of difficulty, it is better to withhold dissection at the back of the liver until the liver graft is ready.

When the liver graft is available, total hepatectomy is performed by dividing the RPV, LPV, RHV, and the common trunk of the LHV and MHV. The IVC is further mobilized from the retroperitoneum. One or two phrenic veins may have to be ligated and divided to allow a longer suprahepatic IVC obtained for safe application of the vascular clamp. The phrenic veins can be safely ligated because there are collaterals between the phrenic vein and the left renal vein. Too much dissection in between the IVC and diaphragm must not be done as weakening in this area may lead to

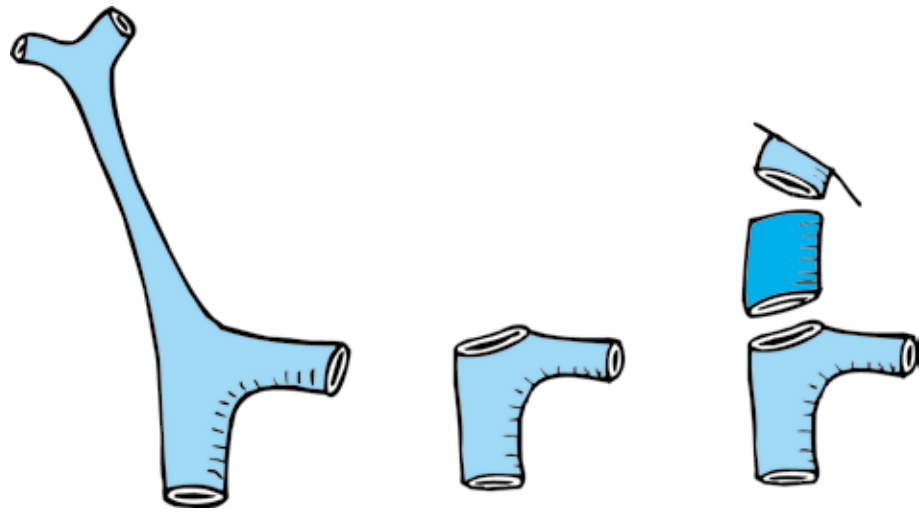

Figure 3.26. Modification of techniques for atretic portal vein in a biliary atresia patient.[7]

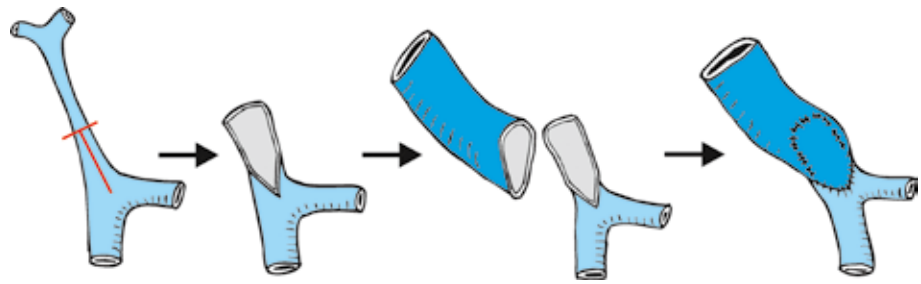

Figure 3.27. Modification of techniques for atretic portal vein in a biliary atresia patient.[8]

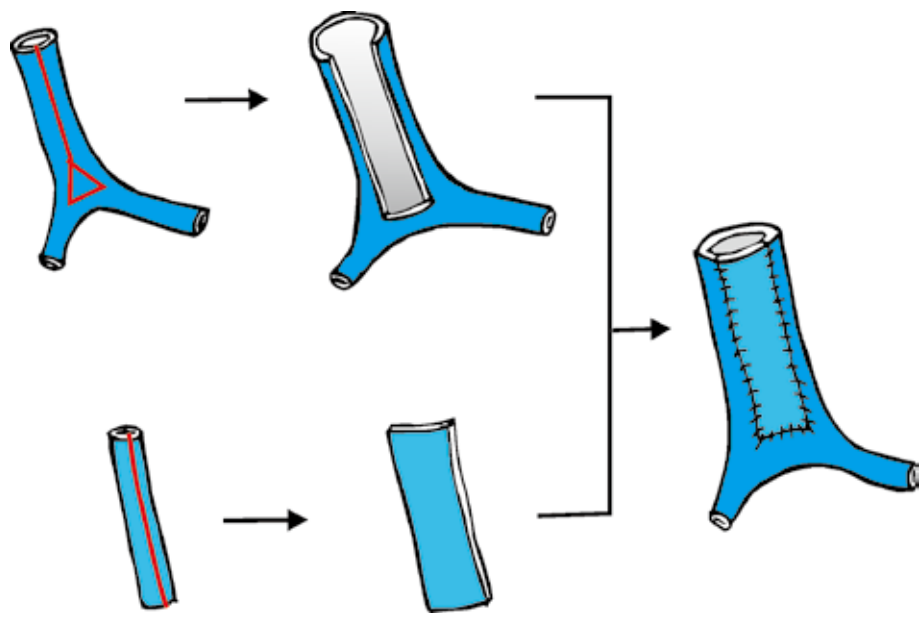

Figure 3.28. Modification of techniques for atretic portal vein in a biliary atresia patient.[9]

small bowel herniation[6] (Figure 3.22).

Hemostasis of the retroperitoneum and hepatoduodenal ligament is performed. The RHV stump is sutured. It is not used for anastomosis because it is lateral and posterior in position and kinking of the IVC may occur if it is used for anastomosis (Figure 3.23). The infrahepatic IVC is controlled by tape instead of a vascular clamp because it would allow more space for manipulation of the surgeon's right hand (Figure 3.21C). The suprahepatic IVC is then cross-clamped. The clamp controlling the MHV and LHV is removed and the septum between the two veins is divided. Cutting is then made transversely and then longitudinally into the IVC to form a large triangular orifice that matches in size with that of the liver graft (Figure 3.24). Hepatic vein anastomosis is then performed on the three sides of the triangle with 6-0 prolene running suture. For the inferior edge of the triangular opening, the liver graft is lifted up to expose the opening for the running suture placed from outside. A short growth factor is allowed during tying of the knot. The graft is then re-positioned for portal vein anastomosis. If the LPV of the graft is long, it is clamped by a bulldog vascular clamp and the IVC vascular clamp and tape are removed. Early release of the IVC control is beneficial for restoring retroperitoneal circulation and hemodynamics. The graft is now perfused by backflow from the IVC. Application of the vascular clamp on the graft LPV requires attention on the correct orientation. Otherwise, twisting of the portal vein may occur after anastomosis.

In the hepatic vein anastomosis, the common cuff of the MHV and LHV of the recipient has been used for anastomosis with the graft LHV. The operation may be rendered easy because the hepatic vein cuff is long and side clamping of the IVC would not interrupt the IVC flow. It was also suggested that the cuff orifice is large and matches the cuff of the LHV well. However, the orifice of the common cuff at the site of where it joins the IVC is actually smaller than that created by joining the MHV and LHV together. Moreover, redundancy is often present and renders outflow of the liver graft poor. Thus, such technical design is not to be recommended.

Portal vein anastomosis is the most difficult part of the implantation. Normally, the cuff of the portal vein after opening the junction of the RPV and LPV

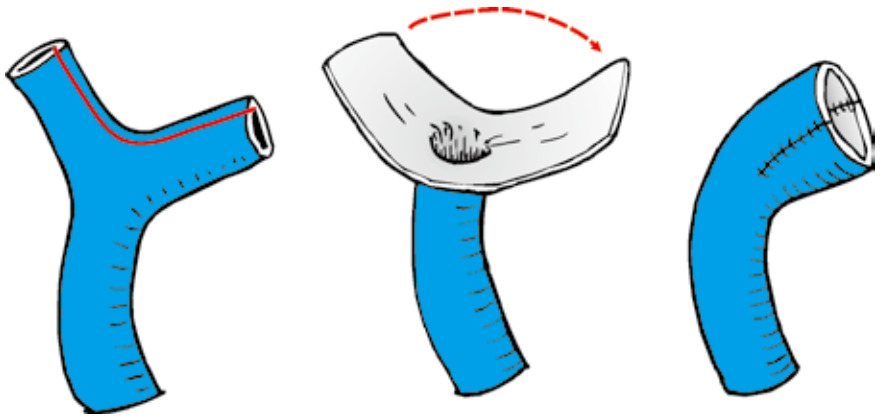

Figure 3.29. A technique to enlarge the portal vein opening in a biliary atresia patient.[10]

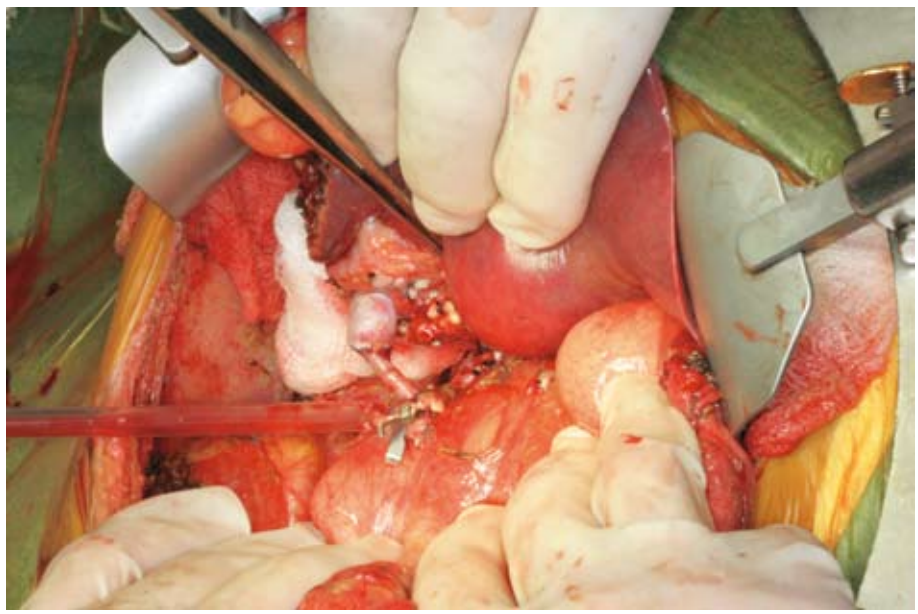

Figure 3.30. Segment II/III graft implantation. The recipient portal vein was narrow but the donor left portal vein was wide. Anastomosis was performed by the cuff of right and left portal veins of the recipient. The course of the portal vein appeared straight on lifting up the graft, but on putting down the graft, the portal vein was redundant and folded on itself. The graft must be pulled toward the left side to prevent kinking.

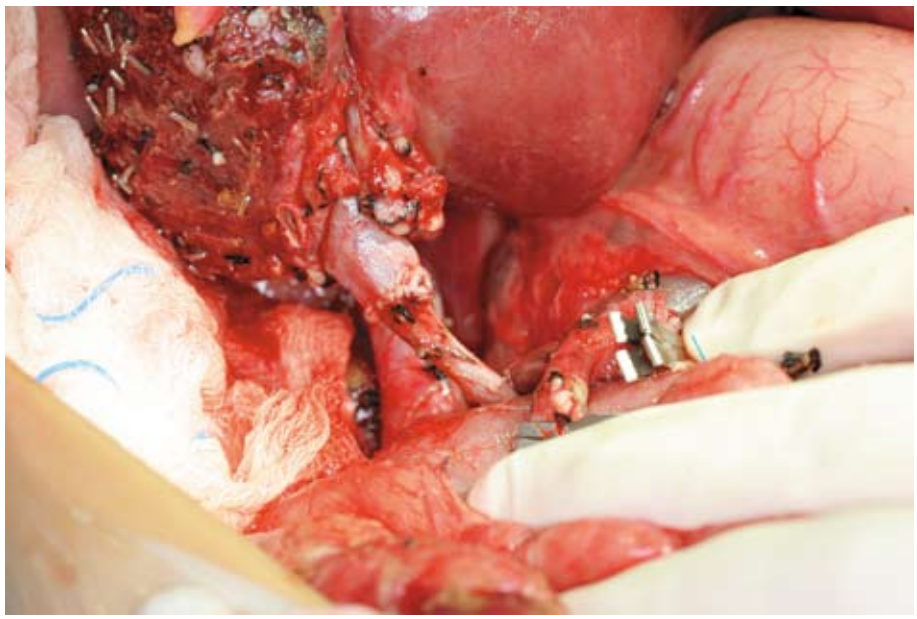

Figure 3.31. Another patient with a large-size main portal vein. The cuff of the right and left portal veins of the recipient was used for anastomosis. The resultant anastomosis appeared satisfactory.

is used for anastomosis (Figure 3.25). However, in a biliary atresia patient, the portal vein may be atretic and could not be used for anastomosis even though the cuff of the portal vein bifurcation is large. If the donor portal vein is long enough, anastomosis could be performed down to the level of the splenic vein, so that size mismatch can be avoided. However, during arterial anastomosis, lifting up the liver graft may stretch the portal vein, resulting in tearing or thrombosis. A venous graft conduit has been used[7,8] (Figures 3.26 and 3.27) to overcome the problem of portal vein atresia. Venous patch has also been used to enlarge the atretic portal vein[9] (Figure 3.28). A venoplasty technique has also been advocated by Tokyo University, Japan[10] (Figure 3.29).

When the MPV of the recipient is not atretic, the cuff of the RPV and LPV is used for anastomosis (Figure 3.25). Its size could match with the donor portal vein well but there is a risk of redundancy, leading to kinking and thrombosis (Figures 3.30 and 3.31). To correct the redundancy, the graft could be pulled to the left side. If the recipient MPV is about 6–8 mm wide, it may be possible to stretch it to match to the donor LPV, which may be 12–15 mm wide. In this situation, to avoid redundancy, the MPV of

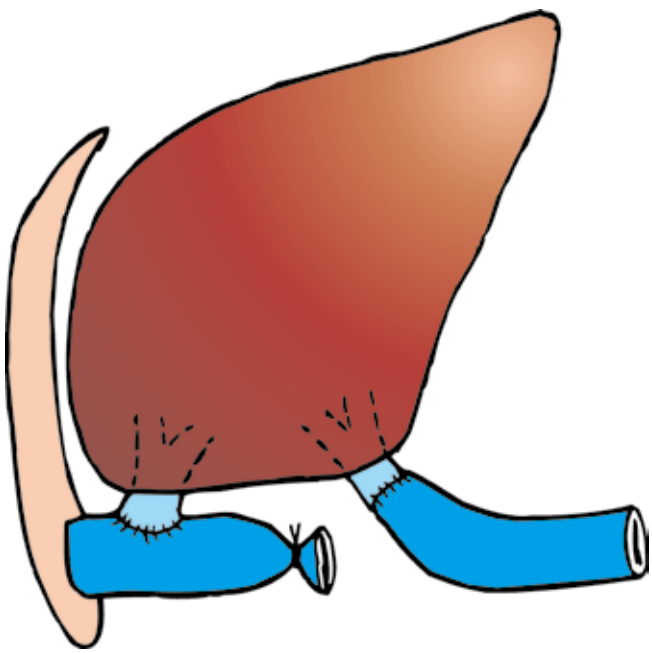

Figure 3.32. Schematic diagram shows the cavo-portal transposition.[11]

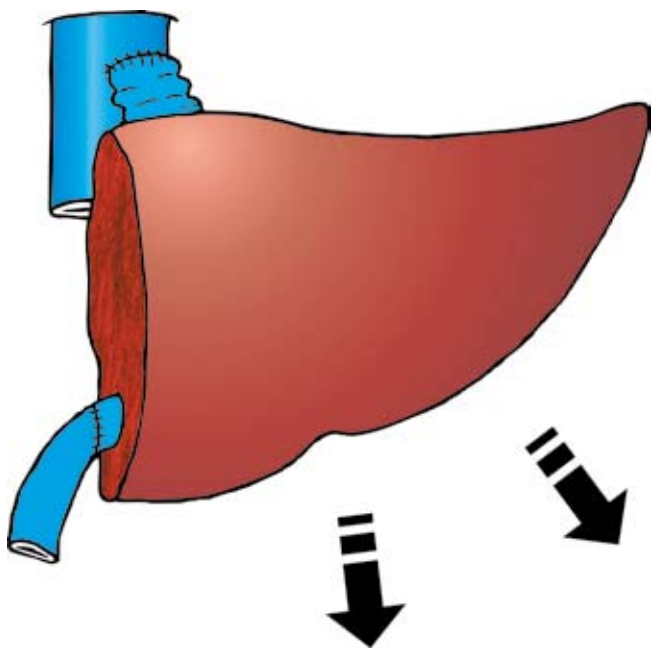

Figure 3.33. Schematic diagram shows redundancy of the left hepatic vein anastomosis. The graft was pulled to the left and caudally to correct the deficiency.

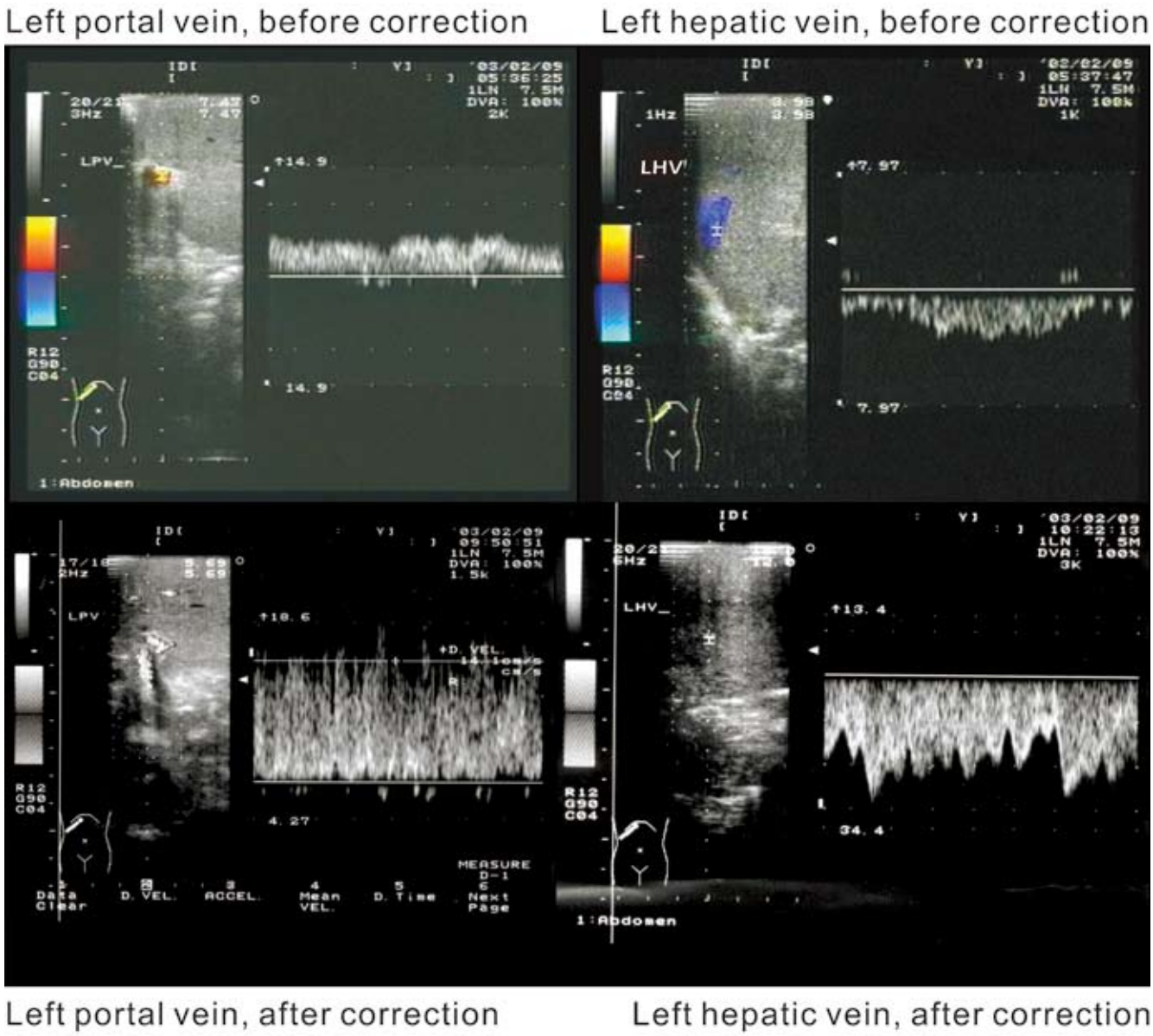

Figure 3.34. Left hepatic vein redundancy affected blood flow in the left hepatic vein as well as the left portal vein. Correction of the redundancy restored the blood flow and pulsatility pattern of the left hepatic vein and left portal vein.

the recipient could be used for anastomosis instead. However, the recipient portal vein wall may become thin on stretching and does not hold stitches well. A fine needle must be used in this circumstance.

The major risk of portal vein anastomosis is thrombosis. It is more likely when the portal vein blood flow is slow before implantation. Moreover, when the portal blood flow empties into the large donor LPV, there could be much turbulence within the umbilical portion of the LPV, leading to weakening of the pressure head flushing into the liver graft. The weakened blood flow may not be able to overcome the high central venous pressure, leading to poor and non-uniform perfusion of the liver graft. The problem is aggravated when the graft is relatively large in size. The central venous pressure must be reduced to improve graft perfusion. Sometimes, the reduced blood flow is due to the large coronary vein shunting away the portal blood. Ligation of the coronary vein has been used to increase the portal blood flow. However, before ligating the coronary vein, the graft hepatic vein must be examined carefully by Doppler ultrasonography. If there is obstruction in the outflow tract reconstruction, any portal blood flow manipulation is not fruitful.

In the event of portal vein thrombosis after repeated attempts of anastomoses, it is worthwhile to attempt the cavo-portal transposition[11,12] (Figure 3.32) or venoportal anastomosis.[13] The IVC is divided and the infrahepatic portion is anastomosed

end-to-end to the graft LPV. As the spontaneous shunt or retroperitoneal collaterals might have emptied into the IVC, the liver graft will not deprive important growth factors and nutrients. The major concern is that the blood flow in the IVC may be too high causing shear stress injury to the endothelium of the liver graft and the renal function may deteriorate due to congestion. We have tried cavo-portal transposition in one pediatric patient. The short-term outcome seemed satisfactory and both hepatic and renal functions recovered readily.

The hepatic artery anastomosis is performed by the microvascular technique. Normally, about 17 stitches of 9-0 nylon are required to secure water-tight anastomosis. During the procedure, attention must be paid to avoid compression of the LPV by a retractor. Over-stretching of the portal vein as a result of attempting to improve exposure of the liver hilum will also lead to portal vein thrombosis. Therefore, the costal arch must be lifted sufficiently by a self-retaining retractor to allow exposure of the liver hilum and to avoid compression injury to the liver graft by the costal arch. The graft should not be allowed to rotate into the right subphrenic cavity during the arterial anastomosis because twisting of the LHV and portal vein may occur.

Biliary reconstruction is performed by hepatico-jejunostomy. The diameter of the LHD is measured and an exact size opening is made on the jejunum, preferably by cutting current to avoid too much tissue coagulation. The anastomosis is accomplished by continuous 6-0 PDS running suture in the posterior layer and interrupted 6-0 PDS in the anterior layer. The use of the stent is controversial. In our practice, stent is not used but an internal-external stent splinting the anastomosis may be considered when the anastomosis is less than 2 mm in size.

In older children without biliary atresia, duct-to-duct anastomosis can be made.[14] In smaller children, due to the small size of the common bile duct, stenosis of the duct-to-duct anastomosis is highly likely.

Before wound closure, careful inspection is made for bowel perforation and serosal tear. All suspicious areas are sutured by 5-0 or 6-0 prolene. Doppler ultrasonography is again performed. Optimal blood flow within the portal and hepatic veins is ascertained and the most appropriate position of the liver graft is determined before the graft is fixed by stitching to the anterior abdominal wall. We have encountered a case with redundant hepatic vein and pulling the graft caudally and to the left was required to correct the hepatic vein redundancy and graft under-perfusion[15] (Figures 3.33 and 3.34).

Abdominal drain is not inserted, unless excessive abdominal fluid collection is expected, e.g. those with small-for-size graft or cavo-portal transposition.

Postoperative care

The donor is nursed in the intensive care unit on the first postoperative day. Attention should be paid to the oxygen saturation, hemodynamic stability and urine output. Urine output may be marginal in the early postoperative period, but it is dangerous to overload the circulation because impeded venous return of the liver remnant may result in liver congestion and impaired liver function. Adequate pain control and anti-emetic are needed to expedite recovery and to eliminate ill feeling of donation. Two more doses of antibiotic are given. H_2-receptor antagonist or proton pump inhibitor is continued for about 6 weeks postoperatively. One should not assume that the donor will recover quickly because only the segments II and III are lost. In effect, the loss is equivalent to the size of the left liver. Therefore, indices of liver function recovery, namely, base excess, international normalized ratio and serum bilirubin level, are closely monitored. Doppler ultrasonography is performed if the liver function is slow to return to normal or if there is suspicion of sepsis.

The recipient is ventilated mechanically. Fluid administration is cautious to avoid overloading the circulation. Antibiotic is continued for about 5 days, especially for those with preoperative sepsis. Our current immunosuppressive protocol for children consists of steroid, FK506 and interleukin-2 receptor antagonist.

Doppler ultrasonography is performed daily. In a high-risk case, more frequent ultrasonography is performed to detect early occurrence of hepatic artery or portal vein thrombosis. By this vigilant monitoring, liver grafts could be salvaged.[16]

Bowel perforation may occur, but it does not

manifest several days after the transplantation. Clinical manifestation is variable. Patient irritability is a consistent sign. Pyrexia may not be present. A sudden increase in the heart rate may signal the perforation. Abdominal distension due to ileus and ascites is frequently observed and abdominal X-ray may detect free gas, but sometimes only the computed tomography scan can detect the small amount of free gas in the abdominal cavity. Prompt laparotomy is needed to repair the perforation to prevent further deterioration.

Late development of ascites and abdominal distension may impair feeding. The usual strategy is to administer diuretic and albumin. However, if the ascites persists and renal function deteriorates, ultrasound-guided abdominal tapping is needed to decompress the abdomen, and, most importantly, to look for infection and chyle in ascites. Chylous ascites occurs not infrequently. In our impression, the incidence is not related to the extent of hilar dissection, amount of tissue ligation or coagulation. Once diagnosis is made, the child should have a fat-free diet for about 4–6 weeks to allow spontaneous closure of the lymphatics in the liver hilum or retroperitoneum.

References

1. Couinaud C. Surgical anatomy of the liver revisited. 1989. [ISBN 2-903672-01-6]
2. Ohkubo M, Nagino M, Kamiya J, Yuasa N, Oda K, Arai T, Nishio H, Nimura Y. Surgical anatomy of the bile ducts at the hepatic hilum as applied to living donor liver transplantation. Ann Surg 2004; 239: 82-86.
3. Kubota K, Makuuchi M, Takayama T, Harihara Y, Watanabe M, Sano K, Hasegawa K, Kawarasaki H. Successful hepatic vein reconstruction in 42 consecutive living related liver transplantations. Surgery 2000; 128: 48-53.
4. Liu CL, Fan ST, Lo CM, Chan SC, Yong BH, Wong J. Safety of donor right hepatectomy without abdominal drainage: a prospective evaluation in 100 consecutive liver donors. Liver Transpl 2005; 11: 314-319.
5. Hwang S, Lee SG, Lee YJ, Park KM, Ahn CS, Kim KH. Postoperative changes in remnant medial segment parenchyma of living donor livers after procurement of left lateral segment graft. Hepatogastroenterology 2006; 53: 773-777.
6. Okajima H, Hayashida S, Iwasaki H, Suda H, Takeichi T, Ueno M, Asonuma K, Inomata Y. Bowel obstruction due to diaphragmatic hernia in an elder child after pediatric liver transplantation. Pediatr Transplant 2007; 11: 324-326.
7. Tanaka K, Uemoto S, Tokunaga Y, Fujita S, Sano K, Nishizawa T, Sawada H, Shirahase I, Kim HJ, Yamaoka Y, et al. Surgical techniques and innovations in living related liver transplantation. Ann Surg 1993; 217: 82-91.
8. Mitchell A, John PR, Mayer DA, Mirza DF, Buckels JA, De Ville De Goyet J. Improved technique of portal vein reconstruction in pediatric liver transplant recipients with portal vein hypoplasia. Transplantation 2002; 73: 1244-1247.
9. Marwan IK, Fawzy AT, Egawa H, Inomata Y, Uemoto S, Asonuma K, Kiuchi T, Hayashi M, Fujita S, Ogura Y, Tanaka K. Innovative techniques for and results of portal vein reconstruction in living-related liver transplantation. Surgery 1999; 125: 265-270.
10. Harihara Y, Makuuchi M, Kawarasaki H, Takayama T, Kubota K, Hirata M, Kita Y, Kusaka K, Sano K, Hashizume K. Portal venoplasty for recipients in living-related liver transplantation. Transplantation 1999; 68: 1199-1200.
11. Tzakis AG, Kirkegaard P, Pinna AD, Jovine E, Misiakos EP, Maziotti A, Dodson F, Khan F, Nery J, Rasmussen A, Fung JJ, Demetris A, Ruiz PJ. Liver transplantation with cavoportal hemitransposition in the presence of diffuse portal vein thrombosis. Transplantation 1998; 65: 619-624.
12. Lipshutz GS, Patel S, Hiatt JR, Yersiz H, Farmer DG, McDiarmid SV, Ghobrial RM, Busuttil RW. Portocaval hemitransposition in pediatric liver transplant recipients: a single-center experience. Liver Transpl 2006; 12: 1097-1103.
13. Marubashi S, Dono K, Nagano H, Gotoh K, Takahashi H, Hashimoto K, Miyamoto A, Takeda Y, Umeshita K, Kato T, Monden M. Living-donor liver transplantation with renoportal anastomosis for patients with large spontaneous splenorenal shunts. Transplantation 2005; 80: 1671-1675.
14. Okajima H, Inomata Y, Asonuma K, Ueno M, Ishiko T, Takeichi T, Kodera A, Yoshimoto K, Ohya Y. Duct-to-duct biliary reconstruction in pediatric living donor liver transplantation. Pediatr Transplant 2005; 9: 531-533.
15. Lo CM, Liu CL, Fan ST. Correction of left hepatic vein redundancy in paediatric liver transplantation. Asian J Surg 2005; 28: 55-57.
16. Sakamoto Y, Harihara Y, Nakatsuka T, Kawarasaki H, Takayama T, Kubota K, Kimura W, Kita Y, Tanaka H, Ito M, Hashizume K, Makuuchi M. Rescue of liver grafts from hepatic artery occlusion in living-related liver transplantation. Br J Surg 1999; 86: 886-889.

4. Left liver graft
(including the caudate and the middle hepatic vein)

Donor operation

The donor is placed in a position to avoid pressure sores (ankle or occiput) and brachial plexus injury. Devices to prevent hypothermia and deep vein thrombosis are provided. Prophylactic antibiotic and H_2-receptor antagonist are given at the time of induction of general anesthesia. Bilateral subcostal incision with midline extension is made. An alternative is omission of the left subcostal incision, if the donor does not have a thick abdominal wall or deep abdominal cavity. Similar to the segment II/III graft operation, the upward extent of the midline extension should allow visualization of the suprahepatic inferior vena cava (IVC) vertically after application of the self-retaining retractor. Intraoperative ultrasonography is performed for documenting the blood flow of the hepatic artery and portal vein. The confluence pattern of the middle hepatic vein (MHV) and left hepatic vein (LHV) and its related segmental branches are also studied. The caudate lobe is included in the graft to increase the volume to meet the demand of an adult recipient.[1,2]

Cholecystectomy and cannulation of the cystic duct by a Fr 3.5 Argyle catheter are then performed. The supraduodenal part of the common bile duct is then isolated partially for application of a bulldog vascular clamp (Featherlight Bulldog Clamp, Geister, Inc, Tuttlingen, Germany) (Figure 3.4). Care is taken to avoid injuring the pancreas and the common bile duct lymph node. If dissection at this region is deemed difficult or unsafe, tilting the operating table head-down may produce a similar effect as occluding the common bile duct, though complete filling of all intrahepatic ducts may not be achieved. Gentle hilar dissection is then performed to expose the left hepatic duct (LHD). A large-size Liga clip (Ethicon Ltd, Edinburgh, UK) is then placed onto the liver capsule at the point of proposed division of the LHD. Operative cholangiography is then performed as described in the previous chapter. Once the site is determined, a mark is made on the liver capsule by diathermy.

Further dissection is then made to expose the left hepatic artery (LHA). The number of LHA should have been known before the operation and is verified during the dissection. Gentle dissection is made to avoid injury and spasm of the artery. Maximum length of the artery is obtained by dissection until the junction with the main trunk is seen, but the part near to the umbilical fissure should not be touched to avoid ischemic injury to the LHD. Next, the left portal vein (LPV) is freed until the junction with the main trunk is seen. Caudate branches near the

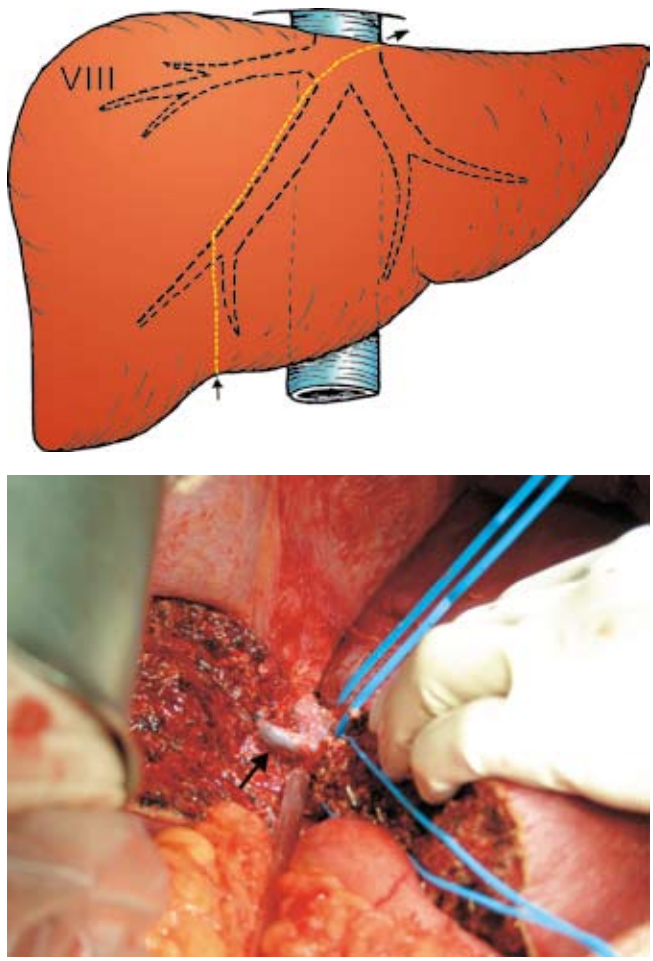

Figure 4.1A,B. The liver transection line on the anterior surface of the liver for the left liver graft. It starts at the tip of the gallbladder fossa and ends at the left hepatic vein junction with the inferior vena cava. The transection plane should be on the right side of the middle hepatic vein. A large segment VIII hepatic vein should be retained with the right liver, if possible **(A)**; In this donor, a large segment VIII hepatic vein (arrow) was preserved. The vessel loops were around the left and middle hepatic veins **(B)**.

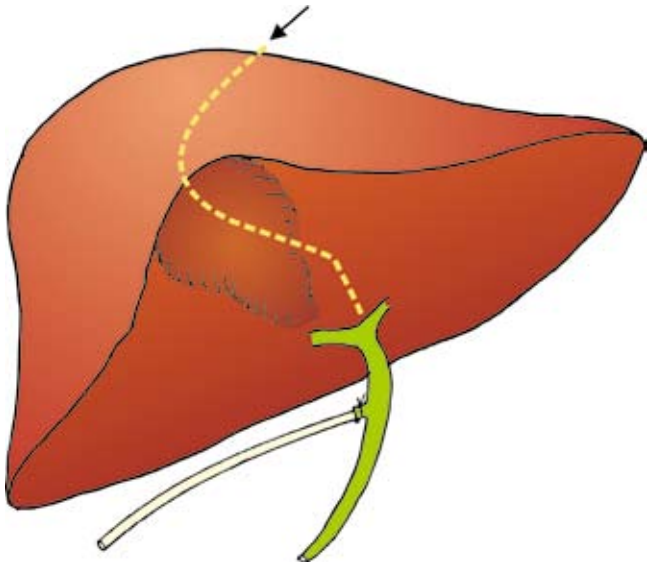

Figure 4.2. The liver transection line at the inferior surface of the liver starts at the tip of the gallbladder fossa and deviates to the left meeting the proposed transection point of the left hepatic duct. By the design, the first point where the middle hepatic vein is encountered is at the junction with the segment IVa hepatic vein.

junction of the LPV and right portal vein should be ligated and divided, whereas the branches to the left side of the LPV going into the caudate lobe should be protected. The lesser omentum is then exposed and inspected and palpated for the presence of an aberrant LHA. If the aberrant LHA is absent, the lesser omentum is divided and ligated.

The left triangular ligament is divided to detach the left liver from the diaphragm. Care is exercised to avoid injury to the left phrenic vein. The phrenic vein entering the LHV is divided and sutured to provide a longer length of the LHV at the time of graft delivery.[3] The left caudate lobe is then detached from the IVC by dividing the minor hepatic veins. A large caudate hepatic vein near the midline of the IVC should be preserved with the graft for subsequent implantation. At the cranial end, the ductus venosum is freed, ligated and divided. Further dissection will expose the posterior surface of the MHV. The common trunk of the LHV and MHV is now encircled.

Temporary clamping of the LHA and LPV will produce the demarcation line between the right and left livers. The line is marked by diathermy (Figure 4.1). At the inferior surface of segment IV, the transection line is drawn along the gallbladder fossa and deviated to the left side above the hilar plate to meet the point of proposed transection of the LHD (Figure 4.2). It is important to protect the right hilar structure by leaving the hilar plate on the right side intact. By making such division plane, the MHV will be encountered at where the segment IVa hepatic vein joins the segment V hepatic vein or the main trunk of the MHV (Figure 5.7). After division of the segment V hepatic vein or the MHV at this point, the right side of the MHV is exposed on the transection plane and followed until the junction with the IVC is seen. The course of the MHV now guides and determines the plane of transection. In case a large segment VIII hepatic vein drains into the MHV near to the IVC, it should be preserved for the donor to improve venous drainage of the right anterior sector because the segment V venous drainage is impaired after division of the main trunk at the point where the segment IV vein drains into it[4,5] (Figures 4.3 and 4.4). The length of the MHV in the graft may be short as a result, but implantation would not be a problem if the right hepatic vein (RHV) cuff of the recipient is preserved long during the hepatectomy. The retained RHV wall of the recipient could be used to anastomose to the MHV of the graft (Figure 4.5).

The liver transection is performed by the ultrasonic dissector (Cavitron Ultrasonic Surgical Aspirator, CUSA, Valley Lab, Boulder, CO, USA) without inflow vascular occlusion. There may be more bleeding from the MHV than in the right liver graft operation because the MHV is at the undersurface of the left liver transection plane.[6] In case of major bleeding from the MHV, temporary inflow vascular occlusion is used for clear visualization of the site of bleeding and accurate placement of sutures. The power of the ultrasonic dissector should be set at a lower scale on approaching the MHV to reduce damage to it. Low central venous pressure[7] and full muscle relaxation are needed to reduce the bleeding volume from the hepatic vein. The liver transection continues until the caudate lobe is reached. A tape or an instrument passed underneath the caudate or a right-angle clamp pushing up the caudate may expedite the transection. Forceful lifting must be avoided because it may avulse the hepatic vein and liver parenchyma. Before the caudate lobe is reached, the tape beneath the caudate lobe serves little purpose. It is important to remember that the initial transection plane in the left liver graft operation is not vertical but oblique and is determined by the position of the MHV. Only when the caudate lobe is reached does the transection plane become vertical. Sometimes the MHV is nearly horizontal

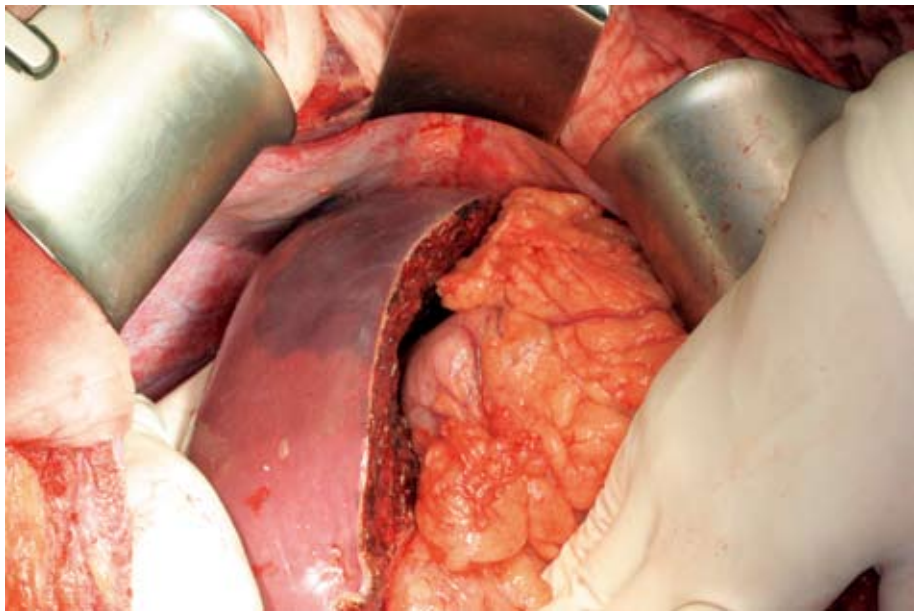

Figure 4.3. Dusky segment VIII after delivery of the left liver graft.



Figure 4.4. Computed tomography scan shows a larger segment VIII hepatic vein (arrows) draining into the middle hepatic vein near the inferior vena cava. This vein can be preserved with the donor's right liver remnant.

(Figure 4.6). Early lifting up the tape placed at the back of the liver will distort the transection plane. In all left liver graft donor operations, the MHV is an important anatomical landmark guiding the transection plane. A groove is expected to be seen at the right liver transection surface if the MHV is rigidly followed.

On approaching the hilar plate, another cholangiogram is performed to ascertain that the site of division of the LHD is appropriate. The major objective is to obtain a single hepatic duct orifice on the graft side and to avoid injury to the hepatic duct confluence (Figure 3.10). The anterior wall is divided first. Arterial and venous bleedings from the duct wall and hilar plate are controlled by 6-0 prolene immediately to provide a clear field for further division of the posterior wall of the LHD. The hilar plate is further divided and sutured. Careful inspection is made for any caudate hepatic duct. If small, it is sutured. If large, incorporation into the LHD could be considered or it is implanted separately.[8] The ductal orifice on the confluence side is closed by 6-0 PDS. Another cholangiogram is performed to ascertain that the confluence of the hepatic duct is not narrowed.

Similar to segment II/III graft, harvesting starts with clamping and division of the LHA and LPV. The caudate hepatic vein is clamped. Then the common trunk of the MHV and LHV is controlled by the vascular stapler [TA30, V3(7.5mm), United States Surgical, Norwalk, CT, USA]. It is then divided. Finally, the caudate hepatic vein is divided on the graft side. The left liver graft is delivered to the basin containing ice sludge. The liver graft is flushed by histidine-tryptophan-ketoglutarate (HTK) solution by a cannula inserted into the LPV and kept in place by pinching between fingers. About 1.5–2.0 L of HTK solution is used.[9] The LHA and LHD are also flushed by HTK solution. The hepatic vein orifices are inspected for the need of venoplasty.

On the donor side, the LHA stump is ligated and the LPV stump is sutured meticulously to avoid narrowing of the main trunk. The caudate hepatic vein is also sutured. Dilute methylene blue is instilled into the biliary tract for detection of leakage. The

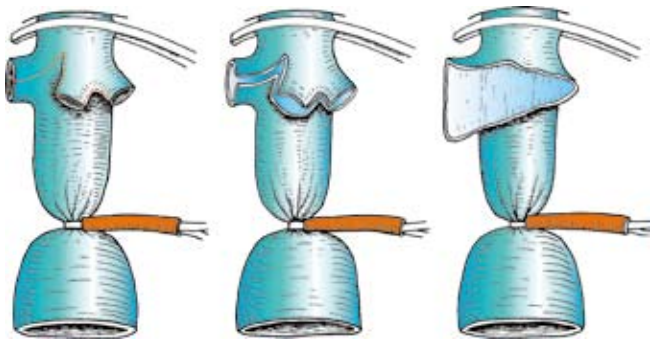

Figure 4.5. The anterior wall of the inferior vena cava and cuff of the middle hepatic vein / left hepatic vein are used for creation of a large triangular opening for most of the instances. In case the middle hepatic vein in the graft is short, the right hepatic vein of the recipient is retained longer in length and opened up for creation of a long and big triangular opening for anastomosis.

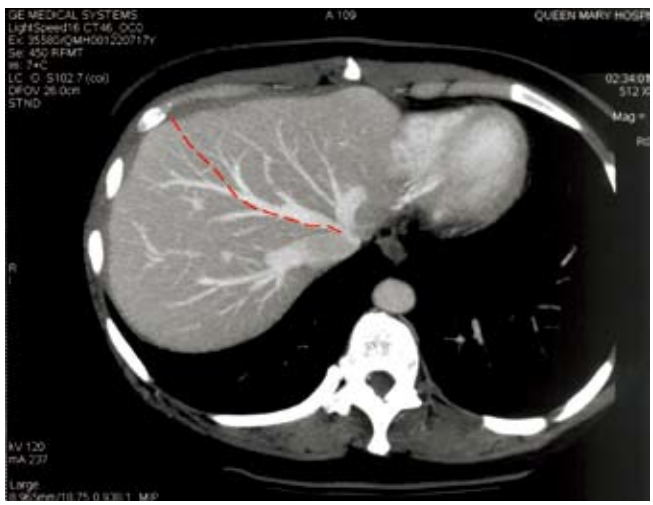

Figure 4.6. The transection plane should keep close to the middle hepatic vein. The transection plane is oblique and sometimes horizontal.

possible sites of leakage are the liver transection surface, the LHD stump and the hilar plate. If found, they must be sutured by 6-0 PDS.

After thorough inspection for bleeding and bile leakage, the wound is closed without drainage.[10] To detect minor bleeding, saline flushing of the transection surface is helpful. Pressing the transection surface by a piece of clean gauze may detect unsuspected bile leakage. Another dose of antibiotic is given to prevent wound infection.

Recipient operation

Bilateral subcostal incision with upward midline extension is made. Hilar dissection starts with cystic duct cannulation with a Fr. 3.5 cannula for subsequent bile leakage detection and cholangiogram if duct-to-duct anastomosis is performed. After division of the cystic duct, the right hepatic artery (RHA) is dissected free. Care is exercised to avoid dissecting the RHA around the common hepatic duct so as to protect the blood supply of the duct. The RHA is dissected above the level of the common hepatic duct into the right liver hilum so as to obtain a sufficient length for subsequent anastomosis. Not infrequently, the right anterior and posterior branches are separate at the right liver hilum. They may not be used for microvascular anastomosis. Rather, the RHA or LHA itself is used more frequently, but it is good practice to have a long RHA and its branches prepared for matching with the donor LHA and for the possibility of anastomosis failure. The RHA is clamped by the AcLand microvascular clamp (S&T AG, Neuhausen, Switzerland) and its branches divided. The common hepatic duct is divided high in the liver hilum. The recipient end is left open but bleeding vessels are plicated by 6-0 prolene sutures. The end on the liver side is sutured. The recipient side of the common hepatic duct is also inspected for minor caudate duct openings, which are preferably sutured at this stage to avoid missing during biliary anastomosis because they could be the source of postoperative bile leakage. The dissection is then carried out to the left side to free and divide the LHA. Finally, the portal vein and its two branches are freed. The portal vein is not clamped until the dissection of the retroperitoneum is completed and the liver graft is ready.

The liver is mobilized from both sides and the small hepatic veins are individually ligated, divided and/or sutured. The IVC ligament is sutured as it may contain a vein and could be the source of postoperative bleeding. After division of the IVC ligament, the RHV is encircled. Further dissection into the anterior surface of the IVC is made. Then, the IVC is approached from the left side by rotation of the left liver and detachment of the left caudate lobe. Finally, the common trunk of the LHV and MHV is encircled. If the field is clear, it is possible at this stage to mobilize the IVC from the back of the retroperitoneum. However, if there is difficulty, this step can be left until the diseased liver is removed.

When the liver graft is available, the portal vein is clamped by the Blalock vascular clamp (Blalock Pulmonary Artery Clamp, Pilling Weck, Research

Triangle Park, NC, USA) (Figure 4.7), which is preferred for better orientation of the transverse axis of the anastomosis. The LPV and right portal vein are clamped high in the liver hilum and divided. Vascular clamps are placed to control the hepatic veins and the diseased liver is removed. After hemostasis, the IVC is separated from the retroperitoneum. Dissection is easier if the plane is kept close to the IVC. The mobilization of the IVC is made to the level of the adrenal gland and not necessarily further down. A number of lumbar and phrenic veins may have to be ligated and divided before the mobilization is completed.[3] Suturing of the divided hepatic vein stumps on the IVC, even though they are relatively small, is preferred because the knots may be dislodged on manipulation of the IVC afterward. The infrahepatic IVC is then controlled by cotton tape which is preferred to allow more space for the surgeon's right-hand manipulation. If the blood pressure is well-maintained, the suprahepatic IVC is cross-clamped by the Ulrich-Swiss clamp (Ulrich AG, St Gallen, Switzerland) (Figure 5.26). The clamps on the hepatic veins are removed and the IVC content is flushed away by heparin-saline. The RHV orifice is normally not used for anastomosis. It is closed by 5-0 running suture. In case the MHV of the graft is short, the RHV stump should be left long and used for anastomosis (Figure 4.5).

To prepare for the hepatic vein anastomosis, the septum of the MHV and LHV is divided and the right wall of the MHV is cut across into the anterior wall of the IVC. The direction of the cutting is then made longitudinally and caudally. The purpose is to create a large triangular opening that matches with that of the left liver graft (Figure 3.24). Part of the caudal side of the MHV and LHV has to be excised. The anastomosis is performed first on the right side of the triangle, followed by the inferior side and finally the superior side. The caudate hepatic vein is then anastomosed to the sidewall of the IVC.



Figure 4.7. Blalock vascular clamp.

If long enough, the LPV of the liver graft is then clamped by the bulldog vascular clamp. Attention is paid to the orientation. The presence of the caudate portal vein orifice as seen inside the lumen provides a good guide of the correct orientation. The IVC clamps are removed to allow restoration of blood flow in the IVC. It serves to reduce congestion of the retroperitoneum and hence less bleeding, reduce the renal congestion and allow backflow reperfusion of the liver graft.[9] Bowel congestion and swelling may be less because blood in the collateral can now drain through the IVC. In the absence of bleeding from the retroperitoneum and vascular clamps protruding from the abdominal cavity, portal vein anastomosis can be performed without much hindrance and at ease.

Normally, the LPV of the recipient is used for anastomosis to the graft LPV. In case the main portal vein is long and kinking is anticipated, the main trunk of the portal vein is used instead.

Hepatic artery anastomosis or reconstruction is performed by the microvascular technique. The LHA or RHA is used depending on the size match, orientation and vessel quality. Bluish discoloration of the hepatic artery is not infrequently observed. It is due to either intimal dissection (which is more serious) or bleeding in the adventitia. As long as there is adequate blood flow from the lumen of the artery, microvascular anastomosis can be accomplished with good result.

Biliary reconstruction is by hepatico-jejunostomy or duct-to-duct anastomosis, depending on whether the recipient's own common hepatic duct is long enough or not. Stent is usually not required. In case duct-to-duct anastomosis is performed, the cystic duct cannula left in situ can be used for checking of leakage by methylene blue or cholangiography. After thorough irrigation of the abdominal cavity, the graft is anchored to the anterior abdominal wall to prevent rotation into the right subphrenic cavity and the wound is closed without abdominal drainage.

Postoperative care

The donor is nursed in the intensive care unit for the first day. Attention is paid to maintain blood pressure, oxygen saturation, urine output, and pain control. Intravenous fluid administration is kept

at minimum because overloading may impair venous return of the liver remnant. Indicators of liver function recovery, e.g. base excess, international normalized ratio and serum bilirubin, are closely monitored. Serum aspartate aminotransferase and alanine aminotransferase levels may be high because the undrained segments V and VIII may be large in volume. In case of persistent elevation of aspartate aminotransferase and alanine aminotransferase levels and failure of the international normalized ratio to improve, Doppler ultrasonography must be performed to detect abnormality in the vasculature of the liver remnant. Attention is also paid to chest physiotherapy, early mobilization and early oral feeding. Psychological support by a clinical psychologist should continue, especially when the recipient is not recovering well from the operation.

The recipient is cared for in much the same way as those receiving deceased donor whole grafts and right liver grafts. The patient is ventilated mechanically until strong respiratory effort is evident. Intravenous fluid administration (except albumin) is withheld. If an abdominal drain is inserted, fluid replacement according to the drain output may be needed. Regular surveillance by Doppler ultrasonography is performed. The current immunosuppressive protocol consists of low-dose FK506, two doses of steroid (first dose during the anhepatic phase and second dose 24 hours afterward), interleukin-2 receptor antagonist, and mycophenolate mofetil.[11] Attention is paid to oxygenation, blood pressure and urine output. If liver function recovery is delayed or sign of sepsis is evident, imaging should be done promptly and threshold for relaparotomy should be low. An adult receiving the left liver graft may develop more ascites than one receiving the right liver graft because the graft size is just marginally adequate. In the absence of abdominal drain, tense ascites may develop and paracentesis is needed to relieve the intra-abdominal pressure, improve renal function, and restore urine output.

References

1. Ikegami T, Nishizaki T, Yanaga K, Shimada M, Kakizoe S, Nomoto K, Hiroshige S, Sugimachi K. Changes in the caudate lobe that is transplanted with extended left lobe liver graft from living donors. Surgery 2001; 129: 86-90.
2. Takayama T, Makuuchi M, Kubota K, Sano K, Harihara Y, Kawarasaki H. Living-related transplantation of left liver plus caudate lobe. J Am Coll Surg 2000; 190: 635-638.
3. Dulundu E, Sugawara Y, Kishi Y, Akamatsu N, Kokudo N, Makuuchi M. Phrenic vein dissection in partial liver graft harvesting. Hepatogastroenterology 2006; 53: 778-780.
4. Hwang S, Lee SG, Ha TY, Ahn CS, Park KM, Kim KH, Moon DB, Song GW, Kim DS, Jung JP. Feasibility assessment for tailoring preservation of segment VIII hepatic vein during left liver graft procurement. Hepatogastroenterology 2006; 53: 928-932.
5. Kishi Y, Sugawara Y, Akamatsu N, Kaneko J, Matsui Y, Kokudo N, Makuuchi M. Sharing the middle hepatic vein between donor and recipient: left liver graft procurement preserving a large segment VIII branch in donor. Liver Transpl 2004; 10: 1208-1212.
6. Chan SC, Fan ST, Lo CM, Liu CL. Effect of side and size of graft on surgical outcomes of adult-to-adult live donor liver transplantation. Liver Transpl 2007; 13: 91-98.
7. Johnson M, Mannar R, Wu AV. Correlation between blood loss and inferior vena caval pressure during liver resection. Br J Surg 1998; 85: 188-190.
8. Kubota K, Takayama T, Sano K, Hasegawa K, Aoki T, Sugawara Y, Makuuchi M. Small bile duct reconstruction of the caudate lobe in living-related liver transplantation. Ann Surg 2002; 235: 174-177.
9. Chan SC, Liu CL, Lo CM, Fan ST. Applicability of histidine-tryptophan-ketoglutarate solution in right lobe adult-to-adult live donor liver transplantation. Liver Transpl 2004; 10: 1415-1421.
10. Liu CL, Fan ST, Lo CM, Chan SC, Yong BH, Wong J. Safety of donor right hepatectomy without abdominal drainage: a prospective evaluation in 100 consecutive liver donors. Liver Transpl 2005; 11: 314-319.
11. Liu CL, Fan ST, Lo CM, Chan SC, Ng IOL, Lai CL, Wong J. Interleukin-2 receptor antibody (basiliximab) for immunosuppressive induction therapy after liver transplantation: a protocol with early elimination of steroids and reduction of tacrolimus dosage. Liver Transpl 2004; 10: 728-733.

5. Right liver graft

(including the middle hepatic vein)

Donor operation

The donor is placed supine on the operating table, preferably with the upper limbs adducted to avoid brachial plexus injury. Attention is paid to avoid pressure sores developing at the ankles and occiput. Devices to prevent deep vein thrombosis are applied to the legs. Anticoagulant is not given unless a female donor has a recent history of taking contraceptive pills. Warming devices are applied over the lower limbs and neck. The room temperature is set at 22°C to 23°C to avoid excessive heat loss via exposed viscera. Intravenous fluid warmer is also used. A dose of antibiotic is given at the time of skin incision. H_2-receptor antagonist is also given. Central venous pressure line could be avoided if the surgeon is confident with the operation.[1] Red cell salvage, preoperative autologous blood donation or intraoperative hemodilution is not performed in our center.[2,3] Bilateral subcostal incision with upward midline extension is made. The left side extension is needed for mobilization and rotation of the right liver. If the donor is thin and the body cavity is not deep, the left side extension may not be necessary. The xiphoid process is removed to allow sufficient exposure of the suprahepatic inferior vena cava (IVC) which should be approached vertically rather than from below. A Bookwalter retractor (Codman and Shurtleff, Inc, Raynham, MA, USA) is then applied.

The cystic duct is freed and cannulated by a Fr 3.5 catheter. Next, the supraduodenal part of the common bile duct is freed to allow application of an atraumatic vascular clamp (Featherlight Bulldog Clamp, Geister, Inc, Tuttlingen, Germany) (Figure 3.4). It may not be necessary to encircle the common bile duct entirely. Care is taken to avoid injury to the common bile duct lymph node and the head of the pancreas. Otherwise, troublesome bleeding may occur. At the liver hilum, gentle dissection is made to identify the confluence of the hepatic ducts. A large-size Liga clip (Ethicon Ltd, Edinburgh, UK) is applied to the liver capsule at the point where the proposed transection of the right hepatic duct (RHD) is. Then, a cholangiogram is obtained by undiluted contrast delivered via the cystic duct cannula. Occlusion of the common bile duct by the atraumatic vascular clamp will facilitate opacification of the entire intrahepatic duct system. The sequence of the segmental duct filling by contrast is observed on fluoroscopy and the images are captured serially for documentation and backward viewing if needed.[4] The location of the Liga clip in relation to the RHD is studied and, if needed, the clip is re-positioned until the most appropriate position of duct division is determined. Then, the position is marked by diathermy on the liver capsule near to the RHD, which is not dissected at this stage, unless the confluence of the hepatic ducts is low and obvious. This is because complete dissection of the RHD at this time could be difficult, and overzealous dissection of the RHD may result in removing the tissue around the RHD, leading to thinning of the ductal wall and ischemic injury.

A good cholangiogram is the most essential step in the success of the operation. Interpretation of cholangiogram finding may be difficult if the RHD and left hepatic duct overlap with each other at the liver hilum. Counterclockwise rotation of the X-ray tube to the right side of the donor may produce a clear display of the RHD and left hepatic duct branches (Figures 5.1, 7.5 and 7.6).

The right hepatic artery (RHA) is freed. The dissection for the RHA should not be made beyond the left side of the common hepatic duct and into the space in between the RHD and RHA (Figures 7.1 and 7.2B) to protect the blood supply to the common hepatic duct and RHD, respectively. Presence of the segment IV hepatic artery arising from the RHA may be recognized on preoperative imaging or at the time of hilar dissection. It must be preserved to prevent ischemic necrosis of segment IV. If uncertain, the RHA or the suspicious branch is occluded temporarily and Doppler scan performed to ascertain that blood flow within the segment IV hepatic artery is intact. Sometimes, there may

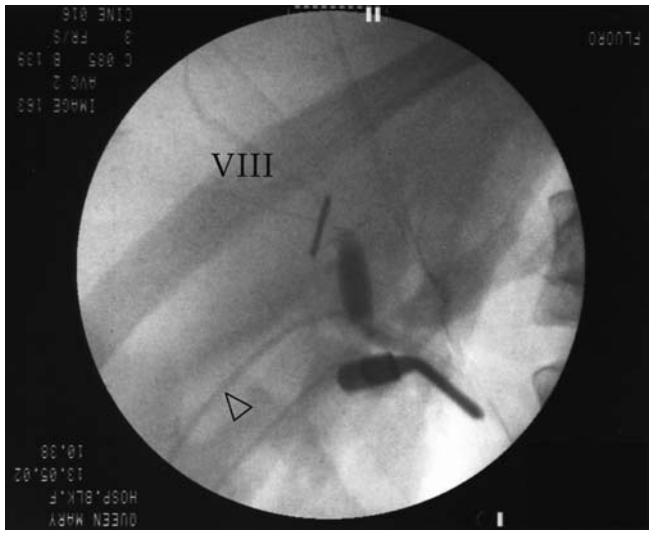

A

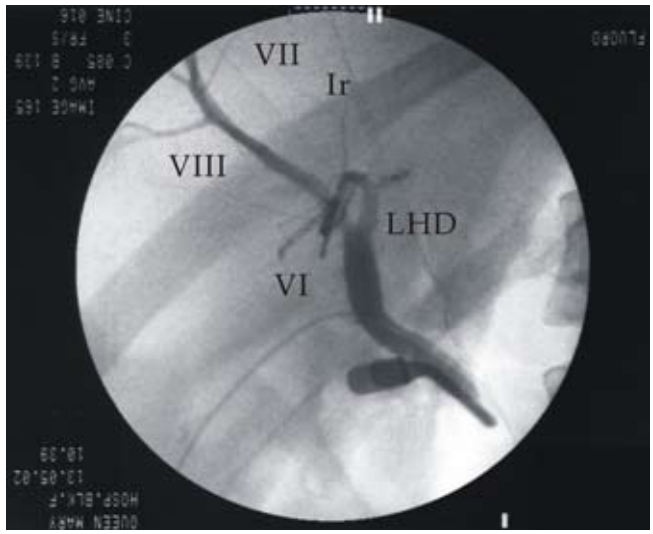

B

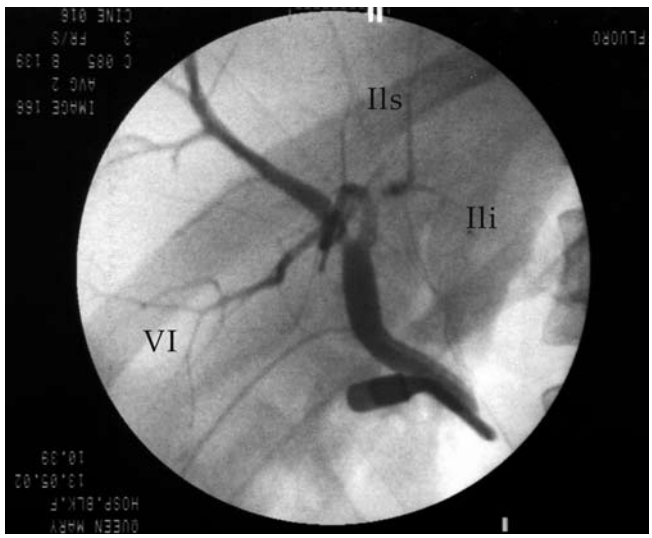

C

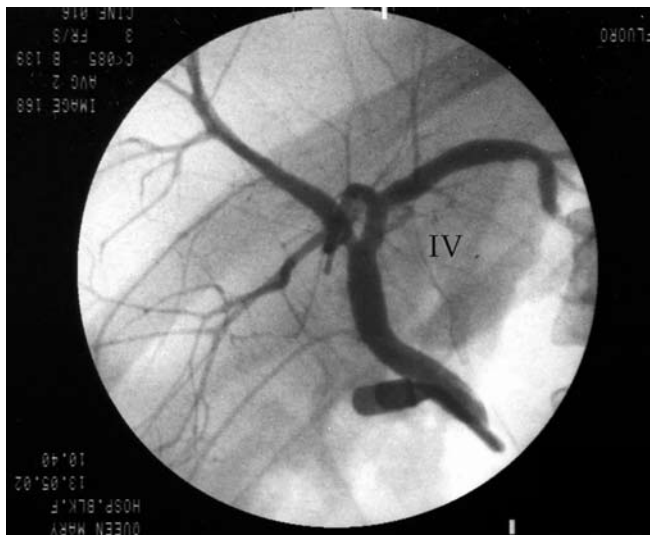

D

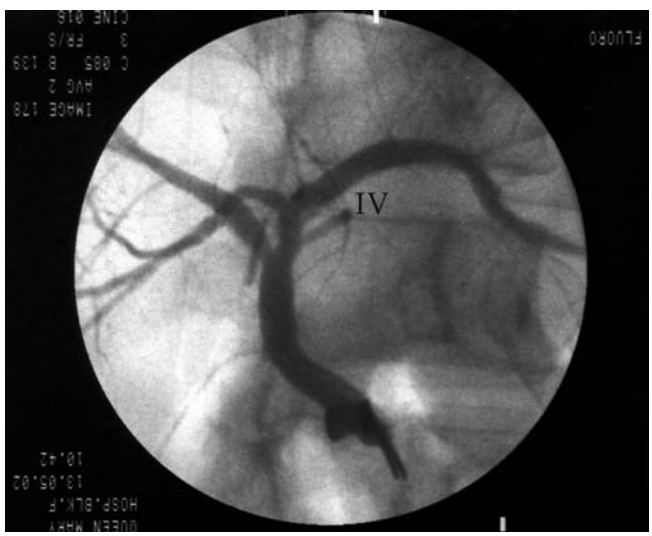

E

Figure 5.1A-E. Operative cholangiogram via a cannula (▷) inserted into the cystic duct. A bulldog vascular clamp was used to occlude the supraduodenal portion of the common bile duct. In this case, the first segmental branch filled by contrast was the segment VIII duct because the right posterior duct joined the left hepatic duct (LHD) **(A)**; The LHD was shown by more contrast filling. The right posterior duct joined the LHD. From the right posterior duct, the segment Ir, VII and VI ducts were seen **(B)**; The entire segment VI duct was shown by further contrast filling. On the left side, segment IIs (left superior) and segment IIi (left inferior) ducts were shown **(C)**; The segment IV duct was shown by further contrast filling. It appeared that the segment IV duct joined the LHD. The right hepatic duct branches overlapped with each other at the liver hilum and the display was not clear **(D)**; After counterclockwise rotation of the X-ray tube, the display of the right anterior and posterior hepatic ducts became clear. The segment IV duct was seen to join the common hepatic duct in this case **(E)**.

be communication between the segment II/III and segment IV hepatic arteries. If the segment IV hepatic artery is very close to the right liver hilum, it may be sacrificed to render a longer RHA, but the communication between segment II/III and segment IV hepatic artery must be ascertained firmly by Doppler ultrasonography. Next, the right portal vein (RPV) is freed and encircled. To obtain a suf-

ficiently long RPV for subsequent anastomosis, the caudate branches must be divided and ligated. Any branch that goes near into the right posterior portal fissure (Rouviere groove) must be preserved. It may be early branching of the segment VI portal vein.

After hilar dissection, the caudate process is separated from the anterior surface of the IVC by dividing the overlying peritoneum and caudate hepatic vein. The inferior right hepatic vein (RHV) (draining segment VI) may be exposed and encircled by this approach. The size of the inferior RHV that has to be preserved is arbitrarily set at 5 mm (Figures 5.2 and 5.3), but cases of segment VI congestion have been seen when the inferior RHV was 4 mm and ligated. Sometimes, stretching of the vein on lifting up the liver may render the vein narrower than it should be. To prevent graft congestion and suboptimal graft function, temporary occlusion of the inferior RHV should be made and segment VI color observed. If discoloration is seen, the inferior RHV, even if it is less than 5 mm, must be preserved.

The right liver is then mobilized by dividing the right triangular ligament. To provide enough space for right liver rotation, the left subcostal wound or the midline wound must be lifted up by the self-retaining retractor. The liver is rotated entirely into the left subphrenic space rather than lifting out of the abdominal cavity. The latter maneuver is ineffective for exposure of the right and anterior surface of the IVC and may cause ischemic injury to the liver by compressing against the wound. Rotation of the liver may cause torsion of the inflow and outflow vasculature. Therefore, rotation of the liver is intermittent and limited to 20

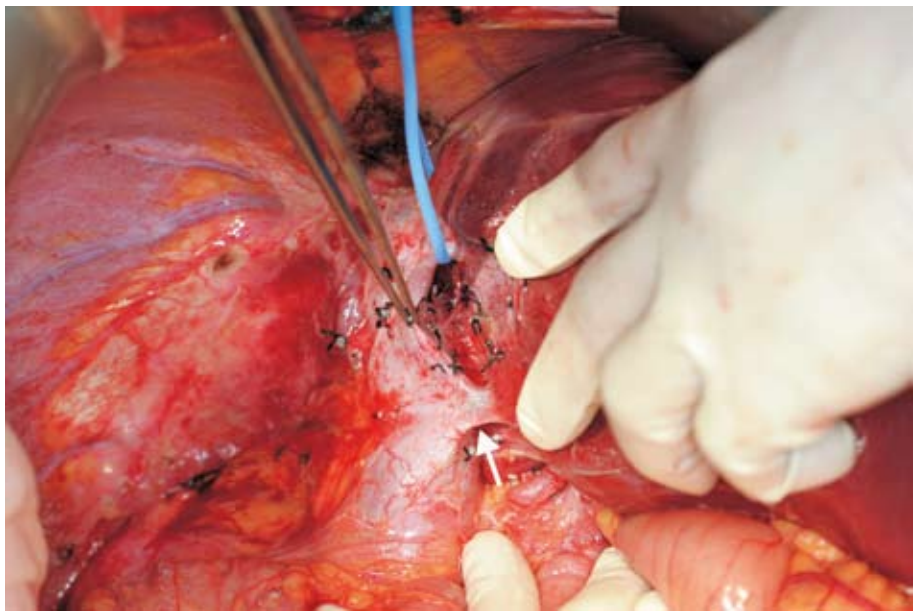

Figure 5.2. The inferior right hepatic vein (arrow) is preserved. It is necessary to free the inferior vena cava to the left side of the inferior right hepatic vein and right hepatic vein to facilitate subsequent liver transection.



Figure 5.3. Segment VI congestion as a result of sacrifice of the inferior right hepatic vein. The computed tomography scan was performed on postoperative day 6 because the recipient had impaired liver function. The size of the inferior right hepatic vein was 6 mm on computed tomography scan. It was judged to be smaller than 6 mm intraoperatively and was not included in the graft. Sometimes, stretching of the vein during measurement may render the diameter of the vein smaller than it should be.



Figure 5.4. Computed tomography scan illustrates the presence of liver tissue surrounding the inferior vena cava (arrow). In this situation, the inferior vena cava ligament is composed of liver tissue. Difficulty will be encountered on dissection from the inferior vena cava.

minutes for each period. Gauze that is inadvertently left in the liver hilum or lesser omentum will aggravate the inflow occlusion. A pack covering the duodenum and stomach may also prevent efficient rotation of the liver into the left subphrenic space. Therefore, all packs and gauzes must be removed before right liver rotation. During the liver rotation, the right adrenal gland is vulnerable to tearing and serious bleeding. Thus, the mobilization has to be slow and cautious. Sharp dissection using cautery may have to be applied if the adrenal gland is firmly adhered to the liver capsule. If the space in between the caudate process and the anterior surface of the IVC has been cleared, the right adrenal gland could be easily encircled for ligation and hemostasis. When bleeding has occurred, suturing the right adrenal gland is preferred to diathermy or argon beam coagulation for secure hemostasis. Further dissection will then expose the IVC ligament. Careful dissection is performed to isolate it from the IVC. It is clamped, divided and sutured because it may contain a vein and may be the cause of postoperative bleeding. Occasionally, the IVC ligament is composed of thick liver tissue encircling the entire IVC causing difficulty of dissection (Figure 5.4). In such instance, the dissection has to proceed slowly to avoid damaging the IVC. The RHV is then encircled. Further dissection is made until the anterior surface of the IVC is cleared to facilitate subsequent liver transection. A large caudate hepatic vein may be present at this site. It is encircled by tape and protected. The presence of an intact caudate hepatic vein will reduce segment IV congestion via intrahepatic collaterals and facilitate liver regeneration. If possible, the space in between the RHV and middle hepatic vein (MHV) is also cleared at this stage (Figure 5.2).

The RHA and RPV are then occluded temporarily to produce the demarcation line between the right and left livers. The line is marked by diathermy. The demarcation between the right and left livers is usually obvious immediately upon clamping of the

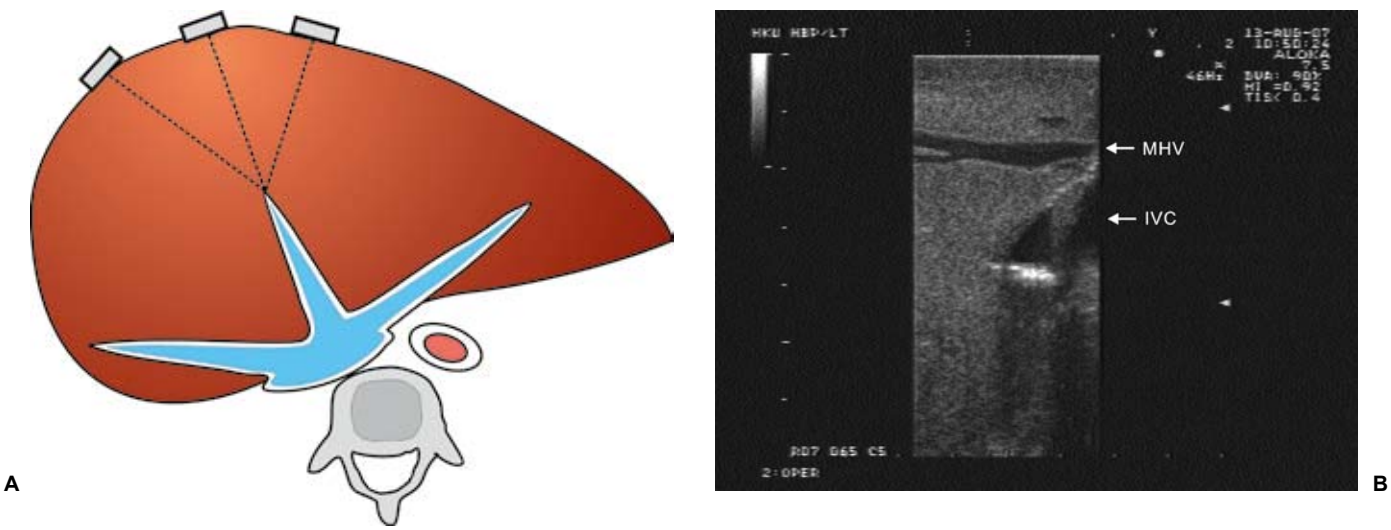

Figure 5.5A,B. The middle hepatic vein (MHV) could be seen by an ultrasound probe placed on any part of the liver depending on the tilting of the probe. Deciding the liver transection line based on the location of the MHV on ultrasonography is therefore not accurate **(A)**; The MHV is seen for full length on intraoperative ultrasonography. The inferior vena cava (IVC) is also seen at the same position. This is most likely the correct plane for liver transection **(B)**.

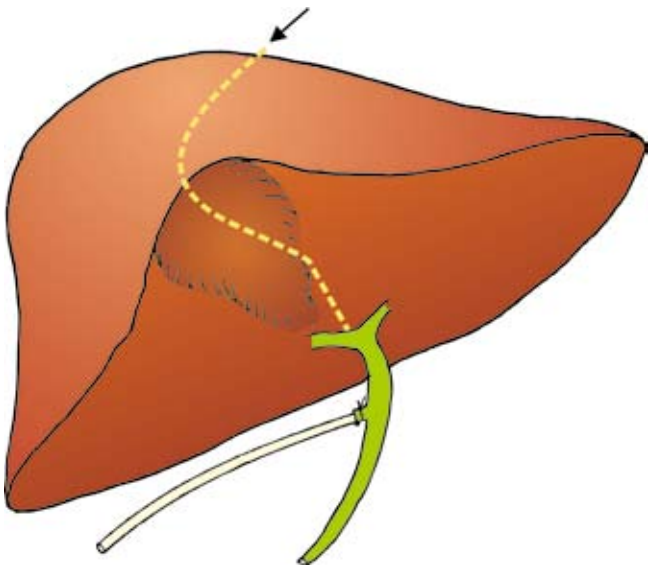

Figure 5.6. The liver transection line at the inferior surface of the liver.

RPV and RHA. If not, there may be a right anterior hepatic artery or right anterior portal vein missed at the liver hilum (Figure 2.5). Occasionally, a large communicating branch between the RHA and left hepatic artery (LHA) may exist in the hilar plate leading to persistent arterial perfusion of the right liver and difficulty in identification of the demarcation. In such situation, the Cantlie line can be established by localization of the MHV by intraoperative ultrasonography. The plane at which the MHV could be seen longitudinally in line with the cranial part of the retrohepatic IVC is the correct plane[5] (Figure 5.5). At the inferior surface of the liver, the transection line begins at the gallbladder fossa and is deviated to the left side of the gallbladder fossa meeting the proposed point of RHD division (Figure 5.6). By such design, a small amount of liver tissue is left to protect the RHD which is not denuded. It is not known whether this small amount of liver tissue is necrotic or not. If so, infection in this area may predispose to stenosis of RHD anastomosis in the recipient. Since this is done routinely but RHD

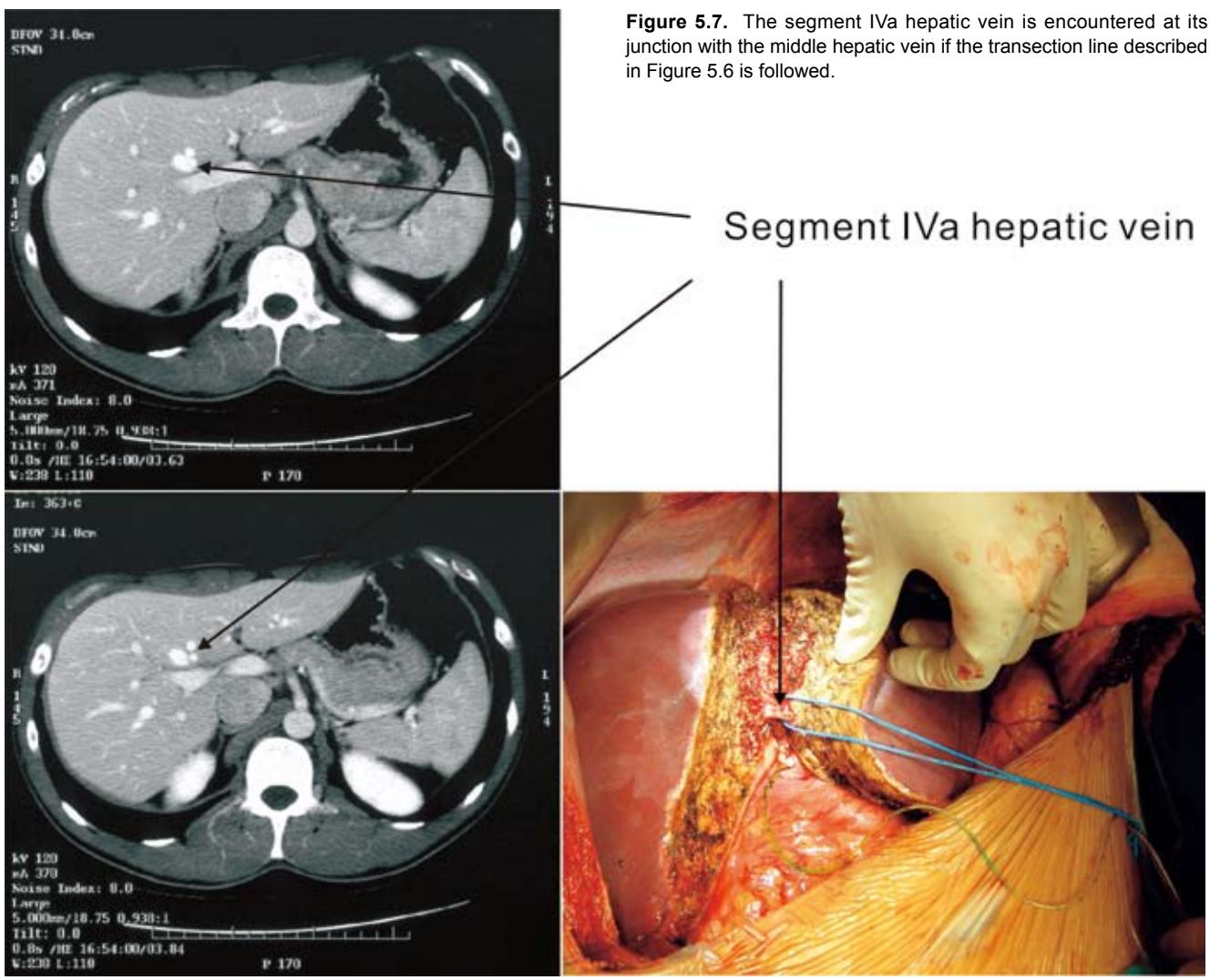

Figure 5.7. The segment IVa hepatic vein is encountered at its junction with the middle hepatic vein if the transection line described in Figure 5.6 is followed.

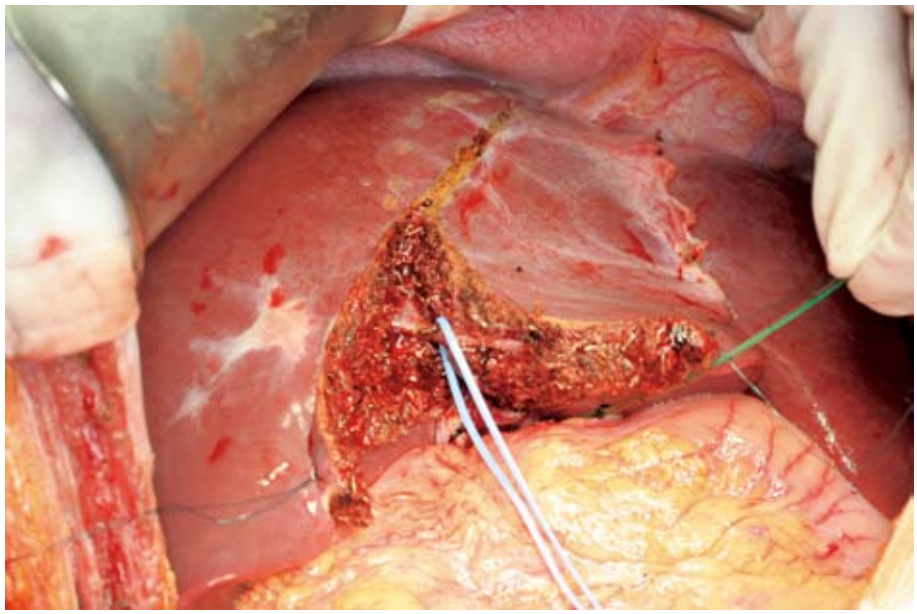

Figure 5.8. At the initial transection plane, the segment IV hepatic vein (blue sling) was encountered. Tracing of this vein exposed the junction with the segment V and the main trunk of the middle hepatic vein. In this donor, the segment IVa and V hepatic veins joined together to form a main trunk.

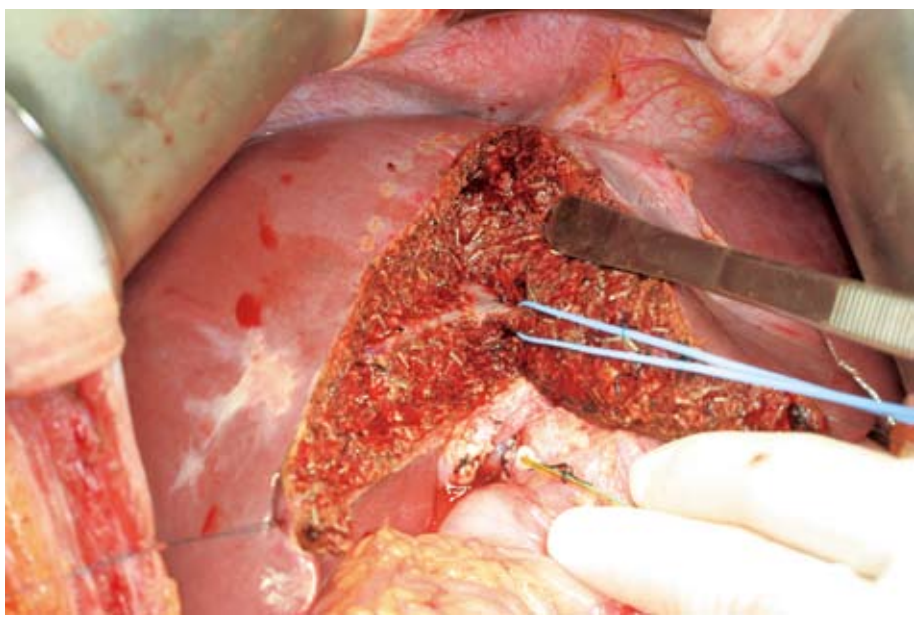

Figure 5.9. The need for exposure of the middle hepatic vein as a guide to liver transection is illustrated here. The donor was the same as that shown in Figure 5.8. Another large segment IV hepatic vein was encountered and clearly exposed. If the middle hepatic vein had not been exposed, it would be difficult to know the exact nature of the vein when it was encountered in the midst of liver parenchyma.

stenosis does not occur in every recipient, the worry may not be real. Moreover, during liver transection in this area, bleeding is frequently encountered. Perhaps there is sufficient blood supply from the hilar plate to maintain this part of liver viable. Thus, we continue to practise this design. The other advantage of designing such transection plane is that the MHV will not be damaged because it is encountered tangentially. In about 70% of the cases, the MHV originates near the gallbladder fossa in the midplane. If the initial transection is exactly at the midplane, the MHV may be divided longitudinally during the liver transection leading to torrential bleeding.

Liver transection is done by the ultrasonic dissector (Cavitron Ultrasonic Surgical Aspirator, CUSA, Valley Lab, Boulder, CO, USA) without inflow or outflow vascular occlusion. The ultrasonic dissector is set at the amplitude of 60% of maximum, irrigation with normal saline about 4–6 mL/minute and suction power of 20% of maximum. Using the line of liver transection described above, the distal portion of the MHV will be protected and encountered usually at the point where it is joined by the segment IVa hepatic vein (Figure 5.7). After dividing the segment IVa hepatic vein, the main trunk of the MHV is exposed and used as a guide or landmark for liver transection (Figures 5.8–5.10). It is useful to remember that the liver transection plane for right hepatectomy is oblique rather than vertical (Figure 5.11). In some thin donors, the transection plane may be nearly horizontal (Figure 5.12). Without exposure of the MHV as a guide and if a vertical transection plane is adopted, the MHV may never be included in the graft and ischemic liver tissue may be present on the left transection surface. In addition, a vertical transection plane may expose or damage the right anterior portal pedicle (Figure 5.13) or the segment IV portal pedicle (Figure 5.14). Not infrequently, the MHV branches lie beneath the segment IV por-

tal branches. By following the course of the MHV, confusion of anatomy could be avoided (Figure 5.11)

During liver transection, the MHV is exposed all the way to the junction with the left hepatic vein (LHV) or IVC (Figure 5.15). The segment IVb hepatic vein joining the MHV should be preserved as far as possible to secure venous drainage of the segment IV (Figure 5.11). We previously demonstrated that the first postoperative day international normalized ratio (INR) was significantly higher if the segment IVb hepatic vein was not preserved.[6] Although there was rapid normalization of the INR in the subsequent postoperative days, any sizeable segment IVb hepatic vein should be preserved because every step must be made to provide a wider safety margin for the donor.

Occasionally, there is a large branch of segment IVb hepatic vein (or segment III hepatic vein) joining the MHV high above the MHV/LHV/IVC junction, whereas a segment VIII hepatic vein joins the MHV near the IVC on the right side (Figure 5.16). This anatomical anomaly was considered as a contraindication to including the MHV in the right liver graft in the past. However, we now realize that it is possible to overcome such anatomical difficulty by venoplasty and modification of the anastomosis technique. Alternatively, a venous conduit [obtained from the recipient's left portal vein (LPV) or cryopreserved vein graft] may be used to lengthen the MHV.[7]

The RHD is divided at the time when liver transection approaches the hilar plate, but is preferred to defer until most of the MHV is exposed because the main trunk of the MHV is near to the liver hilum and avulsion of the hepatic vein branches may occur during RHD division. At this time, another cholangiogram is performed to determine precisely the site of RHD division using a metal clip. Such meticulous step is necessary to ensure that the liver graft contains one hepatic duct orifice as far as possible,

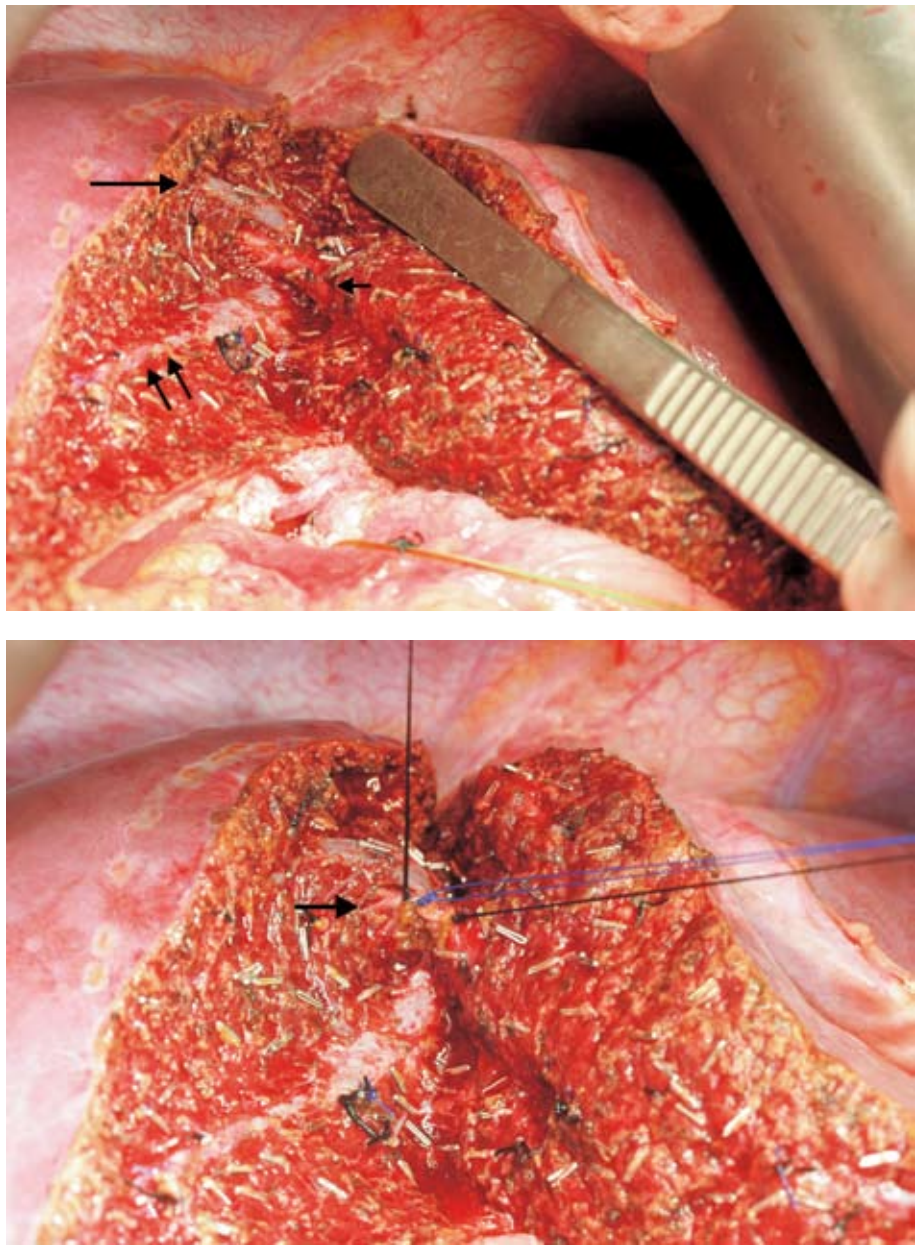

Figure 5.10A,B. Further liver transection in the donor shown in Figure 5.8 exposed the segment VIII hepatic vein (long arrow) **(A)** and terminal branches of the segment IV portal pedicle (short arrow) **(B)**. These structures and the middle hepatic vein (double arrows) may cross each other on the transection plane. Following the middle hepatic vein will reduce confusion. Lifting up of the segment IV portal pedicle exposes its terminal branches (short arrow). Occasionally, there is crossing of segment IV into segment VIII or vice versa accounting for the indistinct demarcation after clamping of the right portal vein and right hepatic artery. In this case, after division of the segment IV pedicle, the transection proceeds along the segment VIII hepatic vein until it joins the middle hepatic vein.

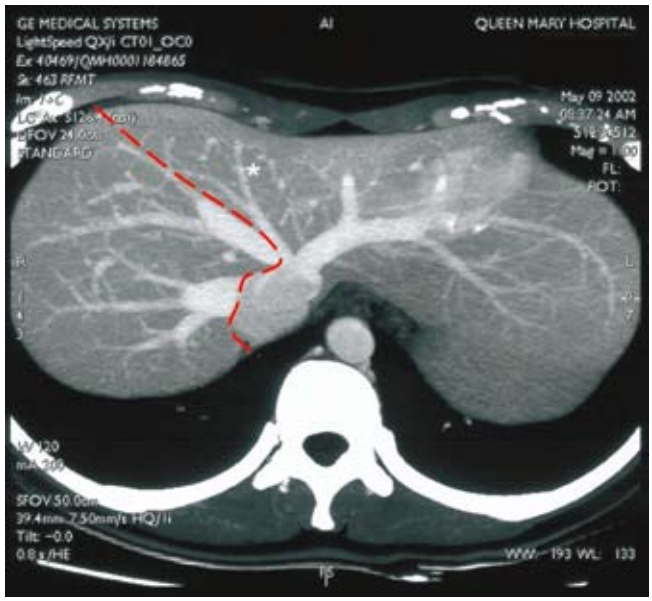

Figure 5.11. The transection plane of the right liver graft is oblique. The segment IVb hepatic vein (asterisk) is preserved to ensure adequate venous drainage of segment IV.

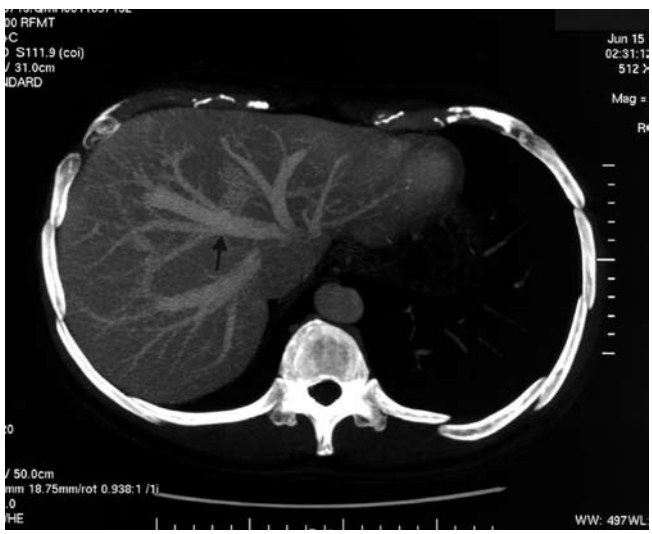

Figure 5.12. The middle hepatic vein (arrow) (and the midplane) is almost horizontal in this donor.

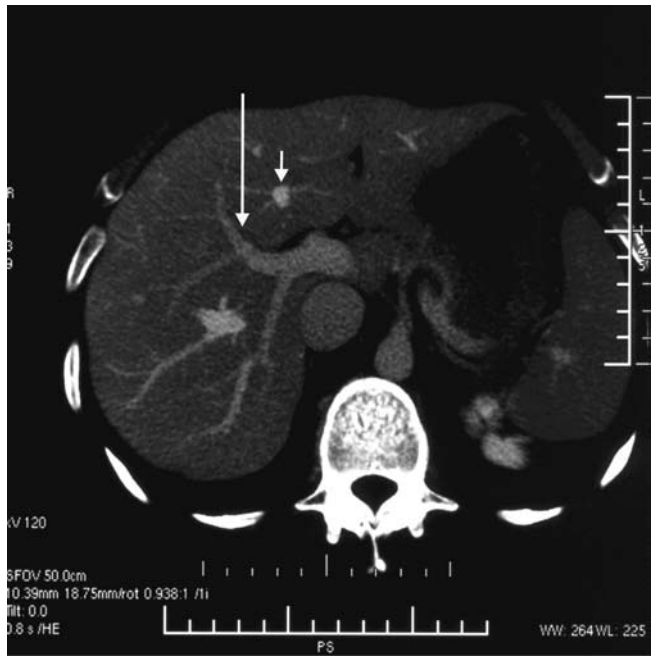

Figure 5.13. A vertical transection plane starting at the demarcation line on the anterior surface of the liver is undesirable. It may damage the right anterior portal pedicle (long arrow) and leave much devitalized tissue in between the transection plane and the middle hepatic vein (short arrow).



Figure 5.14. The middle hepatic vein (▷) is dorsal to the segment IV pedicle (arrow). A vertical transection plane to the left side of demarcation will injure the segment IV hepatic duct, which could be a cause of postoperative bile leakage.

but at the same time, a cuff of about 2 mm should be left at the division site so as to prevent narrowing the hepatic duct confluence of the donor (Figure 5.17). Once determined, the RHD is divided by a knife or scissors. Brisk bleeding is seen from the duct wall and nearby hilar plate. Prompt hemostasis by suturing using 6-0 prolene is made to reduce unnecessary blood loss and provide a clear field for further division of the RHD and the hilar plate. The hilar plate posterior to the RHD is further divided. A major arterial branch communicating the right and left hepatic arteries may be encountered at this point. It is divided between ligatures. Any bleeding or minute caudate hepatic duct openings are sutured immediately. Ligation of the hilar plate next to the RHD opening is not preferred because it may narrow the duct orifice and slippage of ligature may be the cause of bile leakage from caudate branches. The duct orifice on the side of hepatic duct confluence is then closed by 6-0 PDS continuous suture.

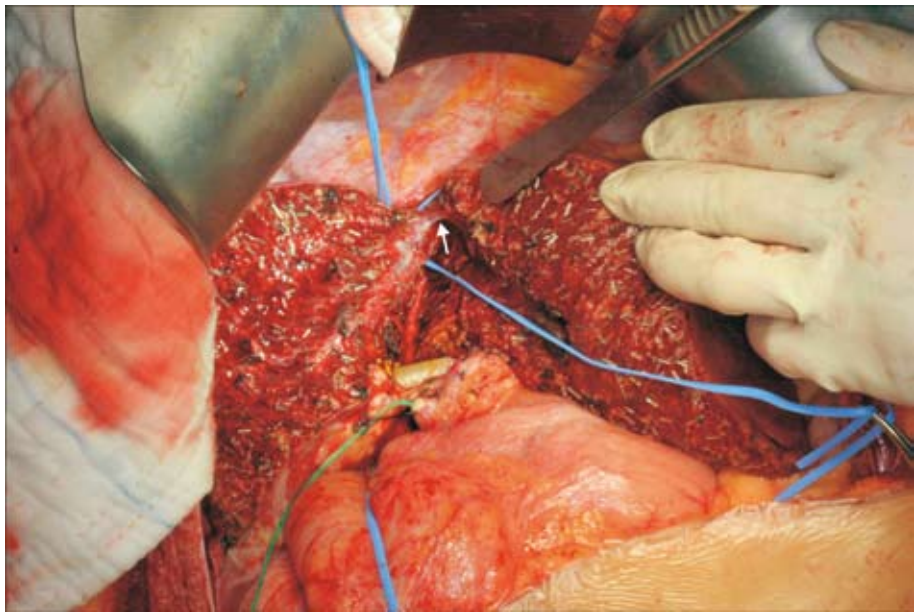

Figure 5.15. Segment IVb hepatic vein (arrow) is preserved for venous drainage of segment IV. The middle hepatic vein is exposed down to the junction with the segment IVb hepatic vein. Only exposure of the middle hepatic vein will allow safe liver transection and preservation of the segment IVb hepatic vein.

Another cholangiogram is performed to check the integrity of the ductal system.

After division of the hilar plate, the caudate process is divided by the ultrasonic dissector and the anterior surface of the IVC is exposed. Further liver division in the cranial direction will expose the caudate portal pedicle, which must be sutured or ligated (Figure 5.18). Failure to do so may cause postoperative bile leakage in either the donor or the recipient. To facilitate the division of the caudate lobe, an instrument, a tape or the left index finger of the assistant passing behind the right caudate lobe will be useful. Earlier passage and lifting of the liver by a tape[8] right from the beginning of liver transection is not preferred because the maneuver may distort the transection plane. As explained before, the transection plane of right hepatectomy is not vertical but oblique. The transection is guided by the MHV rather than the tape. On approaching the root of the MHV, the caudate branch of the hepatic vein will be encountered. It must be ligated rather than clipped because the clips may slip or be caught in the vascular clamp in the subsequent division of the MHV causing severe bleeding.

The liver tissue and the capsule at the back of the MHV are then cleared to obtain a longer MHV cuff (Figure 5.19). On completing the liver transection, division of the tissue around the vein by scissors will be more effective and less damaging than the ultrasonic dissector. By this procedure, a longer extrahepatic portion of the MHV could be obtained.

Currently, there are many liver transection devices. The Waterjet dissector employs the same mechanism as the ultrasonic dissector. Without adequate suction, the view at the dissection field is poor. Other devices, such as the TissueLink (TissueLink Medical Inc, Dover, NH, USA), Harmonic scalpel (Ethicon Endo-Surgery, Inc, Cincinnati, OH, USA), and LigaSure (Valleylab, Boulder, CO, USA), produce coagulation of liver tissue. They are not as useful as the ultrasonic dissector because the intrahepatic branches of the hepatic veins and portal structures could not be exposed clearly after liver coagulation. The clamp crushing technique has also been used for liver transection. It was shown in a prospective randomized trial that its efficacy is higher than the ultrasonic dissector.[9] However, its use needs inflow vascular occlusion and exposure of the MHV may not be satisfactory.

Inflow vascular occlusion or Pringle maneuver

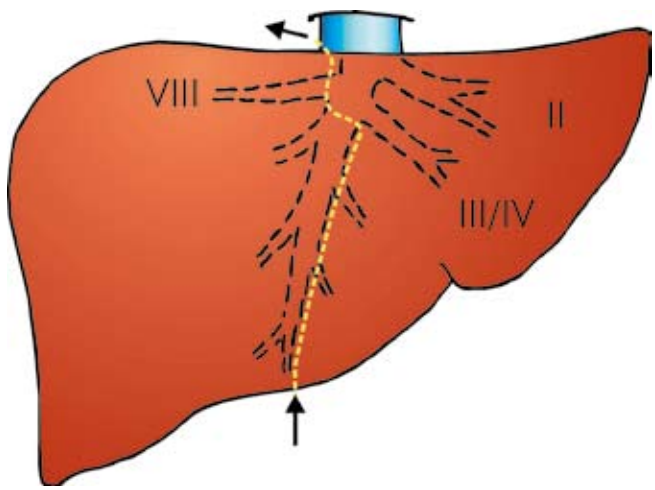

Figure 5.16. In case a large segment III/IV hepatic vein drains into the middle hepatic vein caudal to a large segment VIII hepatic vein, inclusion of the middle hepatic vein in the right liver graft is still possible. The dotted line shows the transection plane.

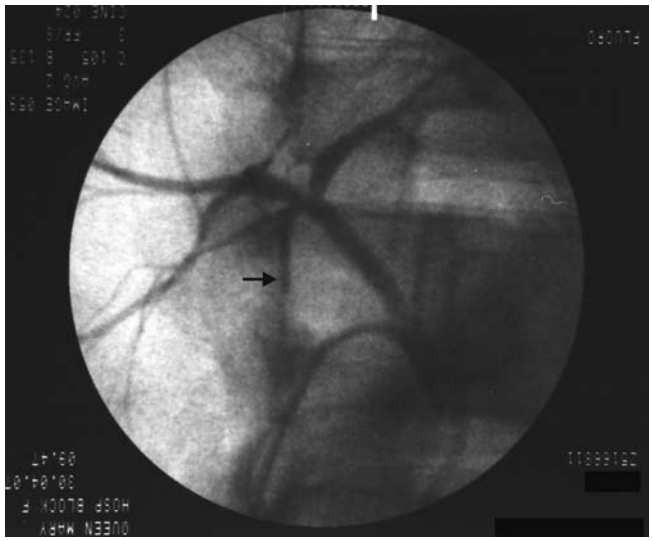

A



C

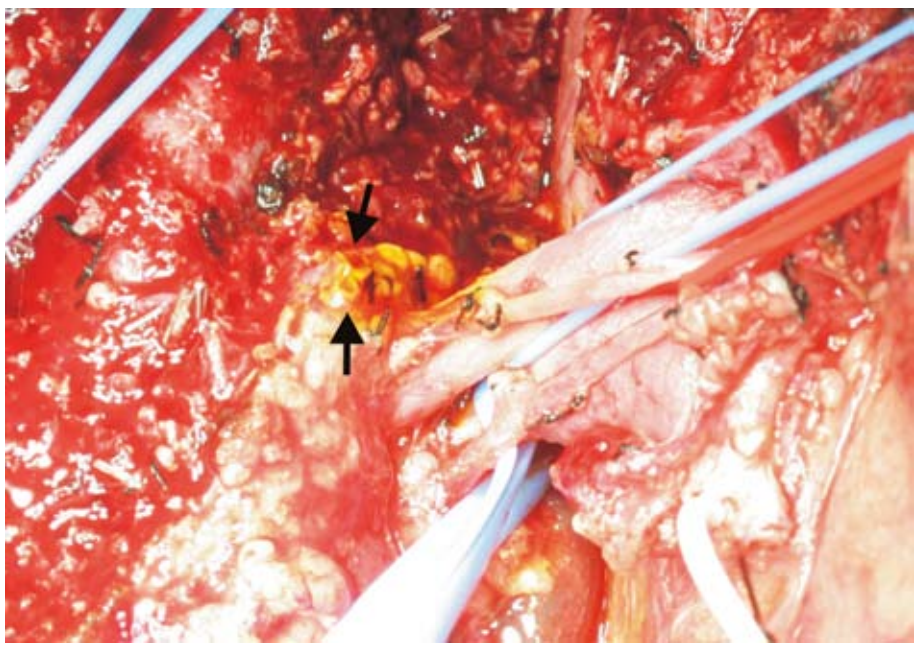

B

Figure 5.17A-C. A Liga clip (arrow) was placed at the proposed site of right hepatic duct division **(A)**; Cholangiogram was performed before duct division. Division at this point resulted in a single cuff right hepatic duct containing two orifices (arrows) **(B)**; Cholangiogram after closure of the right hepatic duct stump showed no narrowing of the confluence of the hepatic ducts **(C)**. Two ductal openings within a single cuff are obtained only if meticulous cholangiogram is performed.

is a standard procedure in liver transection. It was shown in a prospective randomized trial to be more efficient as compared to the cases operated without inflow vascular occlusion.[10] Pringle maneuver is also advocated to reduce bleeding volume in living donor hepatectomy.[11,12] However, prolonged inflow vascular occlusion is not without risk.[13] For donor hepatectomy, if the liver transection proceeds slowly and cautiously, the inflow occlusion time may exceed the accumulated time of 120 minutes, which is the upper limit before parenchymal damage appears.[13] To avoid hurrying with the transection, we do not employ Pringle maneuver. With cautious application of the ultrasonic dissector, it is possible to avoid excessive bleeding and inflow vascular occlusion. However, if major bleeding occurs during liver transection, there should not be any hesitation in applying inflow vascular occlusion. The major bleeding site during liver transection is usually from the MHV. After inflow vascular occlusion, the blood flow in the MHV is reduced and the bleeding site could be controlled precisely by suturing.

To reduce the bleeding rate from the MHV, adequate muscle relaxation and lowering the central venous pressure to less than 5 cmH_2O would be beneficial. However, cautious application of the ultrasonic dissector is the only answer to reducing the bleeding volume.

Retrieval of the right liver graft starts with clamping and division of the RHA. The graft side of the RHA is not clamped to avoid trauma to the vessel wall. The clamping on the RHA must be secure. A bulldog vascular clamp is not secure for the hepatic artery and slippage has been observed after division. Preferably, the RHA stump is ligated at this stage to avoid unnecessary blood

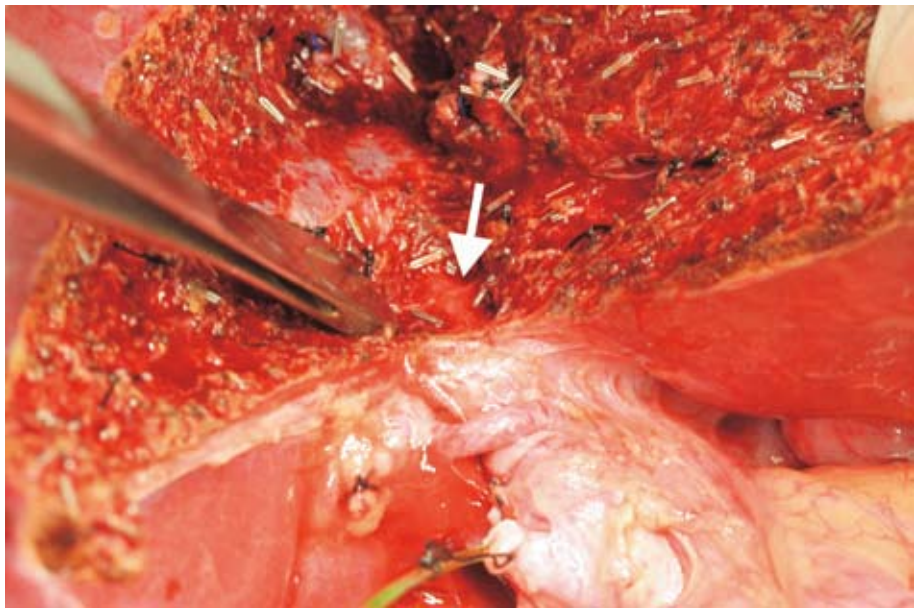

Figure 5.18. The transection was carried down to the level beyond the middle hepatic vein exposing the segment I portal pedicle (arrow). It should be ligated, divided and sutured to prevent bile leakage.

loss due to slippage of the clamp and to reduce the number of instruments inside the abdominal cavity which may interfere with the subsequent procedures. Then, the RPV is clamped vertically at the position that will not jeopardize the junction with the LPV. A bulldog vascular clamp is then applied on the graft side. The RPV is divided leaving a 1–2-mm cuff above the clamp. Next, the MHV is controlled by the vascular stapler [TA30, V3 (2.5 mm), United States Surgical, Norwalk, CT, USA]. The right liver is rotated toward the left side and the RHV is clamped by the vascular stapler. The inferior RHV, if present, is also controlled by the vascular clamp. Then the RHV (and inferior RHV if present) is divided allowing the blood in the liver graft to escape. Finally, the MHV is divided and the graft is delivered to a basin containing ice sludge. Local or systemic heparinization is not given.

The RPV stump is closed by running 6-0 prolene. The vascular clamp on the stump must not be released before knot tying is completed in order to avoid the purse-string effect. Doppler ultrasonography is then performed to ensure that the portal and arterial blood flow in the remnant liver is intact. The hepatic vein stumps are examined carefully because bleeding in between staples may occur, especially when the surrounding tissues are thick or Liga clips are caught in the suture line. Saline flushing of the liver transection surface will allow detection of minor bleeding sites. Hemostasis is accomplished by electrocautery, argon beam coagulation or suturing. Suturing is preferred but it is important to avoid a large-bite suture near the hepatic vein, because inadvertent inclusion of part of the hepatic vein in the suture may result in liver congestion and more bleeding from the liver transection surface. Argon beam coagulation is also effective, but it is important to avoid indiscriminate use near sutures as the intense heat may cause sloughing of the suture, leading to continuous bleeding. Hemostatic materials are also effective, but they are removed after hemostasis because foreign materials on the liver transection surface may predispose to infection. Fibrin glue spray on the liver transection surface must be avoided because it predisposes to infection and occasional case of acquired factor V deficiency.[14] Covering the liver transection site by the greater omentum has been advocated, but such practice predisposes to small bowel migration into the right subphrenic cavity and intesti-

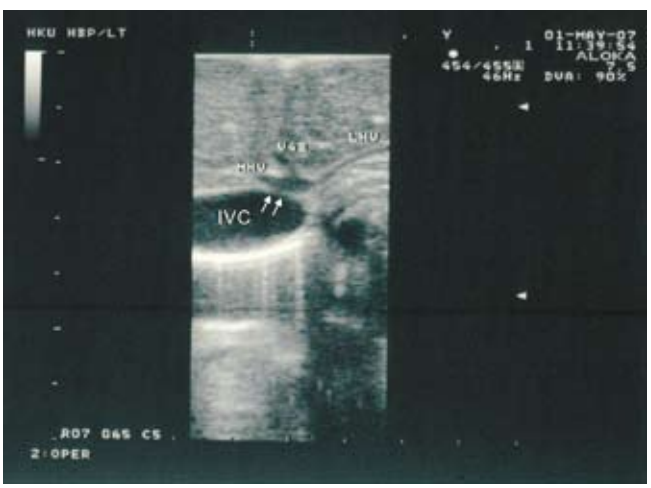

Figure 5.19. The tissue in between the middle hepatic vein (MHV) and inferior vena cava (IVC) (white arrows) needs to be removed before a sufficiently long MHV stump could be obtained.

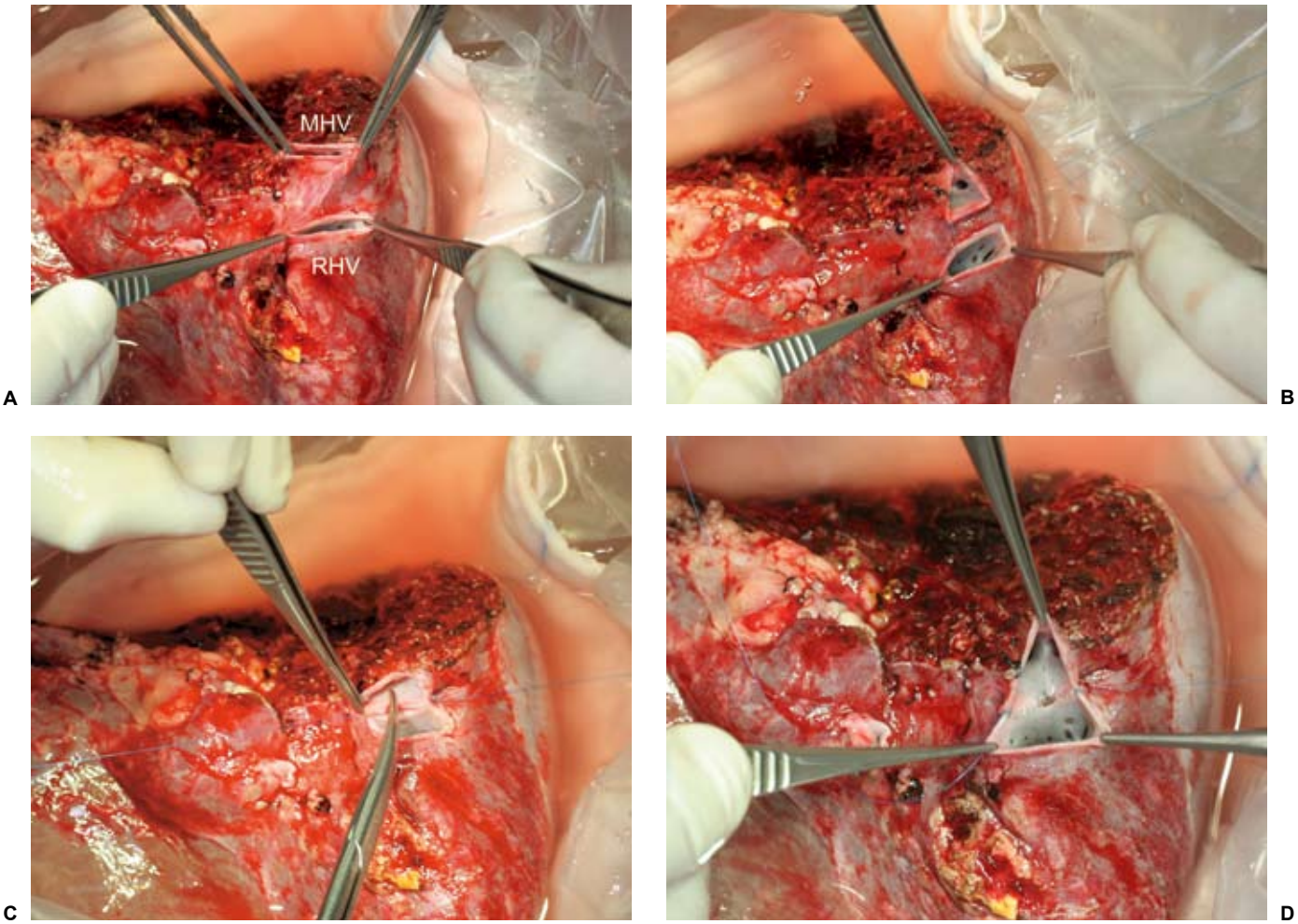

Figure 5.20. Venoplasty of the right hepatic vein (RHV) and middle hepatic vein (MHV) into a single and large triangular orifice.

nal obstruction. We prefer not to cover the liver transection surface by any material.

Saline or diluted methylene blue is instilled into the bile duct via the cystic duct cannula for detection of bile leakage. The common sites of bile leakage are the caudate process, hilar plate and liver transection surface. Compression onto the supraduodenal part of the common bile duct during saline or methylene blue instillation may enhance the detection rate of bile leakage. However, it is illogical to do so because the biliary tract is normally a low-pressure system. Artificially converting the biliary tract into a high-pressure system may produce leakage from needle holes or dislodgement of ligatures. After checking for bile leakage, the cystic duct cannula is removed and the cystic duct ligated by absorbable material proximal to the site of original ligature for the cannula. The falciform ligament is then sutured to the anterior abdominal wall to prevent the left liver from rotating into the right subphrenic cavity. It is wrong to use the left liver to fill the space in the right subphrenic cavity and prevent small bowel migration. Liver rotation will lead to twisting of the outflow, liver congestion, bleeding from the liver transection surface, and possibly liver failure.[15] In the normal situation, the hepatic flexure of the colon will rise to occupy the right subphrenic space. Small bowel migration may take place around the hepatic flexure of the colon. To prevent that from happening, apart from careful placement of the greater omentum over the small bowel, adequate muscle relaxation, positioning of the patient in an anti-Trendelenburg position, and rotation of the operation table slightly to the left side during closure of the right subcostal wound would be helpful. Another dose of antibiotic should be given at the time of wound closure to prevent wound infection.[16] Abdominal drain is not used.[17]

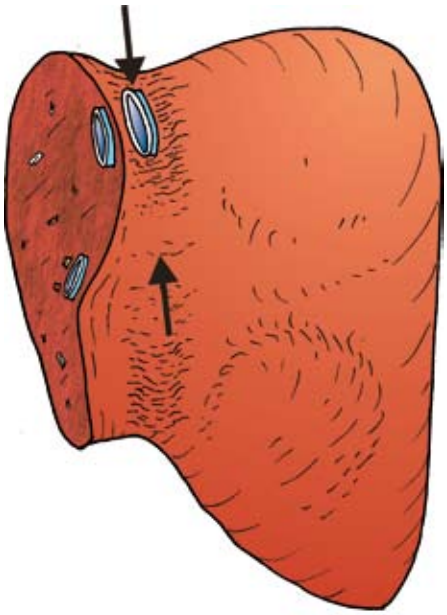

Figure 5.21. The base of the newly formed venoplasty opening should be along the direction of the inferior vena cava groove (arrows).

Backtable procedure

The right liver graft is flushed by 1.5–2 L of histidine-tryptophan-ketoglutarate (HTK) solution via the RPV.[18] To retain the length of the graft RPV for subsequent anastomosis, ligature is not applied to the RPV during cannulation and flushing. Simply pinching the vein against the catheter or pushing the tube gently into the lumen of the right anterior or posterior portal vein is efficient for complete flushing. The color of the liver should be inspected for regions that have not been completely cleared of blood. The hepatic artery is also flushed by about 10–20 mL of HTK solution with a fine catheter. The solution is preferably delivered by gravity to avoid intimal injury, which may lead to irreversible graft loss. Finally, the RHD is rinsed by HTK solution too. The graft is weighed. Venoplasty is then performed to bring the MHV and RHV together to form a common orifice.[19,20] Despite the distance of 2–2.5 cm between the MHV and RHV, the two venous openings could be brought together easily without much tension (Figure 5.20). After formation, the base and height of the triangle are measured and the information relayed to the recipient team. The base of the triangle is along the IVC groove (Figure 5.21), whereas the apex is at the highest point of the MHV.

The venoplasty is not confined to the MHV and RHV. Any exposed segment VIII and VII hepatic vein on the liver transection surface are easily incorporated into the venoplasty[21-23] (Figures 5.22–5.24). Similarly, two or three inferior RHV could be incorporated into a single orifice. Instead of venoplasty, Hwang et al[24] advocated stitching a piece of vein graft in between the RHV and MHV to reduce tension. This is a good alternative but the bench operation time is longer.

The liver graft is then put in a sterile plastic bag immersed in ice sludge in a basin. In case the recipient is not ready for graft implantation, the graft should be put into a box containing ice cubes in a similar manner as a deceased donor graft. As the graft is small-for-size, the cold ischemia duration has to be as short as possible to reduce the severity of ischemia-reperfusion injury. If the du-

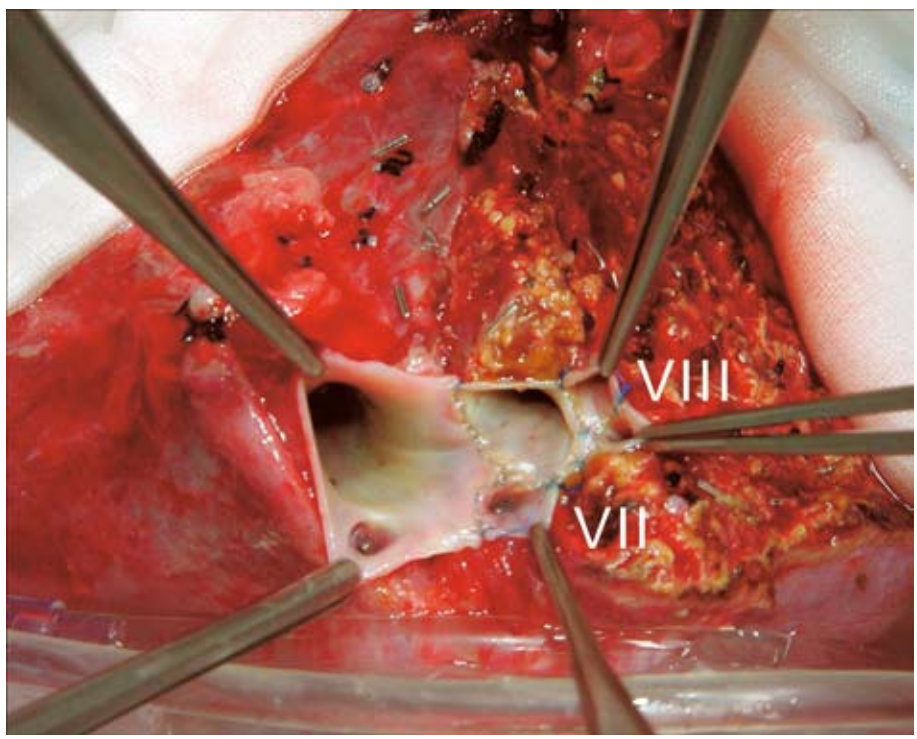

Figure 5.22. Venoplasty incorporating the right hepatic vein, middle hepatic vein, two segment VIII hepatic veins, and one segment VII hepatic vein.

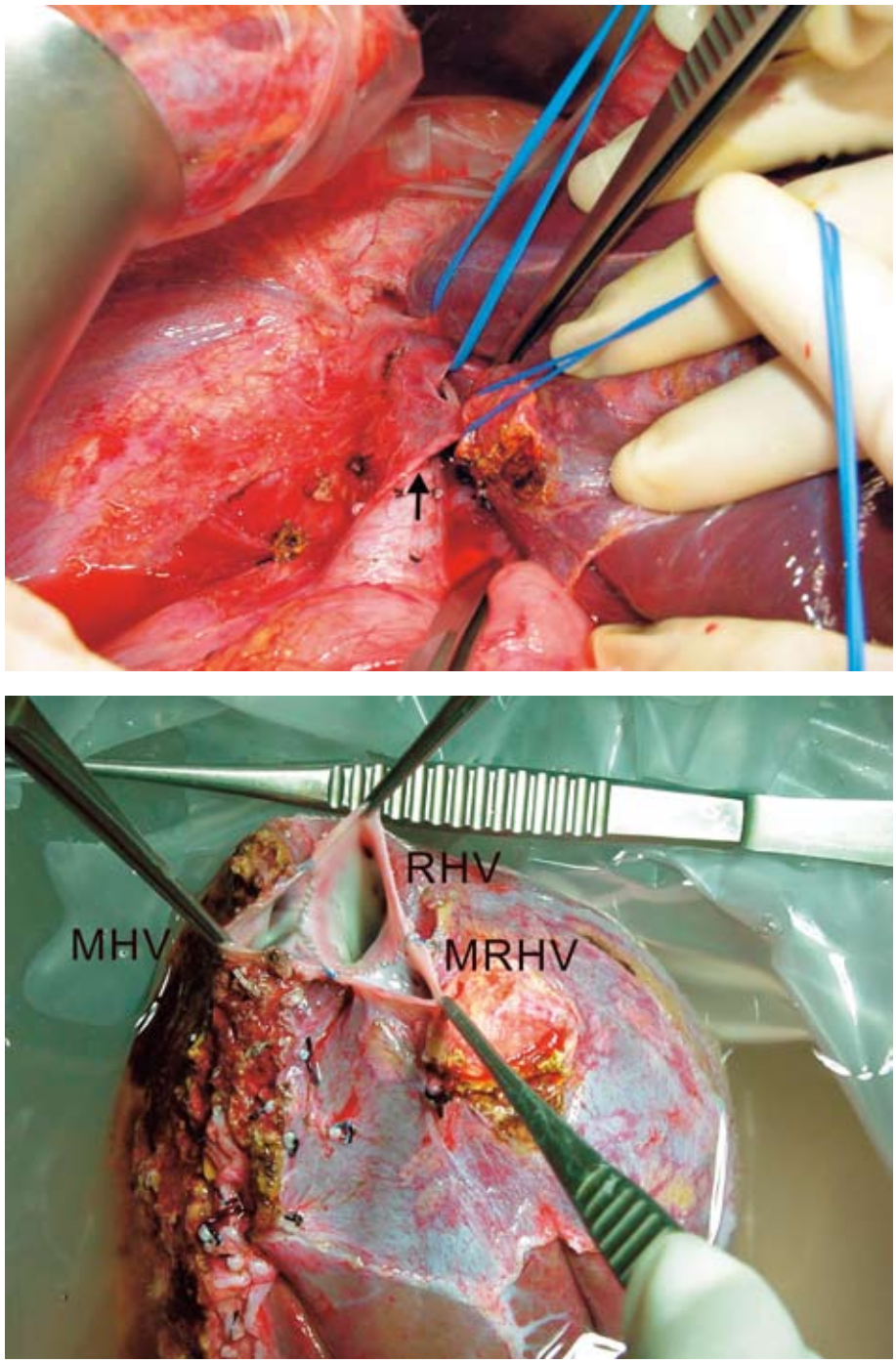

Figure 5.23A,B. Operative photo shows a large middle right hepatic vein (MRHV) (draining segment VII) (arrow) and a right hepatic vein (RHV) **(A)**; Venoplasty incorporating the RHV, MRHV, and middle hepatic vein (MHV) **(B)**.

ration is unexpectedly long, adequate protection from warming of the liver graft is mandatory.

Recipient operation

The recipient is prepared in the similar manner as the donor. Because veno-venous bypass is rarely employed today,[25] draping of the patient is confined to the abdomen and lower chest. Bilateral subcostal incision and upward midline incision is made. The xiphoid process is excised and the wound is exposed by the Bookwalter retractor (Codman and Shurtleff, Inc, Raynham, MA, USA). Hilar dissection is made to free the cystic duct which is cannulated for subsequent cholangiogram and bile leakage testing after the duct-to-duct anastomosis. Unlike deceased donor liver transplantation, hilar dissection is initiated near the hilar plate. The RHA is freed at the right liver hilum above the level of the transection of the common hepatic duct so as to protect the blood supply to the common hepatic duct from the RHA as it crosses in front of or behind the common hepatic duct (Figure 5.25). Next, the LHA is dissected free on the left side of the hepatoduodenal ligament. Sometimes, a left medial hepatic artery is also seen and preserved for use in case of need. During dissection of the hepatic arteries, all tiny branches are carefully ligated by 4-0 silk. If the ligation is not secure, bleeding underneath the ligature may spread retrogradely and cause intimal dissection of the hepatic artery. As in the donor operation, the hepatic artery should never be picked up at any time by the dissecting forceps.

The three branches of the hepatic artery are then each clamped by the Acland vascular clamp (S&T AG, Neuhausen, Switzerland) and divided near the hilar plate after application of a small right-angle clamp near to the hilar plate. Liga clips are not used

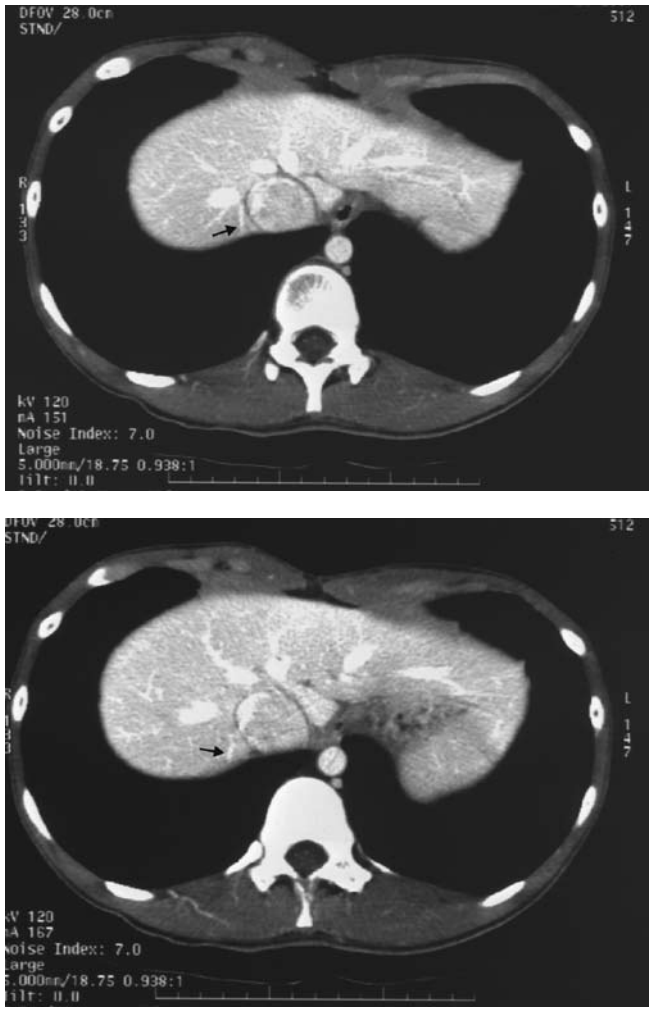

Figure 5.24. Computed tomography scans show the segment VII hepatic vein (arrow) adjacent to the right hepatic vein. This segment VII hepatic vein should be preserved and incorporated into the right hepatic vein if it is found to be separate from the right hepatic vein in the right liver graft.

because they may slip during subsequent hilar dissection. The hepatic artery stumps on the liver side are then ligated.

After division of the hepatic artery branches, the right or left side of the portal vein may be obvious. If not, dissection on both sides of the hepatoduodenal ligament is made until the portal vein is exposed. Then, dissection is kept close to the portal vein leaving all the tissues surrounding the common hepatic duct intact.

The common hepatic duct and the surrounding tissues are freed and transected as high as possible but not into the hilar plate, because a caudate hepatic duct may be included in the stump but missed and may be the cause of bile leakage afterward. An exceedingly long recipient common hepatic duct may also cause "crane-neck" deformity and biliary obstruction.[26] The liver side of the common hepatic duct is sutured, whereas the recipient side is left open. Bleeders from the hepatic duct wall and the peridochal tissues are sutured carefully by 6-0 prolene.

After division of the common hepatic duct, the RPV and LPV are freed by division of the caudate branches. Because, in the usual situation, the main portal vein (MPV) is used for anastomosis, further dissection for a long length of the RPV and LPV is not required except in the occasional case when a temporary porto-caval shunt is planned or the LPV is going to be used as a conduit for a short MHV in the right liver graft. The MPV is also freed caudally to obtain a sufficient length for application of a vascular clamp. Loose tissues behind the MPV are preferably ligated. The portal vein is not divided until mobilization of the liver is completed and the liver graft is available.

The caudate process is lifted up and the loose tissues overlying the IVC are divided. The caudate hepatic veins thus exposed are divided and sutured. The right liver is mobilized by division of the right triangular ligament and the adhesion with the right adrenal gland. The right IVC ligament is exposed, encircled, divided and sutured. The RHV is encircled and the space between the caudate lobe and anterior surface of the IVC is freed by dividing all tiny short hepatic veins. Next, the left liver is mobilized by dividing the lesser omentum and left triangular

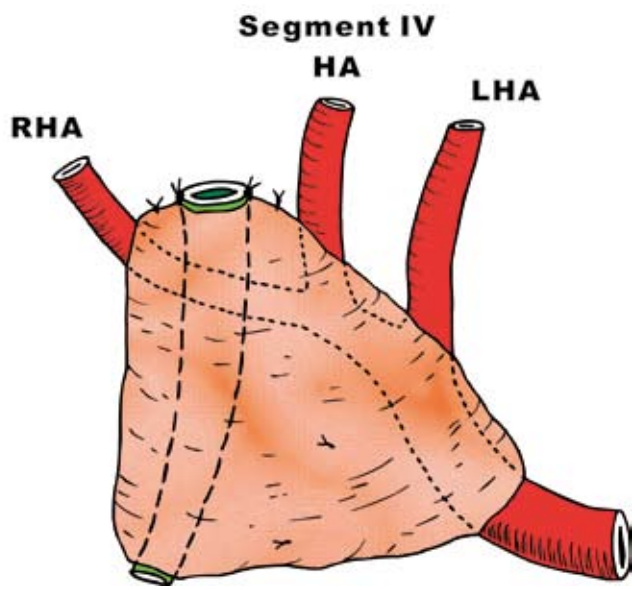

Figure 5.25. Preservation of blood supply to the common hepatic duct in the recipient. RHA, right hepatic artery; HA, hepatic artery; LHA, left hepatic artery.



Figure 5.26. Ulrich-Swiss clamp. A vascular clamp of similar configuration is preferred for control of the suprahepatic inferior vena cava in right liver living donor liver transplantation.

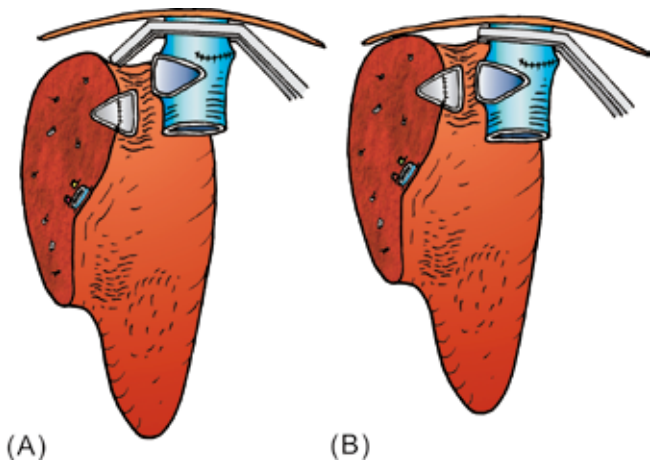

Figure 5.27. A Satinsky vascular clamp **(A)** is undesirable because the tip or the return jaw will interfere with the approximation of the hepatic vein orifices.

ligament. The left caudate lobe is then lifted off from the IVC by dividing the tiny hepatic veins and ductus venosum. Finally, the common trunk of the LHV and MHV is encircled.

Difficulty may be encountered on separating the caudate lobe from the IVC, especially when the entire liver or the caudate lobe is bulky or when there is previous operation or infection. Transection of the portal vein will facilitate the separation but should be deferred until the liver graft is available for implantation because prolonged clamping of the portal vein in the absence of veno-venous bypass will induce bowel congestion and bleeding from the transected hepatoduodenal ligament, and render the implantation difficult. An alternative is to ligate the RPV or LPV and divide the ipsilateral hepatic vein. Exposure of the IVC will then be much easier while the splanchnic circulation is not very congested.

In the usual situation, complete separation of the back of the liver from the IVC is possible and removal of the diseased liver begins only when the graft is available. The portal vein is controlled by the Blalock vascular clamp (Blalock Pulmonary Artery Clamp, Pilling Weck, Research Triangle Park, NC, USA) (Figure 4.7) and the RPV and LPV divided. The Blalock clamp is preferred for precise orientation. The RHV and the common trunk of the MHV and LHV are each controlled by a strong vascular clamp and divided. After delivery of the diseased liver, the LHV and MHV stump is sutured, whereas the clamp on the RHV is left intact. For hepatocellular carcinoma patients, the hepatic veins are controlled and divided by ATW35 (Ethicon Endo-Surgery, Inc, Cincinnati, OH, USA) to avoid cancer cells spilling into the peritoneal cavity.

The IVC is now mobilized, if not already done, by dividing the lumbar veins. Dissection by keeping to the IVC wall will facilitate speedy mobilization. The diaphragm is cleared from the suprahepatic IVC and the diaphragmatic veins may have to be divided and ligated. The infrahepatic IVC is taped and occluded using the Rummel tourniquet. If the patient could tolerate the IVC occlusion, then an Ulrich-Swiss clamp (Ulrich AG, St Gallen, Switzerland), which does not have a return jaw, is employed to occlude the suprahepatic IVC (Figure 5.26). On application of the clamp, the tip should not protrude

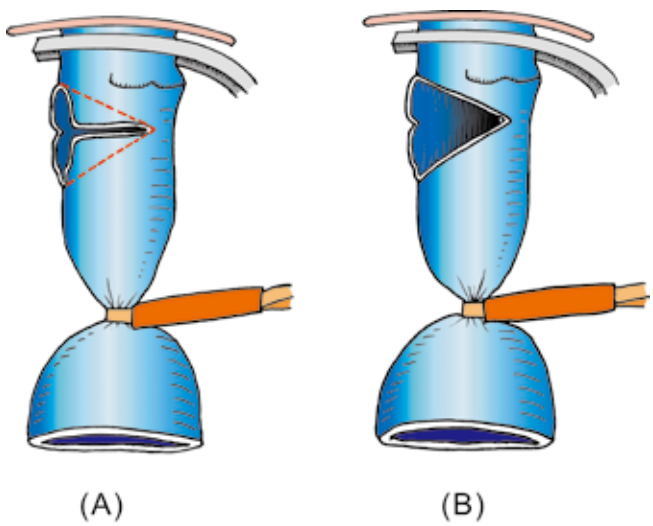

Figure 5.28. After control of the inferior vena cava, the right hepatic vein clamp is removed. The longitudinal and transverse cuts are made to form a large triangular opening with the size matching the donor venoplasty opening. The posterior wall of the right hepatic vein is also divided transversely to remove the possibility of formation of a ridge that may obstruct blood flow.



Figure 5.29A,B. Ultrasound picture of the right hepatic vein (RHV), middle hepatic vein (MHV) and inferior vena cava (IVC) after implantation of a right liver graft. The IVC anastomosis is wide but there is a ridge (arrow) at the edge of the RHV causing flow impedance **(A)**; The suspicion of flow impedance is confirmed by Doppler ultrasonography. The color signal at the outlet of the RHV is mixed, indicating much turbulence at that region, whereas the color signal in the MHV is uniform. The spectral wave form also lacks pulsatility **(B)**.

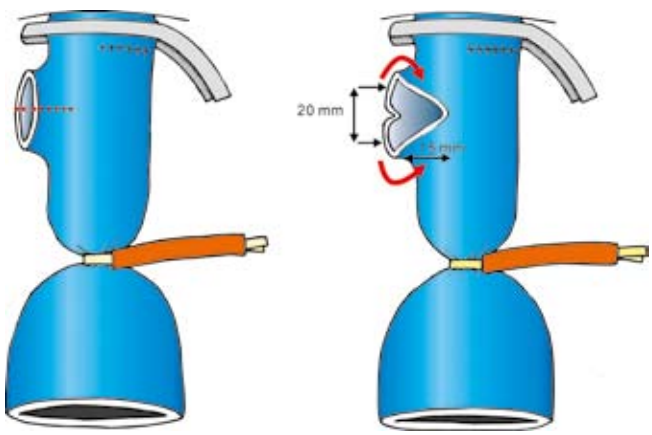

Figure 5.30. In case of a short middle hepatic vein in the graft, the recipient right hepatic vein is retained longer and the posterior wall is rotated to compensate for the discrepancy.

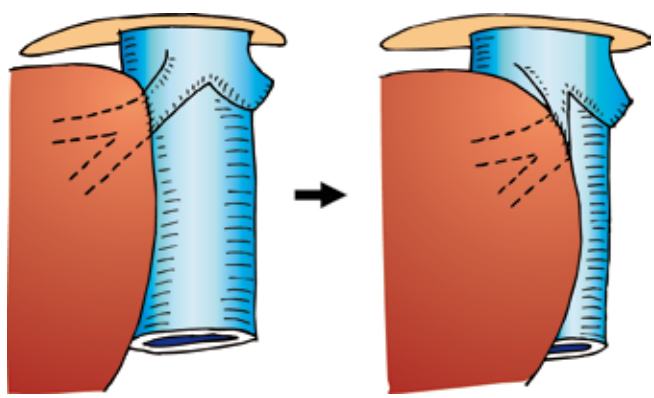

Figure 5.31. For the situation when the graft middle hepatic vein and recipient middle hepatic vein are anastomosed in an end-to-end fashion, expansion of the graft by hepatic artery reperfusion or regeneration may compress onto the middle hepatic vein causing outflow obstruction of segments V and VIII.

too much beyond the right side of the IVC. Otherwise, the protruded tip may interfere with the approximation of the hepatic vein orifice of the graft with the IVC. A Satinsky vascular clamp is definitely undesirable because the return jaw will interfere with the approximation of the hepatic vein orifices (Figure 5.27). The Rummel tourniquet is applied to the infrahepatic IVC because unlike a vascular clamp, it will not interfere with the right hand of the surgeon during suturing of the venous anastomosis.

After full control of the IVC, the RHV clamp is released and the lumen flushed clear of blood by heparin-saline. The longitudinal length of the RHV orifice is measured. If not long enough for the graft venoplasty opening, it is divided longitudinally in the caudal direction. If the posterior flap of the RHV is too broad, the flap is cut transversely so that a ridge will not form on completion of the anastomosis (Figures 5.28 and 5.29). The anterior wall of the IVC is divided transversely for such distance that matches that of the graft venoplasty opening. The two triangular flaps are excised to create a large triangular orifice that matches that of the venoplasty. The hepatic vein anastomosis is then completed by 5-0 prolene running sutures. In case the graft MHV is short, the posterior wall of the RHV of the recipient should be retained long and rotated to compensate for the discrepancy. Complete and circumferential mobilization of the IVC will also solve the problem and a vein graft may not be required (Figure 5.30). If the inferior RHV is present, it is anasto-

mosed to the right wall of the IVC after an appropriate size opening has been made. A diamond-shaped opening in the IVC wall is preferred.

In an early series of right liver living donor liver transplantation (LDLT), the RHV and MHV of the graft were anastomosed to the RHV and MHV of the recipient independently.[5,19] While the RHV anastomosis was normally free of problem, the MHV anastomosis was problematic, either at the time of implantation or thereafter. During implantation, the orientation of the MHV on the graft and recipient sides was difficult to judge. Not infrequently, twisting and folding occurred. The partial occlusion rate was 15% and complete occlusion rate was 3.5%. Occlusion of the MHV by compression might also occur when the graft expanded upon hepatic artery reperfusion or regeneration[19] (Figure 5.31). The RHV/MHV venoplasty technique can now eliminate all such problems.

On completion of all hepatic vein anastomoses, the graft RPV is picked up and occluded by a thin-blade or bulldog vascular clamp. The vascular clamp and tape controlling the IVC are released to allow restoration of blood flow in the IVC and reperfusion of the liver graft by backflow from the hepatic vein. Gradual rewarming of the graft will take place when portal vein anastomosis is carried out. Depending on the length of the graft RPV, anastomosis is performed to either the RPV or MPV of the recipient. To avoid redundancy, careful adjustment of the length of the portal vein on the recipient side is necessary (Figure 5.32A). We found anastomosis of the graft RPV to the recipient MPV feasible and desirable in most of the situations (Figure 5.32B). The resultant length is just appropriate. Normally, there is discrepancy in the diameter between the RPV of the graft and MPV of the recipient. Without closing part of the MPV, the RPV of the graft may be stretched and torn on pulling the corner stitches together. However, we found that the graft RPV can be safely stretched to about 1.25 times of its diameter. Fine 6-0 prolene needle is used to avoid tearing of the stretched RPV. It is important that the recipient MPV should not be closed partially to the same diameter as the donor RPV because the antero-posterior dimension of the recipient portal vein would be much narrowed and the resultant anastomosis smaller than expected.

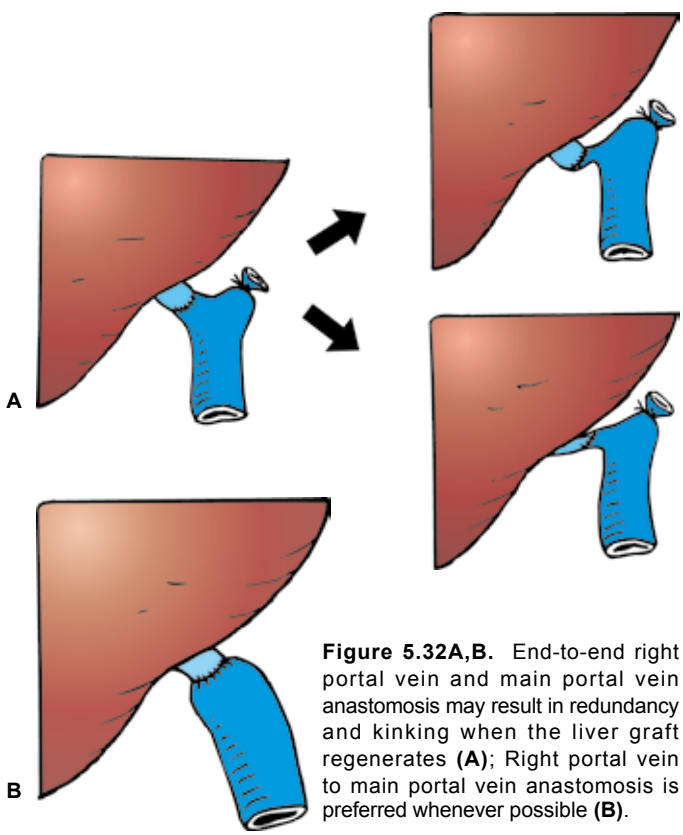

Figure 5.32A,B. End-to-end right portal vein and main portal vein anastomosis may result in redundancy and kinking when the liver graft regenerates **(A)**; Right portal vein to main portal vein anastomosis is preferred whenever possible **(B)**.

In the graft, sometimes the right anterior and posterior portal veins are separate (Figure 5.33A). Venoplasty of the two portal vein branches results in a single orifice, but the configuration is not favorable for the usual way of vein reconstruction (horizontal orientation, left to right) because the venoplasty site (horizontal axis) is usually the narrowest part (Figure 5.33B), whereas the antero-posterior dimension is the longest. To achieve a perfect anastomosis, the bulldog clamp is not applied to the graft portal vein, the corner stitches are applied to the vertical axis rather than the horizontal axis (Figure 5.33C). Right and left corner stitches are applied to the donor graft side to open up the orifice and for accurate placement of sutures. The right and left corner stitches are not applied to the recipient side, until the suturing approaches the right or left corner in order to avoid confusion and difficulty in placement of running suture.

In case the right anterior and posterior portal veins are separate for a long distance, it would be necessary to perform separate anastomoses to the recipient RPV and LPV.

Portal vein thrombosis in the recipient before transplant poses a difficult problem. Thrombectomy by the eversion technique is usually successful for most cases, but thrombosis extending into the su-



A

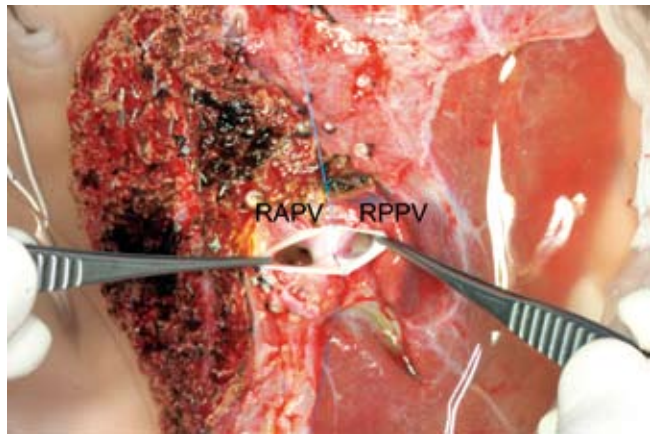

B

Figure 5.33A-C. Computed tomography scan shows separate right anterior and posterior portal veins **(A)**; After venoplasty, the right anterior portal vein (RAPV) orifice is on top of the right posterior portal vein (RPPV). The horizontal or transverse diameter of the venoplasty is shorter than the vertical diameter. Such configuration is not favorable for the usual method of portal vein reconstruction **(B)**; To secure a wide anastomosis, modification of the suturing method is needed. As shown here, the anterior and posterior corner stitches are applied first to both sides. The right and left corner stitches are applied to the graft side only to avoid confusion. In effect, suturing is performed on four sides rather than two sides **(C)**.

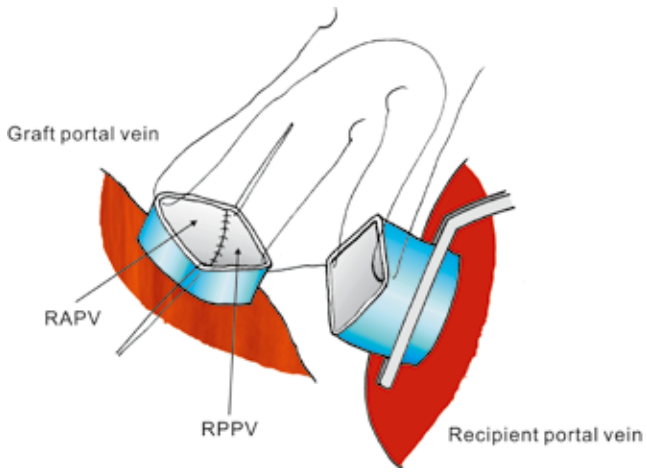

C

perior mesenteric vein may require an interposition vein graft or porto-caval transposition.[27]

After reperfusion of the graft, bleeding sites are controlled by suturing. Pulsatility of the MHV seen on the liver transection surface indicates patency of the venous anastomosis. Patency of the hepatic vein anastomosis is also ascertained on ultrasonography. If an anastomosis of approximately the same size as the hepatic vein orifice is seen, one can assume that a perfect anastomosis has been made (Figure 5.34). Presence of gas and suture may, however, affect such assessment. Color flow signal across the anastomosis would be a better indication (Figure 5.35). A more important criterion of full patency is the triphasic pulsatility spectral waveform.[28] Presence of triphasic pulsatility waveform and reverse flow indicate anastomosis patency and soft graft consistency, respectively. If the MHV is patent, there is minimum bleeding on the liver transection surface. Using the Doppler signal, one may define partial occlusion as low flow rate with absence of pulsatility in the spectral waveform and complete occlusion as absent flow signal. When such abnormalities are detected, re-doing of the anastomosis should be considered.

Hepatic artery anastomosis is performed under the operating microscope at a magnification of ×10 to ×15. An alternative to the operating microscope is the head-mounted surgical binocular system, which allows magnification up to ×7.2.[29] The choice of the recipient RHA or LHA depends on the orientation, diameter, length and patency. Intimal dissection is occasionally induced during the hilar dissection. The alternative to the RHA and LHA is the gastroduodenal artery, gastroepiploic artery,[30] interpositional vein graft, or radial artery.[31] The recipient and donor hepatic arteries are approximated by a paired Acland microvascular clamp.[32] The microvascular anastomosis is performed with interrupted 9-0 nylon monofilament sutures (Ethilon, Ethicon, Inc, Somerville, NJ, USA) on a 9-0 gauge micropoint needle. The first suture is placed at 0° and the second stay suture at 160°. In this way, the posterior wall of the



Figure 5.34. Doppler ultrasonography with a probe placed over the transection surface of the liver and inferior vena cava (IVC) showing the lumen of anastomosis of the common hepatic vein orifice with the IVC.

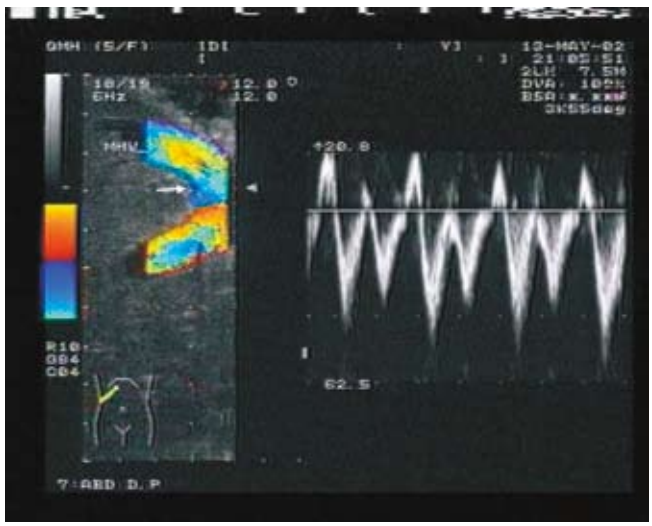

Figure 5.35. Doppler ultrasonography with a probe placed over the transection surface of the right liver graft showing the middle and right hepatic veins and the inferior vena cava. A large opening is obvious and the septum (arrow) is also seen several millimeters away from the inferior vena cava. Excellent pulsatility in the spectral waveform and backflow are observed in the spectral tracing of the middle hepatic vein (MHV), indicating that the anastomosis is completely patent and the graft is soft in consistency.

two vessel ends would fall away from the anterior walls and thus reduce the chance of inadvertently catching the posterior walls while stitches are inserted on the anterior walls. After completing the anterior wall, the paired vascular clamp is turned over and stitching on the posterior wall is performed. On completion, Doppler ultrasonography is again performed. Using the microvascular surgery technique, the overall complication rate is 2%.

Biliary reconstruction is by duct-to-duct anastomosis as the first choice using 6-0 PDS sutures (continuous in the posterior wall, interrupted in the anterior wall) without a stent or T-tube (Chapter 7). If gallstone is present in the gallbladder or suspected to be present inside the common bile duct, choledochoscopic examination would be necessary to exclude common bile duct stones. Cholangiogram via the cystic duct cannula can be performed for baseline study of the anastomosis. Diluted methylene blue could also be instilled into the biliary tract for detection of bile leakage. In case of presence of two ductal orifices in the graft that could not be brought together by ductoplasty, hepatico-jejunostomy is performed, again without an internal or external stent. After hemostasis, the abdominal wound is closed. Abdominal drain is not necessary unless a large amount of ascites is expected.

Postoperative care

The donor deserves meticulous attention because his/her liver function is transiently impaired. The median peak INR value of a right liver donor without the MHV is about 1.4 in the early postoperative period and it appears at about 36 hours after the operation. In some donors, the INR may increase to 2.0 or 2.2. Such a phenomenon, though transient, does indicate that the donor is at risk of liver failure if proper care is not given.

The donor is nursed in the intensive care unit and monitored for physiological changes on the first postoperative day. Oxygen is given via the nasal cannula. Fluid administration is restricted unless he/she is obviously under-loaded. Elevated central venous pressure is undesirable as it will impede venous return of the small liver remnant and predispose to impaired liver function. Antibiotic is given for three more doses and proton pump inhibitor is routinely given for 6 weeks. Adequate pain relief is provided by morphine or its derivative. Nausea and vomiting are frequent problems. Adequate anti-emetic is provided to eradicate the donor's ill-feeling toward the operation. Breathing exercise by incentive spirometry is mandatory for prevention of chest infection and speedy recovery. Since the donor is vulnerable to infection, the central venous catheter and urinary catheter are removed as soon as possible.

The recipient is nursed in the intensive care unit. He/she is sedated and ventilated until the hemodynamic status is stable, the respiratory effort is judged adequate and liver function satisfactory. The pulmonary artery catheter is removed as soon as possible unless the hemodynamic status is unsatisfactory. The central venous catheter is also removed afterward to reduce the risk of central venous catheter infection. Intravenous fluid administration is totally withheld unless there is obvious fluid deficit because fluid retention before and during the operation is usual. The only fluid inputs are inotropes (if needed), insulin infusion, antibiotic solution, and concentrated albumin solution. Fresh frozen plasma is not given routinely unless the INR is more than 2.5. A low platelet count is expected and no replacement is needed unless interventional procedure is planned. Blood transfusion is avoided unless the hemoglobin level decreases to less than 7 gm/dL. The blood glucose level is maintained at 6–8 mmol/L to reduce the risk of postoperative infection.[33] Because abdominal drain is not placed in the majority of recipients, fluid and protein loss is not a concern. However, there could be ascites leaking through the abdominal wound in the later period. By then, accurate fluid balance calculation may be difficult. Judicious administration of intravenous fluid and concentrated albumin solution is needed. Depending on the microbiology culture result before the operation, the type and duration of antibiotic administration vary. Occult infection could be the cause of deterioration of liver function and renal failure. Empirical use or change of antibiotic is required before bacterial or fungal culture result is available.

Infectious complication is not infrequent in LDLT. The site of infection could be the chest, urinary tract, abdomen and intravenous or arterial lines. For intra-abdominal infection, the likely sources are the ascites, liver transection surface (as a result of necrosis), liver hilum (due to bile leakage), or perihepatic hematoma. Prompt laparotomy is required if the suspicion of intra-abdominal infection is strong.

Because the lumen of the hepatic artery anastomosis is much smaller than that of deceased donor liver transplantation, regular (daily) Doppler ultrasonography is required for early detection of hepatic artery thrombosis. Regular Doppler study may detect early cases of hepatic artery thrombosis and render salvage possible.[34] In case of excessive ascites, attention must be paid to the patency of the hepatic vein and portal vein anastomosis during Doppler study.

Early resumption of enteral feeding is required for liver regeneration stimulation and prevention of bacterial translocation. However, failure of return of gastrointestinal function usually implies abdominal sepsis or impaired liver function. Prompt investigations are needed to identify the cause of delayed gastric emptying and ileus.

Transient renal function impairment is frequently observed. Hemodialysis or continuous veno-venous hemofiltration is needed as indicated. Use of nephrotoxic agents, including calcineurin inhibitor, must be reduced or avoided before full recovery of renal function. In case of liver and kidney dysfunction, technical errors and infection must be excluded. Molecular Adsorbent Recirculation System treatment may be considered as a means to prepare the patient for re-transplantation or expedite spontaneous recovery.[35]

References

1. Niemann CU, Feiner J, Behrends M, Eilers H, Ascher NL, Roberts JP. Central venous pressure monitoring during living right donor hepatectomy. Liver Transpl 2007; 13: 266-271.
2. Lutz JT, Valentin-Gamazo C, Gorlinger K, Malago M, Peters J. Blood-transfusion requirements and blood salvage in donors undergoing right hepatectomy for living related liver transplantation. Anesth Analg 2003; 96: 351-355.
3. Hashimoto T, Kokudo N, Orii R, Seyama Y, Sano K, Imamura H, Sugawara Y, Hasegawa K, Makuuchi M. Intraoperative blood salvage during liver resection: a randomized controlled trial. Ann Surg 2007; 245: 686-691.
4. Fan ST, Lo CM, Liu CL, Tso WK, Wong J. Biliary reconstruction and complications of right lobe live donor liver transplantation. Ann Surg 2002; 236: 676-683.
5. Fan ST, Lo CM, Liu CL. Technical refinement in adult-to-adult living donor liver transplantation using right lobe graft. Ann Surg 2000; 231: 126-131.
6. Fan ST, Lo CM, Liu CL, Wang WX, Wong J. Safety and necessity of including the middle hepatic vein in the right lobe graft in adult-to-adult live donor liver transplantation. Ann Surg 2003; 238: 137-148.
7. Kasahara M, Takada Y, Fujimoto Y, Ogura Y, Ogawa K, Uryuhara K, Yonekawa Y, Ueda M, Egawa H, Tanaka K. Impact of right lobe with middle hepatic vein graft in living-donor liver transplantation. Am J Transplant 2005; 5: 1339-1346.
8. Belghiti J, Guevara OA, Noun R, Saldinger PF, Kianmanesh R. Liver hanging maneuver: a safe approach to right hepatectomy without liver mobilization. J Am Coll Surg 2001; 193: 109-111.
9. Takayama T, Makuuchi M, Kubota K, Harihara Y, Hui AM, Sano K, Ijichi M, Hasegawa K. Randomized comparison of ultrasonic vs clamp transection of the liver. Arch Surg 2001; 136: 922-928.

10. Man K, Fan ST, Ng IO, Lo CM, Liu CL, Wong J. Prospective evaluation of Pringle maneuver in hepatectomy for liver tumors by a randomized study. Ann Surg 1997; 226: 704-711.
11. Imamura H, Takayama T, Sugawara Y, Kokudo N, Aoki T, Kaneko J, Matsuyama Y, Sano K, Maema A, Makuuchi M. Pringle's manoeuvre in living donors. Lancet 2002; 360: 2049-2050.
12. Miller CM, Masetti M, Cautero N, DiBenedetto F, Lauro A, Romano A, Quintini C, Siniscalchi A, Begliomini B, Pinna AD. Intermittent inflow occlusion in living liver donors: impact on safety and remnant function. Liver Transpl 2004; 10: 244-247.
13. Man K, Fan ST, Ng IO, Lo CM, Liu CL, Yu WC, Wong J. Tolerance of the liver to intermittent pringle maneuver in hepatectomy for liver tumors. Arch Surg 1999; 134: 533-539.
14. Cheng VCC, Yuen KY, Ma ESK. Unusual cause of bleeding tendency in a postoperative patient. HKABTH Newsletter 2000; 7: 5-8.
15. Poon RT, Chan J, Fan ST. Left hepatic vein kinking after right trisegmentectomy: a potential cause of postoperative liver failure. Hepatogastroenterology 1998; 45: 508-509.
16. Haley RW, Culver DH, Morgan WM, White JW, Emori TG, Hooton TM. Identifying patients at high risk of surgical wound infection. A simple multivariate index of patient susceptibility and wound contamination. Am J Epidemiol 1985; 121: 206-215.
17. Liu CL, Fan ST, Lo CM, Chan SC, Yong BH, Wong J. Safety of donor right hepatectomy without abdominal drainage: a prospective evaluation in 100 consecutive liver donors. Liver Transpl 2005; 11: 314-319.
18. Chan SC, Liu CL, Lo CM, Fan ST. Applicability of histidine-tryptophan-ketoglutarate solution in right lobe adult-to-adult live donor liver transplantation. Liver Transpl 2004; 10: 1415-1421.
19. Liu CL, Zhao Y, Lo CM, Fan ST. Hepatic venoplasty in right lobe live donor liver transplantation. Liver Transpl 2003; 9: 1265-1272.
20. Lo CM, Fan ST, Liu CL, Wong J. Hepatic venoplasty in living-donor liver transplantation using right lobe graft with middle hepatic vein. Transplantation 2003; 75: 358-360.
21. Chan SC, Lo CM, Liu CL, Wong Y, Fan ST. Versatility and viability of hepatic venoplasty in live donor liver transplantation using the right lobe with the middle hepatic vein. HBP Dis Int 2005; 4: 618-621.
22. Concejero A, Chen CL, Wang CC, Wang SH, Lin CC, Liu YW, Yang CH, Yong CC, Lin TS, Ibrahim S, Jawan B, Cheng YF, Huang TL. Donor graft outflow venoplasty in living donor liver transplantation. Liver Transpl 2006; 12: 264-268.
23. Kinkhabwala MM, Guarrera JV, Leno R, Brown RS, Prowda J, Kapur S, Emond JC. Outflow reconstruction in right hepatic live donor liver transplantation. Surgery 2003; 133: 243-250.
24. Hwang S, Lee SG, Ahn CS, Moon DB, Kim KH, Ha TY, Song GW. Outflow vein reconstruction of extended right lobe graft using quilt venoplasty technique. Liver Transpl 2006; 12: 156-158.
25. Fan ST, Yong BH, Lo CM, Liu CL, Wong J. Right lobe living donor liver transplantation with or without venovenous bypass. Br J Surg 2003; 90: 48-56.
26. Yoshimoto T, Yazumi S, Hisatsune H, Egawa H, Maetani Y, Chiba T. Crane-neck deformity after right lobe living donor liver transplantation. Gastrointest Endosc 2006; 64: 271.
27. Egawa H, Tanaka K, Kasahara M, Takada Y, Oike F, Ogawa K, Sakamoto S, Kozaki K, Taira K, Ito T. Single center experience of 39 patients with preoperative portal vein thrombosis among 404 adult living donor liver transplantations. Liver Transpl 2006; 12: 1512-1518.
28. Egawa H, Inomata Y, Uemoto S, Asonuma K, Kiuchi T, Okajima H, Yamaoka Y, Tanaka K. Hepatic vein reconstruction in 152 living-related donor liver transplantation patients. Surgery 1997; 121: 250-257.
29. Ohdan H, Tashiro H, Ishiyama K, Ide K, Shishida M, Irei T, Ohira M, Tahara H, Itamoto T, Asahara T. Microsurgical hepatic artery reconstruction during living-donor liver transplantation by using head-mounted surgical binocular system. Transpl Int 2007; 20: 970-973.
30. Tannuri U, Maksoud-Filho JG, Silva MM, Suzuki L, Santos MM, Gibelli NE, Ayoub AA, Velhote MC, Pinho-Apezzato ML, Maksoud JG. An alternative method of arterial reconstruction in pediatric living donor liver transplantation with the recipient right gastroepiploic artery. Pediatr Transplant 2006; 10: 101-104.
31. Kamei H, Fujimoto Y, Yamamoto H, Nagai S, Kamei Y, Kiuchi T. The use of radial artery interpositional graft between recipient splenic artery and graft artery in living donor liver transplantation. Transpl Int 2006; 19: 945-946.
32. Wei WI, Lam LK, Ng RW, Liu CL, Lo CM, Fan ST, Wong J. Microvascular reconstruction of the hepatic artery in live donor liver transplantation: experience across a decade. Arch Surg 2004; 139: 304-307.
33. Blondet JJ, Beilman GJ. Glycemic control and prevention of perioperative infection. Curr Opin Crit Care 2007; 13: 421-427.
34. Sakamoto Y, Harihara Y, Nakatsuka T, Kawarasaki H, Takayama T, Kubota K, Kimura W, Kita Y, Tanaka H, Ito M, Hashizume K, Makuuchi M. Rescue of liver grafts from hepatic artery occlusion in living-related liver transplantation. Br J Surg 1999; 86: 886-889.
35. Chiu A, Chan LMY, Fan ST. Molecular adsorbent recirculating system treatment for patients with liver failure: the Hong Kong experience. Liver Int 2006; 26: 695-702.

6. The middle hepatic vein controversy

Introduction

The middle hepatic vein (MHV) lies in between the right and left livers. Anatomically, it does not belong to either side of the liver. Ever since the inception of living donor liver transplantation (LDLT) for adults, it is arguable whether the MHV should be included in the liver graft or retained in the donor. For right liver donor operation, we have included the MHV in all of the right liver grafts except one because we considered that the MHV is an important venous drainage of the right anterior sector (Figure 6.1). However, others consider that sacrifice of the MHV in the left liver remnant is dangerous to the donor and inclusion of the MHV in the right liver graft is not always necessary for recipient survival. For left liver donor operation for adults, the MHV is always included in the left liver graft, but it generates much less discussion because it is assumed that the function of the right anterior sector in the donor, though impaired, will be compensated by the right posterior sector, which is larger than the segment II/III, and even with segment IV combined together. Despite serious congestion of the right anterior sector after left liver graft harvesting (Figure 6.2), the magnitude of the problem of sacrifice of the MHV in the left liver donor is considered not as serious as in the right liver donor. The discussion in this chapter will focus on that of the right liver graft.

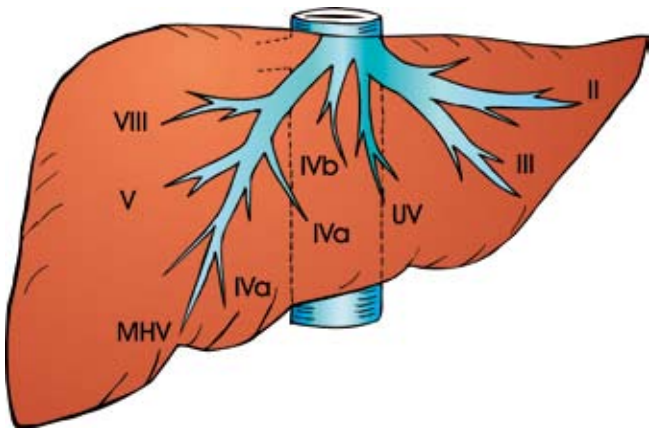

Figure 6.1. Schematic diagram shows the venous drainage pattern by the middle hepatic vein (MHV), umbilical vein (UV), and left hepatic vein.

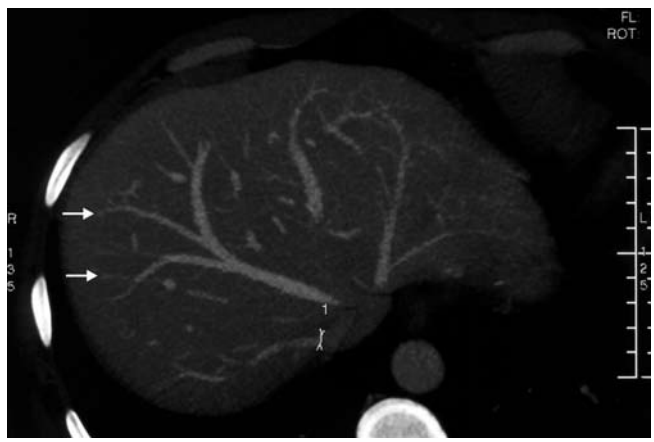

A

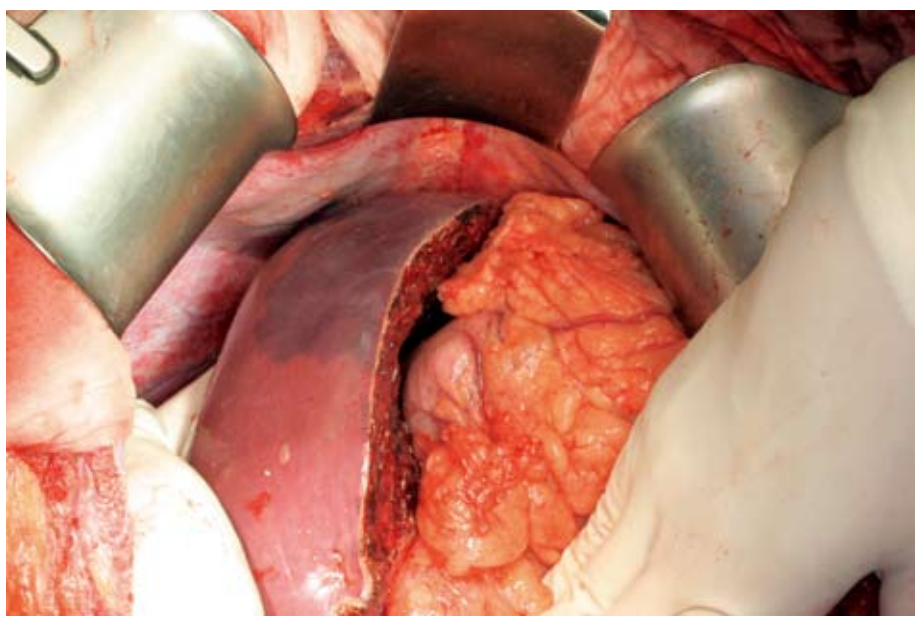

B

Figure 6.2A,B. Computed tomography scan of a left liver donor. There were two major segment VIII hepatic veins draining into the middle hepatic vein (arrows) **(A)**; The segment VIII was dusky after the left liver graft (including the middle hepatic vein) had been removed **(B)**.

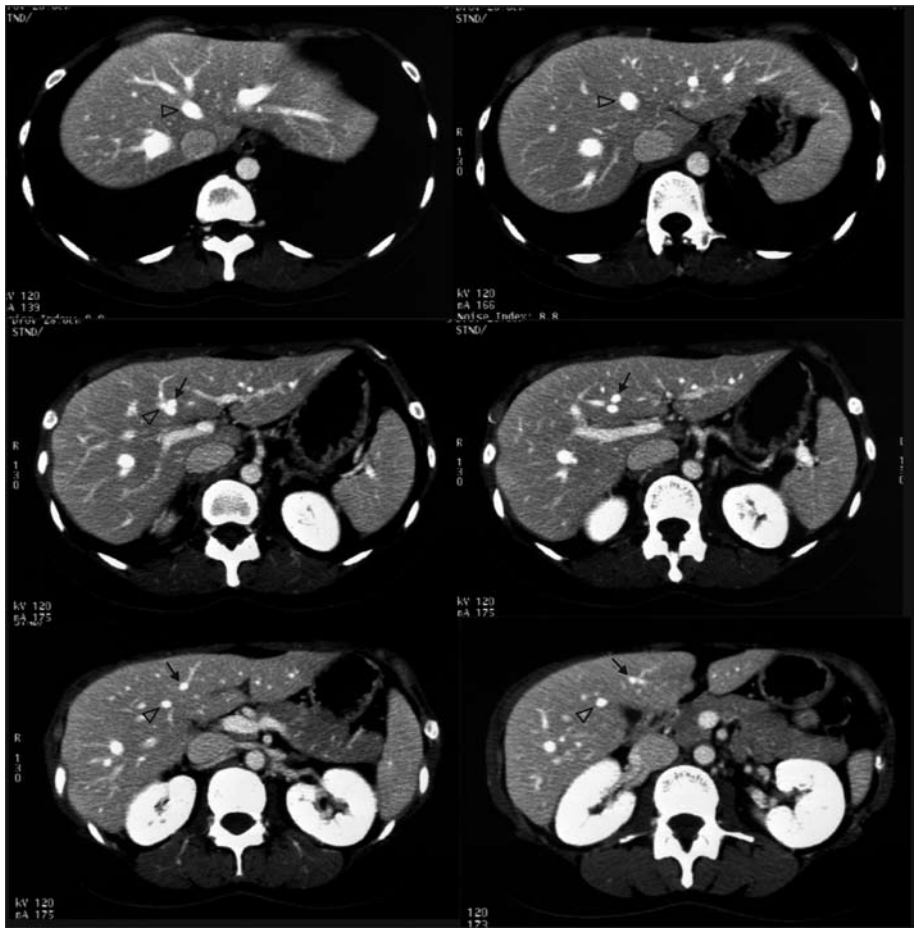

Figure 6.3. The middle hepatic vein (▷) shown on the computed tomography scan could be traced to originate near the gallbladder fossa. The segment IVa hepatic vein (arrow) joins the main trunk near to the right portal vein or liver hilum. In this donor, the right branch (or main trunk, draining segment V) was about the same size as the left branch (draining segment IVa).

Anatomy of the MHV

The main trunk of the MHV lies in the midplane (Cantlie line) of the liver. Distally or caudally, the MHV originates near the gallbladder fossa in between segments IV and V (69%)[1] (Figure 6.3). However, on many occasions, the main trunk of the MHV could be traced to originate in segment V (29%) (Figure 6.4), and even from segment VI (2%) (Figure 6.5).[1-3] Rarely, the MHV is duplicated, with a right trunk draining segment V/VIII and a left trunk draining segment IV, each joining the inferior vena cava (IVC) or left hepatic vein (LHV) separately.[4] More frequently, the so-called "right branch" (draining segment V) and the "left branch" (draining segment IVa) join near the right liver hilum to form a main trunk (Figure 6.3). However, there are also situations that the right and left trunks join at a deeper level (Figure 6.6).

The MHV is an important drainage of the right liver. On computed tomography (CT) scan, the MHV is of the same size as the right hepatic vein (RHV) in 43% of cases and is bigger than the RHV in 14% of cases (Figure 2.2).[1,5] Along the course, the MHV may receive about 15 tributaries from segment V, and about 18 tributaries from segment VIII on the right side,[6] and probably similar numbers from segments IVa and IVb on the left side. Such tributaries are large and obvious on ultrasonography and CT scan. However, there are numerous tiny branches in addition to the major tributaries, emptying into the MHV (Figure 6.7). They are not readily seen on CT scan, but the blood flow volume from these tiny branches could be substantial. The segment VIII hepatic vein is usually a large trunk and joins the MHV at varying positions. Occasionally, it joins the IVC independently of the MHV. On the left side, the segment IVa and IVb hepatic veins join the MHV also at variable positions and the number of branches varies.

Venous drainage of segment IV

The venous drainage of segment IVb (cranial portion) is mainly into the MHV and LHV. There may be more than one segment IVb hepatic vein draining into the MHV, IVC directly, or LHV. According to Nakamura,[7] there are three distinct patterns. Type I drainage is mainly via the LHV (57.5%); type II drainage is equally into the MHV and LHV (36.7%) (Figure 6.8); and type III drainage is predominantly into the MHV (5.8%). An umbilical vein that is in the same plane as the falciform ligament is present in 51%–76% of cases

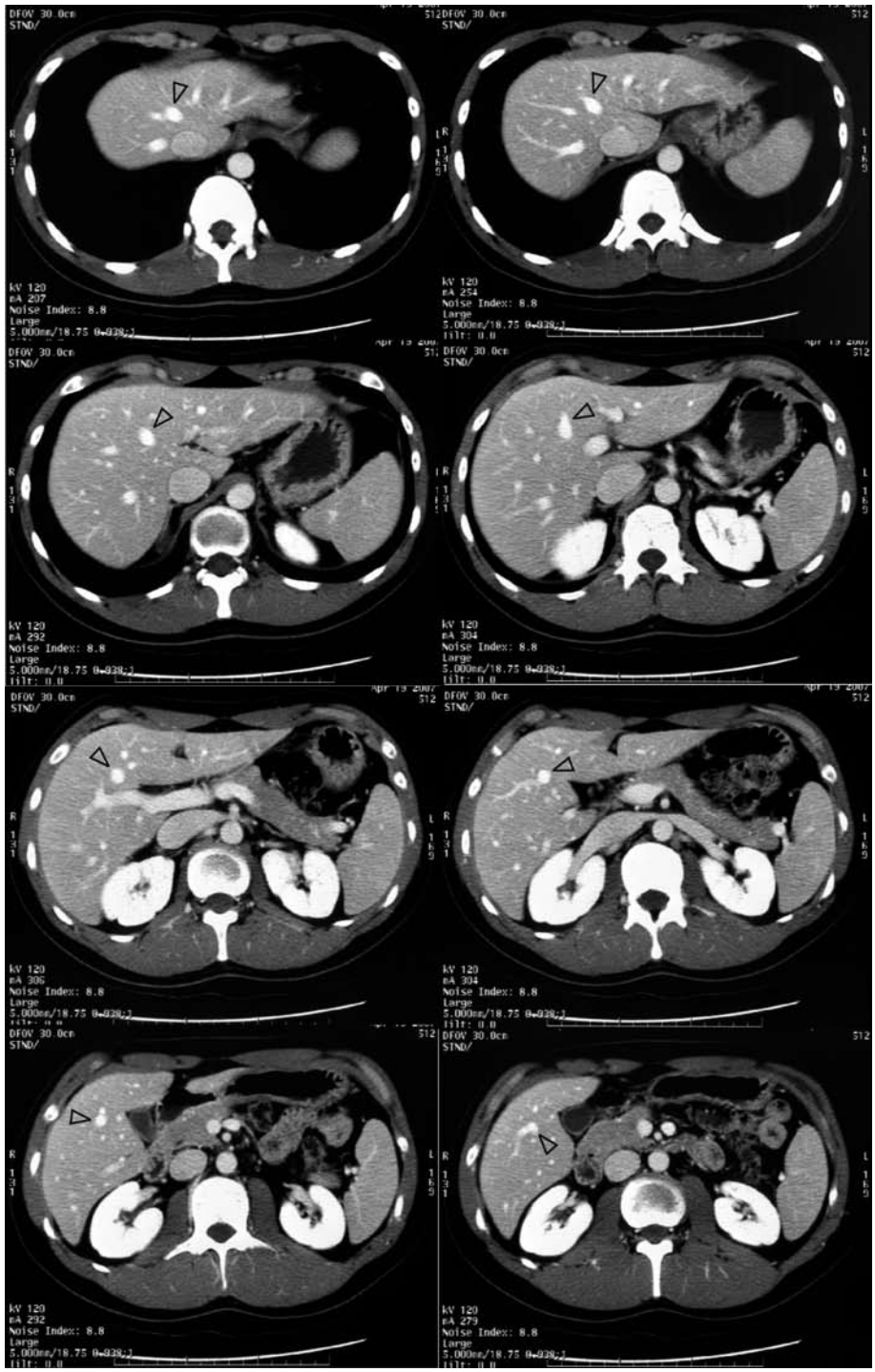

Figure 6.4. Computed tomography scan shows the origin of the middle hepatic vein (▷) in segment V.

(Figure 6.9).[1,4,8] It serves to drain the left portion of segment IV. Occasionally, a large trunk of the segment III hepatic vein drains the segment IV (Figure 6.10). Recognition of this anomaly is important to avoid mistaking it as the segment IVb hepatic vein because its sacrifice will lead to subsequent liver failure.

Disadvantages of not including the MHV in the right liver graft

Surgeons who do not advocate inclusion of the MHV in the right liver graft believe that communications exist between the MHV and RHV (Figure 6.11) and therefore the incidence of graft congestion should be negligible. Such connections occur on the liver surface[4] or within the liver parenchyma and could be seen under Doppler ultrasonography or three-dimensional graphic images created from the CT.[9,10] The incidence of intrahepatic venous collaterals between the RHV and MHV is estimated to be 24%.[11] Even though such collaterals are present, they are small and do not form a large trunk immediately after occlusion of the MHV. According to Kaneko et al,[12] a flow signal in the segment V/VIII hepatic vein of a right liver graft without the MHV is obvious only on postoperative day 6 after implantation, and intrahepatic venous anastomosis may not form uniformly in every graft. It occurs in the right liver graft by the end of the first week in segment VIII in 72% of cases and in segment V in 27% of cases only.[6] By magnetic resonance imaging or CT scan, venous congestion of segment V/VIII in the right liver graft without the MHV occurs in 85%–88% of patients.[13,14] The immediate consequence of venous congestion in segment V/VIII of the right liver graft after implantation is impaired liver function[15] and impaired regeneration,[16] but graft swelling leading to graft rupture[17,18] and subcapsular hematoma[19,20] have been

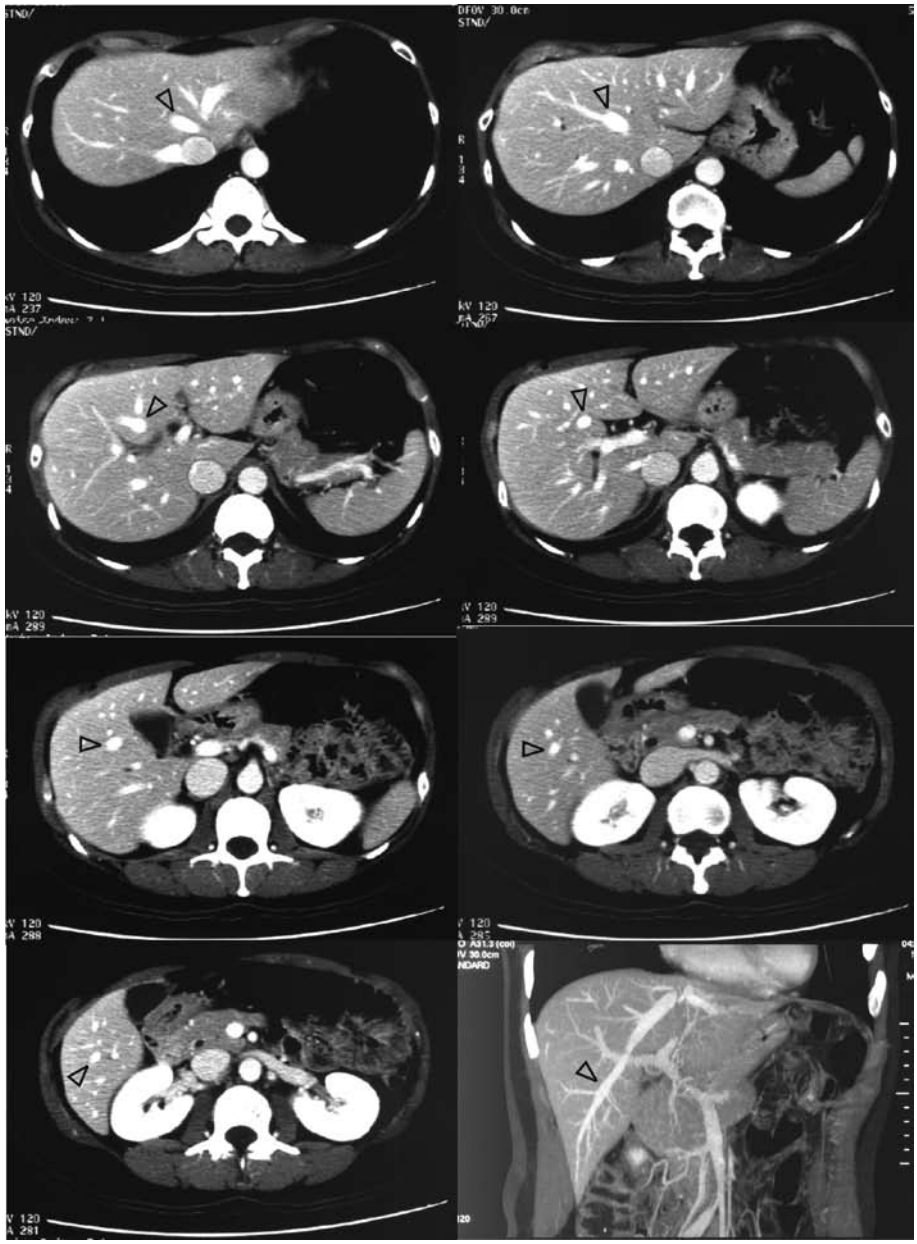

Figure 6.5. Computed tomography scan shows the origin of the middle hepatic vein (▷) in segment VI.

reported. In many cases, the graft is not so swollen after portal vein reperfusion, but a dusky area in segment V/VIII may be present. The graft becomes swollen upon hepatic artery reperfusion. At the same time, the dusky segment V/VIII disappears (Figure 6.12). The phenomenon is easily explained. On portal vein reperfusion, the segment V/VIII is not perfused because venous outflow is obstructed. On hepatic artery reperfusion, the segment V/VIII is perfused by higher arterial blood pressure, but in the presence of outflow occlusion, the arterial blood drains back into the systemic circulation via the right anterior portal vein and then the right posterior portal vein. In such situation, the portal vein pressure increases (and therefore defeats the original purpose of liver transplantation). More importantly, the right posterior sector accommodates all portal and arterial blood, leading to a situation that the right posterior sector sustains hyperdynamic injury, a situation similar to small-for-size graft injury (Figure 6.13). Thus, right liver graft without the MHV does not function perfectly. However, if the graft size is large or obtained from a young donor,[21] if the segment V/VIII is relatively small, and if the patient is not seriously ill and preoperative portal hypertension is not excessive, the aforementioned ill effect is not serious and the patient survives as the anastomosis between the RHV and MHV becomes enlarged and the right posterior sector undergoes hypertrophy.[21] On the other hand, if the patient has acute-on-chronic liver failure (United Network for Organ Sharing status IIA), the initial graft function may not be sufficient to meet the high metabolic demand and the patient mortality rate will be very high.[22-26] It is generally agreed that a Child-Pugh A liver function patient can tolerate or accept a graft without the MHV well.[27] It is also suggested that a patient with a Model for End-stage Liver Disease (MELD) score less than 15 may accept a right liver graft without the MHV.[28] However, the exact cutoff value of graft size and pre-implantation portal pressure that can obviate graft loss is not known. In our series with the MHV included in the right liver graft routinely, even patients with cirrhosis complicated by sepsis and acute deterioration (and very high MELD scores) have survived the operation

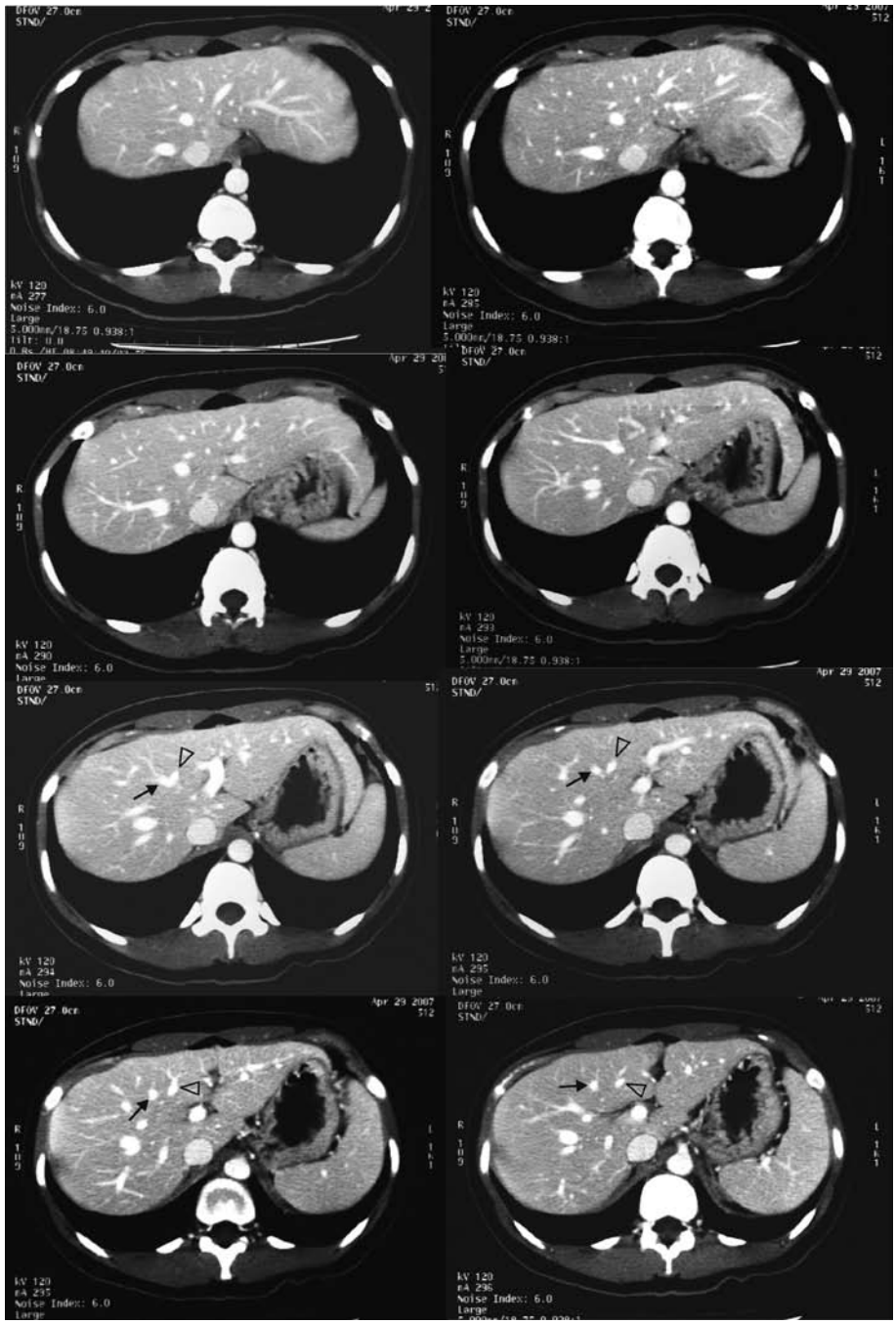

Figure 6.6. Computed tomography scan shows that the middle hepatic vein is formed by fusion of the segment IV (▷) and segment V (arrow) trunks, which are about the same size. The fusion of segment IV and segment V hepatic veins is more cranial than usual.

(Table 6.1 and Figure 6.14). The hospital mortality and long-term survival rates of these patients are comparable with those of patients having whole-graft deceased donor liver transplantation and those with cirrhosis undergoing elective LDLT (Table 6.1 and Figure 6.15). The additional advantage of using a right liver graft including the MHV is the wide applicability because it could be used in almost all anatomical situations and the lower limit of graft weight/estimated standard liver volume ratio could be reduced to 35%.[29] On the other hand, for a right liver graft without the MHV, the graft could not be used if the MHV is dominant in the venous drainage, because even when the intrahepatic anastomosis between the RHV and MHV could develop in time, the venous outflow via the small RHV could not accommodate the large blood flow volume. Thus, careful scrutiny of the venous anatomy is mandatory if a right liver graft without the MHV is chosen.[5]

Donor risk

Without the MHV in the remnant liver, the donor may have suboptimal liver function. In terms of serum total bilirubin levels, donors without the MHV have higher serum total bilirubin levels in the first postoperative week compared with donors without sacrifice of the MHV[1,30-32] (Figure 6.16). However, toward the end of the first postoperative week, the serum total bilirubin level is virtually the same irrespective of whether they have retention of the MHV or not. In terms of serum aspartate aminotransferase (AST) levels, donors with sacrifice of the MHV do not have higher serum AST levels than those with retention of the MHV (Figure 6.17). From a single center study,[33] comparison of donors with or without the MHV sacrifice showed no difference in the peak serum total bilirubin, AST, alanine aminotransferase levels, and the international normalized ratio (INR) in the postoperative period, and time taken for normalization of serum bilirubin and INR. In addition,

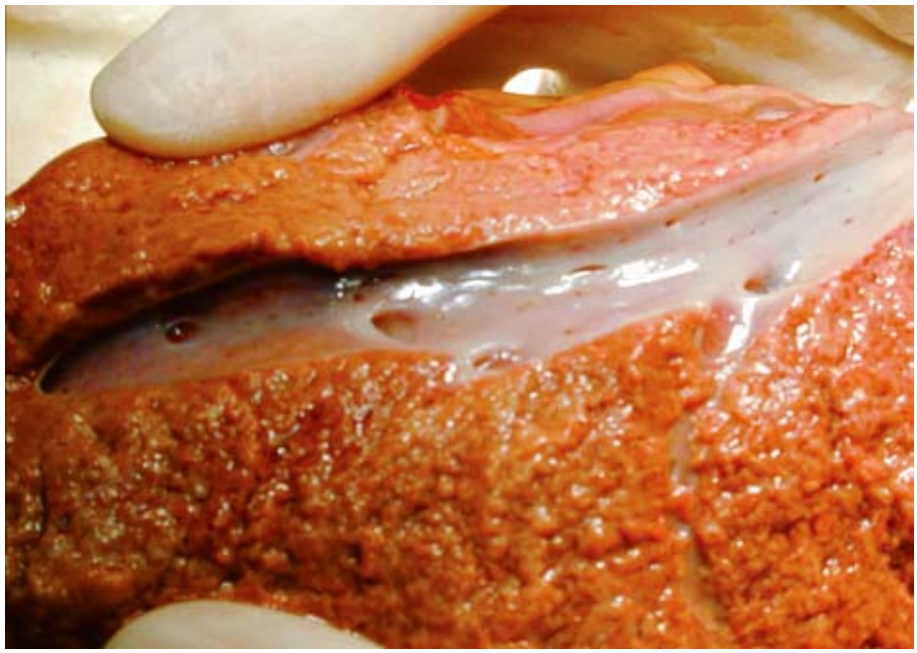

Figure 6.7. Postmortem specimen. The liver was divided at the midplane exposing the middle hepatic vein. In addition to obvious openings of hepatic vein branches, there are numerous tiny hepatic veins going into the lumen of the middle hepatic vein.

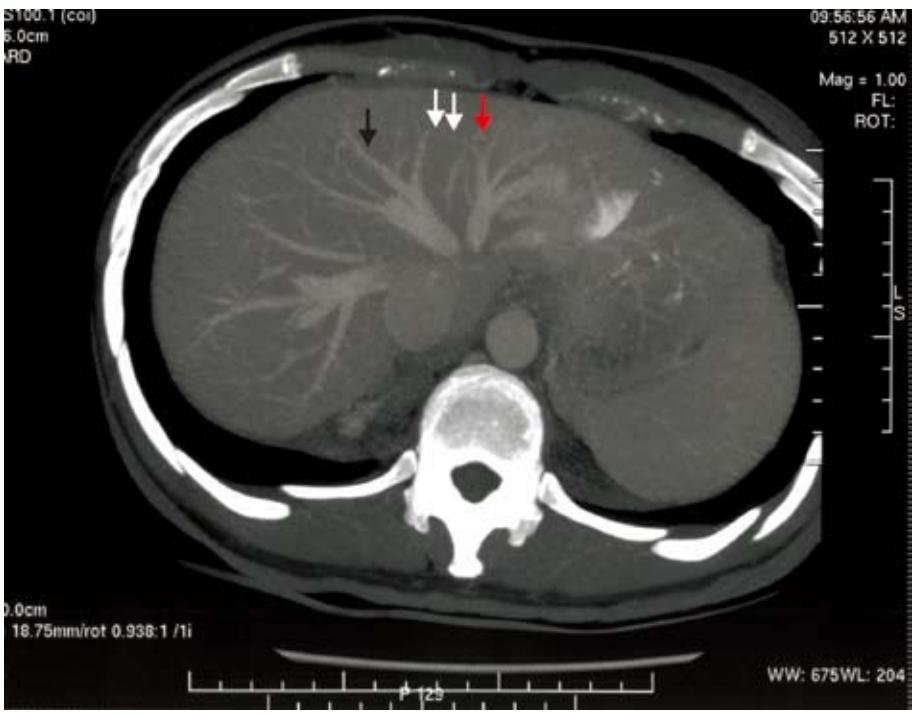

Figure 6.8. A large segment IVb hepatic vein (black arrow) drains into the middle hepatic vein. A large umbilical vein (red arrow) is also present and drains into the left hepatic vein. The venous drainage pattern is Nakamura type II. In this donor, the segment IVb hepatic vein was divided, but segment IV congestion was not noted. Venous drainage of segment IV was maintained likely because there was sufficient drainage via the left hepatic vein and there appeared to be communication between the branches of segment IVb hepatic vein and umbilical vein (white arrows).

Cattral et al[33] showed that inclusion of the MHV in the right liver graft did not incur additional blood loss or a higher postoperative complication rate. In another study by Scatton et al,[34] donors without the MHV in the liver remnant had longer prothrombin time in the early postoperative period, but there was no significant difference of the serum bilirubin levels between donors with or without the MHV in the left liver remnant. Their studies also showed that the left liver regeneration attained the same rate whether the MHV was present in the liver remnant or not. A similar report was made by Cho et al[35] and Chen et al.[36] However, segment IV when deprived of the MHV did have less liver regeneration, but not totally absent after right hepatectomy. The relative lack of liver regeneration in segment IV was compensated by the more rapid regeneration of segments I, II and III.[37] In essence, sacrifice of the MHV in the donor is relatively safe.

Without MHV drainage in the left liver remnant,

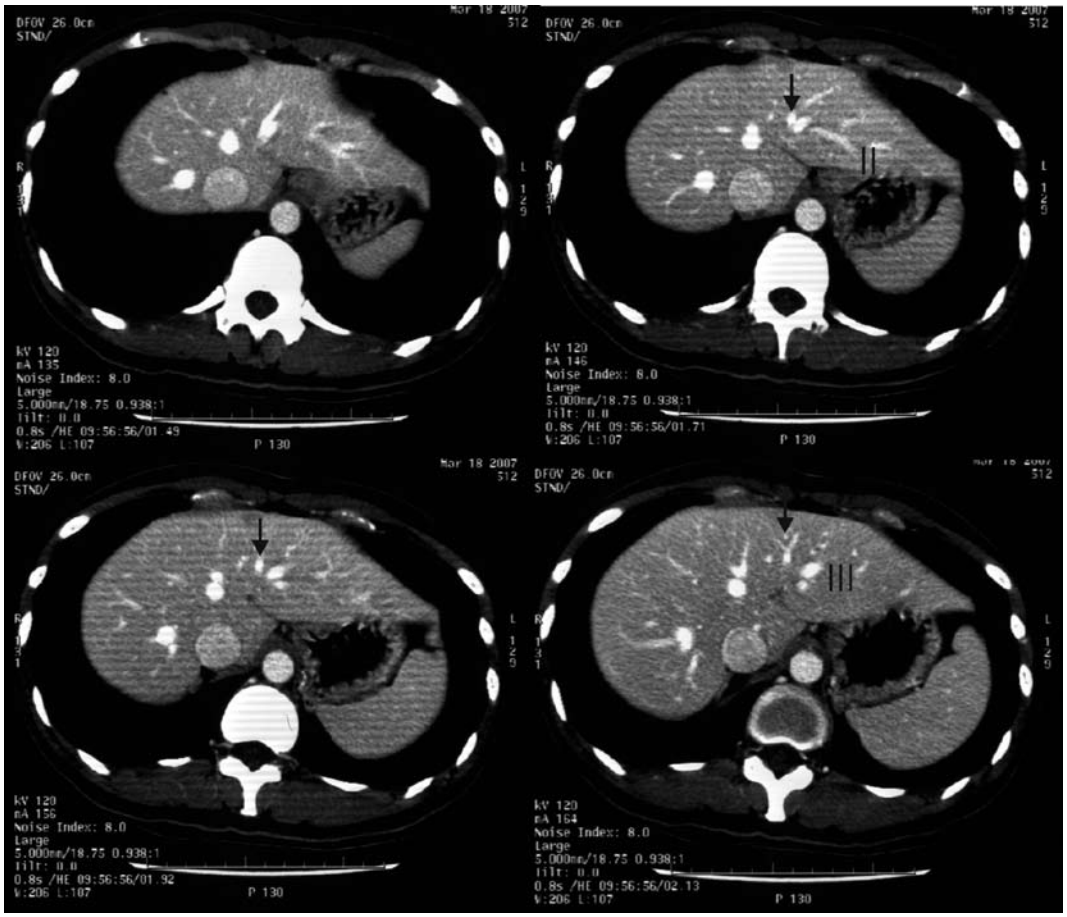

Figure 6.9. Computed tomography scan shows the presence of an umbilical vein (arrow). It runs a separate course from the segment II and III hepatic veins.



Figure 6.10. Computed tomography scan shows the middle hepatic vein with a major segment VIII branch joining from the right side and a large segment III hepatic vein joining from the left (▷). The segment III hepatic vein is recognized as it crosses to the left side of the umbilical fissure. This vein also drains segment IV. The middle hepatic vein is divided proximal to the segment III hepatic vein to preserve the integrity of the segment II/III remnant. Asterisk indicates the segment VIII hepatic vein.

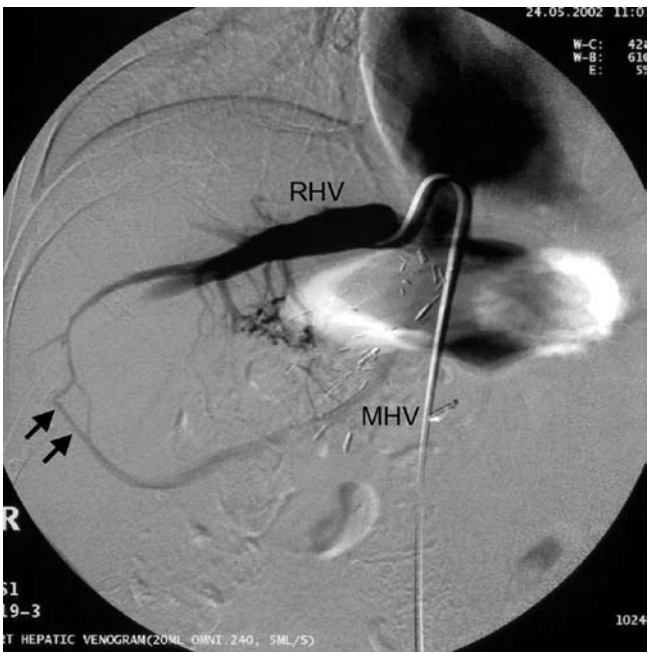

Figure 6.11. Venogram shows intrahepatic venous collaterals (arrows) developed after occlusion of the middle hepatic vein (MHV) in a right liver graft including the MHV. The collateral is sizeable but not as large as the MHV itself. RHV, right hepatic vein.

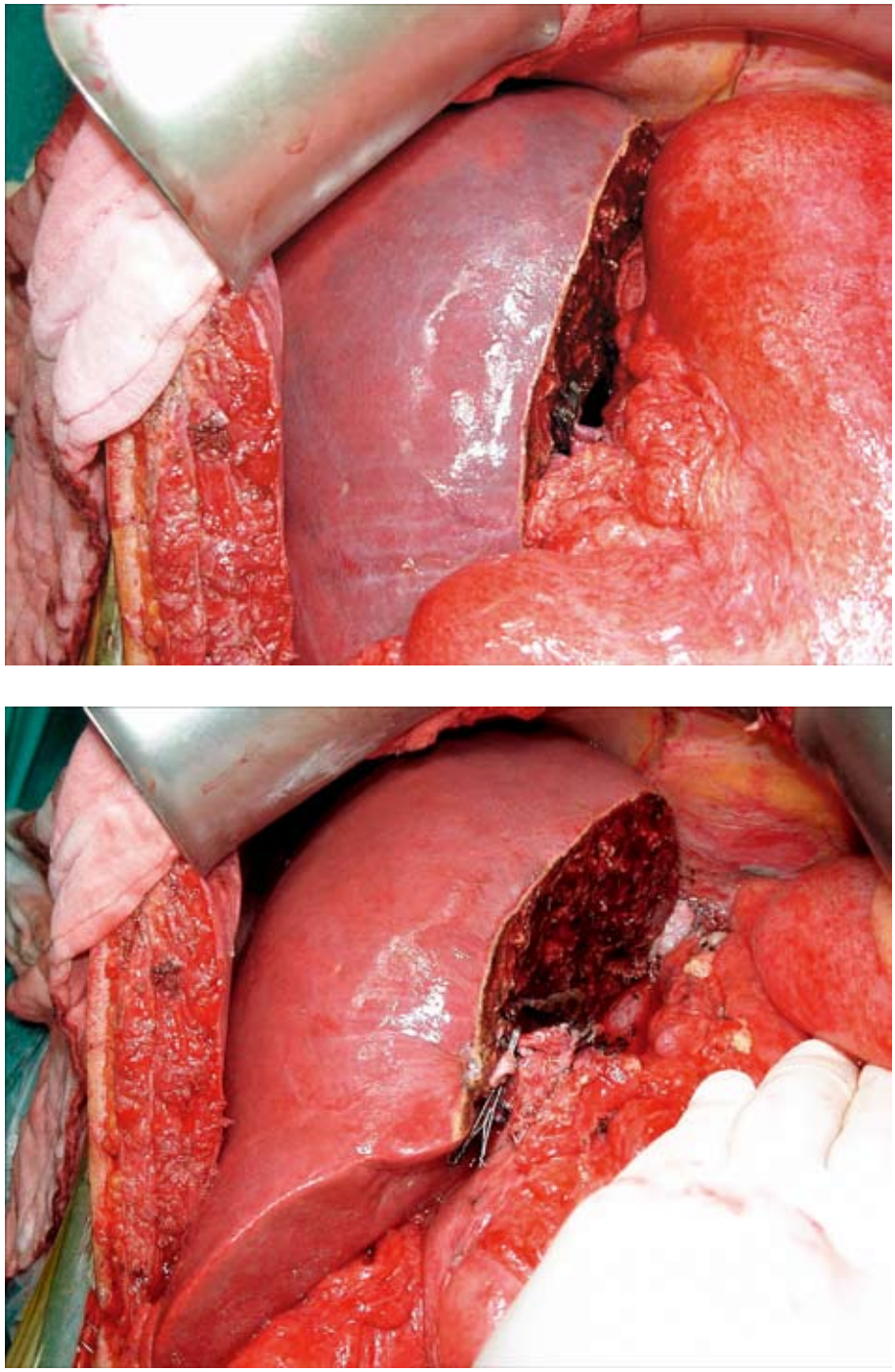

Figure 6.12. Right liver graft without segment V and VIII venous drainage on portal vein reperfusion **(A)**; Right liver graft without segment V and VIII venous drainage after hepatic artery reperfusion. The dusky area disappeared but the graft became swollen **(B)**.

segment IV is indeed congested and the segment IV portal vein blood flow is reversed in about 19% of donors.[1] However, the congestion is ameliorated by preservation of segment IVb hepatic veins and perhaps a large caudate hepatic vein, if present. The segment IVb hepatic vein is readily recognized on preoperative CT scan (Figure 6.18) or intraoperative ultrasonography. The MHV is transected proximal to the segment IVb hepatic vein at the time of graft delivery.[1,38] Exposure of the segment IVb hepatic vein joining the MHV requires exposure of the MHV itself (Figure 6.19). It is achieved by careful application of the ultrasonic dissector (Cavitron Ultrasonic Surgical Aspirator, CUSA, Valley Lab, Boulder, CO, USA). The exposure of the entire length of the MHV starts at the point where the segment IVa hepatic vein joins the main trunk (Figures 5.6 and 5.7). The MHV is then followed and exposed until the segment IVb hepatic vein is encountered. With exposure of the MHV, it is not necessary to perform the ultrasonography looking for the MHV during the transection process. If the donor could have the segment IVb hepatic vein preserved, the early postoperative INR value is lower than those with its sacrifice, although the INR of the two groups become the same toward the end of the first postoperative week, indicating that the regeneration power of the left liver remnant is high irrespective of whether the MHV is present or not[1] (Figure 6.20). However, to increase the safety margin, it is preferred to preserve the segment IVb hepatic vein with the donor's remnant liver. In terms of the Nakamura classification, those with segment IVb hepatic vein preservation in donors with Nakamura types II and III had lower peak INR in the postoperative period.[38] The result reiterates the need to preserve the segment IVb hepatic vein. Nowadays, it is possible to preserve the segment IVb hepatic vein in nearly every instance and the MHV could be joined directly to the IVC after venoplasty or using a vein graft.

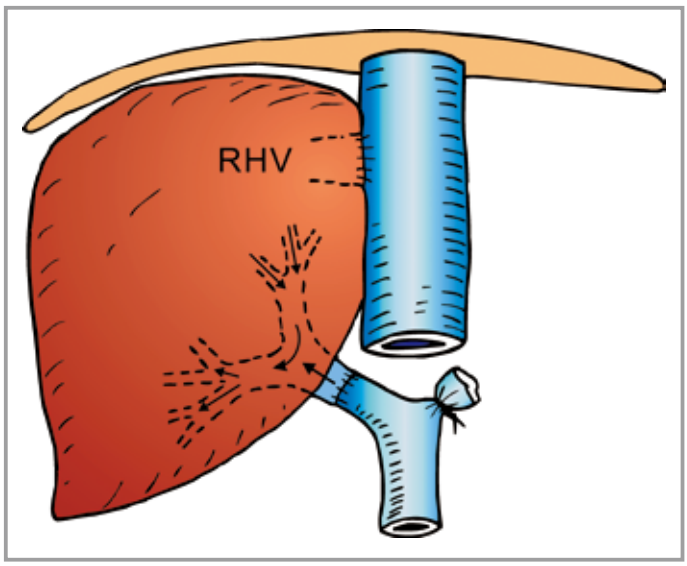

Figure 6.13. In the absence of venous drainage by the middle hepatic vein, portal blood flow in the right anterior sector is absent but arterial blood flow will continue and drain into the right anterior portal vein. The right posterior sector then accommodates all portal and arterial blood. The right posterior sector may suffer from injury related to excessive blood flow. Portal hypertension is not totally resolved. RHV, right hepatic vein.



Figure 6.14. Postoperative (Day 7) computed tomography scans of a patient receiving right liver living donor liver transplantation. The arrows (▷) indicate the middle hepatic vein on the transection surface of the liver and the segment V and VIII branches. The right anterior sector was uniformly perfused. Minimum ascites was present despite small graft size.

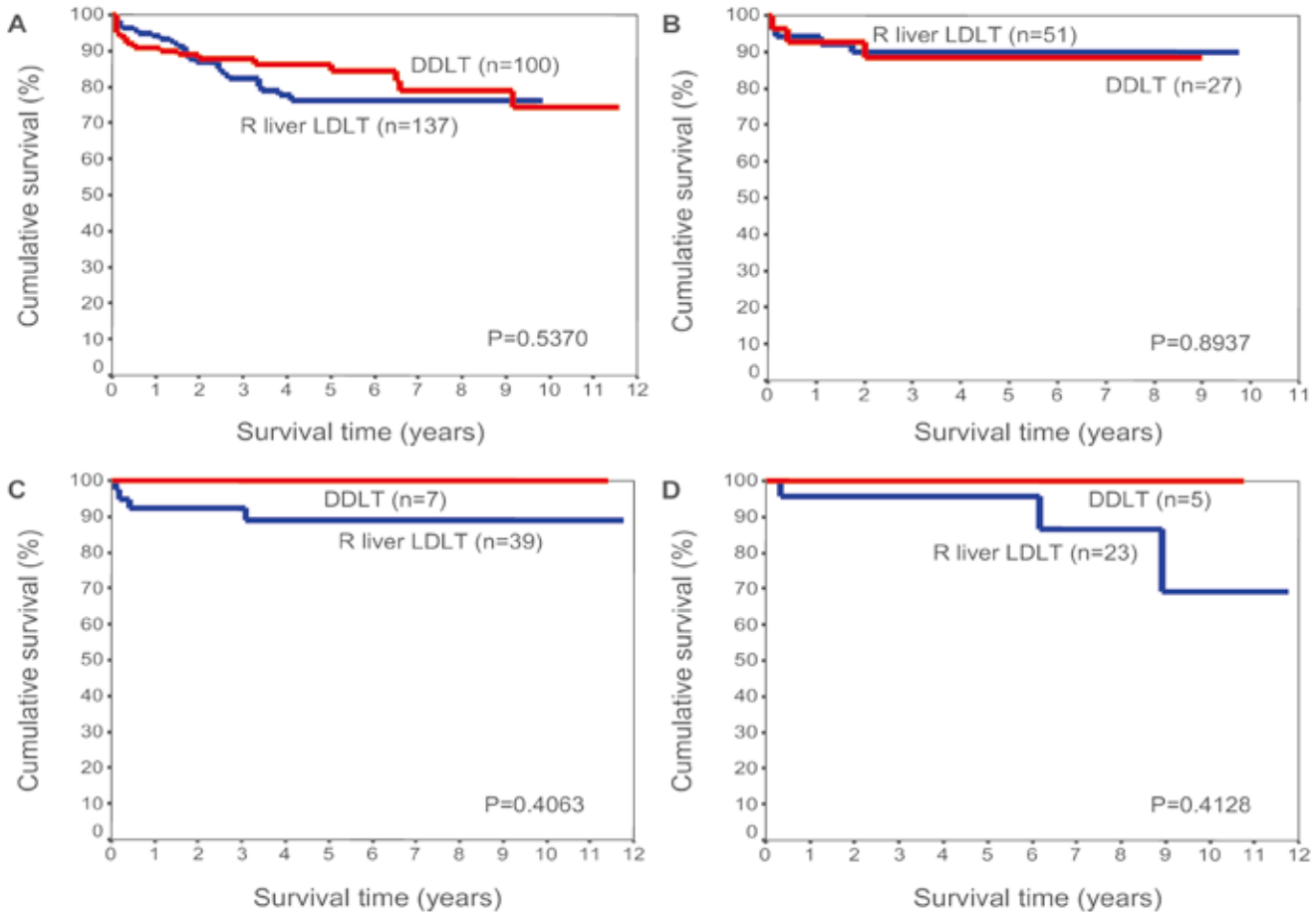

Figure 6.15. Comparison of long-term survival rates of patients with cirrhosis **(A)**, cirrhosis with acute deterioration **(B)**, chronic hepatitis with acute flare **(C)**, and fulminant hepatic failure **(D)** receiving right liver living donor liver transplantation (LDLT) (including the middle hepatic vein) with those of patients receiving whole-size deceased donor liver transplantation (DDLT).

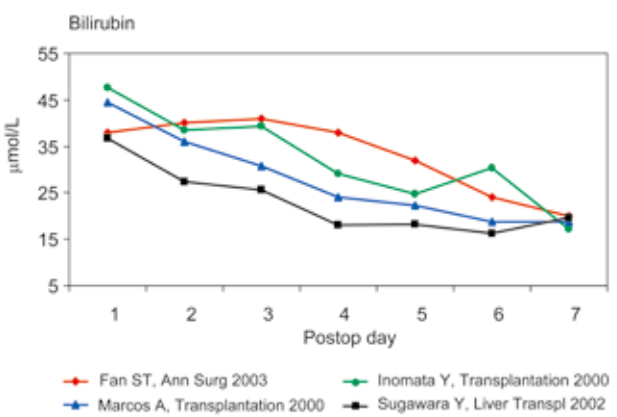

Figure 6.16. A graph shows the median postoperative serum total bilirubin levels of the donors among four transplant centers. Except our center, the middle hepatic vein was not included in the right liver grafts.

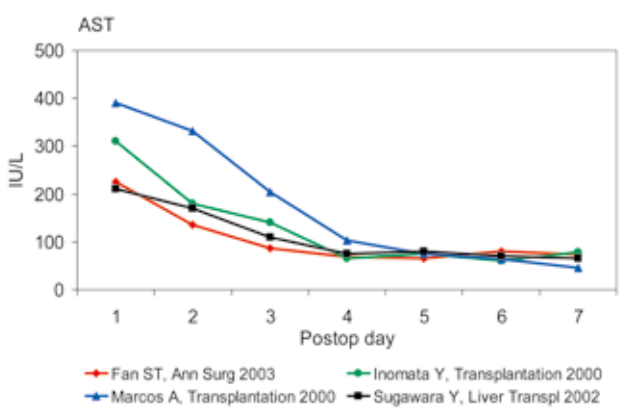

Figure 6.17. A graph shows the median postoperative serum aspartate aminotransferase (AST) levels among four centers. Except our center, the middle hepatic vein was not included in the right liver grafts.

Reconstruction of segment V and VIII hepatic veins

Recognizing the risk of the right liver graft without right anterior sector drainage but being reluctant to subject the donor to sacrifice of the MHV, many surgeons attempt to restore the continuity of segment V and VIII hepatic veins by conduits that are joined to the IVC, MHV or LHV of the recipients. Such conduits may be the recipient's own saphenous vein, superficial femoral vein, recanalized umbilical vein, or left portal vein and cryopreserved iliac



Figure 6.18. Computed tomography scan shows a prominent segment IVb hepatic vein (arrow) joining the middle hepatic vein at a high level (Nakamura type III). Such anatomy was considered not suitable for donation of the middle hepatic vein in the past. With modification of technique (see Figure 5.30), it is now possible to have the anastomosis completed without tension. The dotted line indicates the transection plane on the middle hepatic vein.

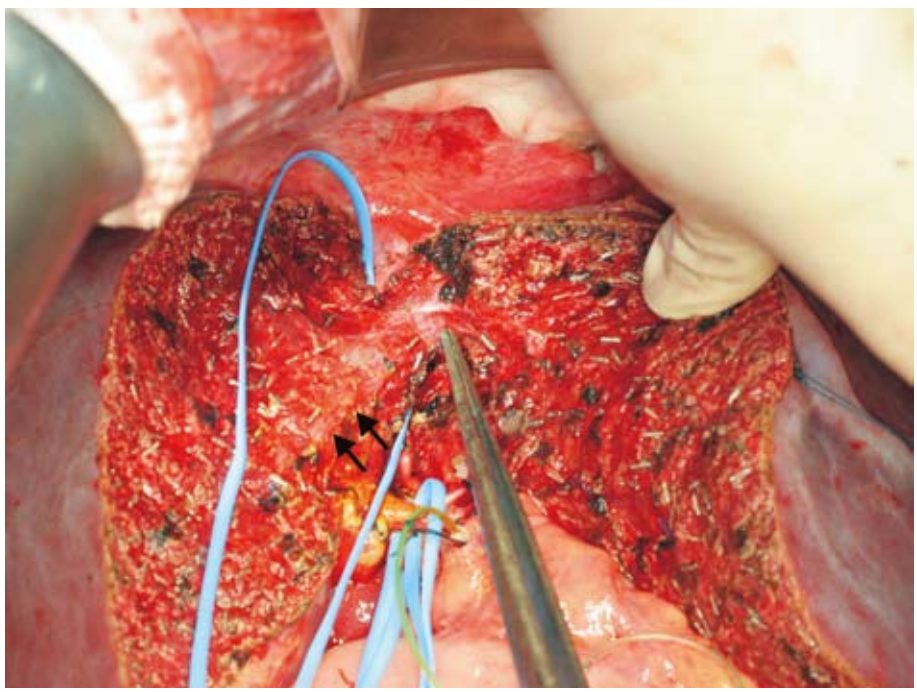

Figure 6.19. Operative photo of the donor whose computed tomography scan is shown in Figure 6.18. It shows the exposed middle hepatic vein (arrows), segment IVb hepatic vein (pointed by the DeBakey forceps) and the left hepatic vein. Safe dissection was possible only with deliberate exposure of the middle hepatic vein.

vein or artery obtained from the deceased donor.[39-49] Some also advocate enlarging the outlet or outflow by venous patches[50] or double IVC technique.[51] The segment VIII hepatic vein, if adjacent to the RHV, could also be incorporated into the RHV by the venoplasty technique.[44] However, since there could be numerous branches draining into the MHV, reconstruction of two or three prominent segment V/VIII

Table 6.1. Results of the right liver graft (including the middle hepatic vein) at Queen Mary Hospital, The University of Hong Kong. The data are expressed as median (range).

	No. of transplants	MELD score	Graft weight to ESLW (%)	Graft weight to recipient body weight (%)	Hospital mortality
Cirrhosis	137	16 (6–41)	48.8 (31.5–79.5)	0.9 (0.55–1.41)	5 (3.6%)
Cirrhosis with acute deterioration	51	35 (15–59)	47 (28.5–68.9)	0.88 (0.49–1.34)	3 (5.9%)
Chronic active hepatitis acute flare	39	37 (23–52)	49.7 (35.1–86.9)	0.93 (0.6–1.95)	3 (7.7%)
Fulminant hepatic failure	23	36 (27–50)	53.6 (39.7–89.4)	1.01 (0.74–1.92)	1 (4.3%)

MELD, Model for End-stage Liver Disease; ESLW, estimated standard liver weight

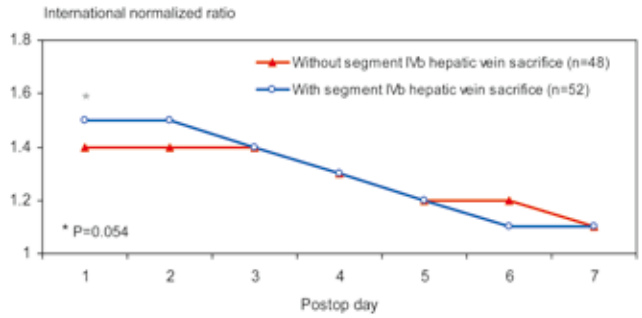

Figure 6.20. A graph shows the median values of the postoperative international normalized ratio of the donors with and without sacrifice of segment IVb hepatic veins.

hepatic veins may not guarantee uniform drainage. Thus, by magnetic resonance imaging, congestion of segments V and VIII still occur (62%) and the degree of congestion is not very different from grafts without segment V/VIII venous drainage.[52] The prolonged bench surgery time for venous conduit construction is a definite disadvantage. It has not been demonstrated that grafts with segment V and VIII conduits have equivalent liver function as those with the whole MHV. Two retrospective studies suggested that reconstruction of right anterior sector tributaries may not confer complete functional liver regeneration.[16,53] The extent of liver regeneration of segment V/VIII is not as efficient as segment VI/VII, even with MHV tributary reconstruction. The long-term patency rate of the venous conduit at the end of the first postoperative week is about 52%–90%.[54,55] The relatively low patency rate may be due to compression of the vein graft by the regenerated liver graft or sclerosis of the venous conduits. On the other hand, the patency of the MHV in our right liver graft with venoplasty when properly constructed is almost 100% at a median follow-up period of 27 months (range, 6–48 months).

Conclusion

Judging from the current data, right liver donation including the MHV is relatively safe, effective and preferred for adult-to-adult LDLT. The best plane for a right liver graft transection is on the midplane including the MHV and proximal to the segment IVb hepatic vein. To enhance donor safety, meticulous hemostasis, exposure of the MHV, prevention of bile leakage, and attention to all technical details must be achieved. A right liver graft containing the MHV is a durable graft even for patients with very high metabolic demands. A right liver graft without the MHV may be considered for patients with Child-Pugh A liver function,[56] if the graft size is relatively large (> 60% of the estimated standard liver weight), when the RHV drainage is dominant,[5] when venous communication between the right anterior and posterior sectors could definitely be seen preoperatively,[9] when segment VI/VII is larger than segment V/VIII, or when the volume of the congested liver is expected to be small.[57-59] To increase the safety margin, MHV tributary reconstruction must be performed to enhance venous outflow, even though the drainage of the right anterior sector with such conduits may not be uniform, perfect, or long-lasting. However, despite many suggestions of complicated algorithm of inclusion or exclusion of the MHV in the right liver graft,[57,59] it has never been proved that donor risk is totally eliminated by preserving the MHV with the liver remnant. Based on our data, a uniform policy of including the MHV in all right liver grafts is simple and safe as long as donor selection in terms of remnant liver volume, degree of fatty change, and meticulous surgical technique are followed. Most importantly, the applicability of adult-to-adult LDLT is thereby widened.

References

1. Fan ST, Lo CM, Liu CL, Wang WX, Wong J. Safety and necessity of including the middle hepatic vein in the right lobe graft in adult-to-adult live donor liver transplantation. Ann Surg 2003; 238: 137-148.
2. Ghobrial RM, Hsieh CB, Lerner S, Winters S, Nissen N, Dawson S, Amersi F, Chen P, Farmer D, Yersiz H, Busuttil RW. Technical challenges of hepatic venous outflow reconstruction in right lobe adult living donor liver transplantation. Liver Transpl 2001; 7: 551-555.
3. Hashimoto T, Sugawara Y, Kishi Y, Akamatsu N, Matsui Y, Kokudo N, Makuuchi M. Reconstruction of the middle hepatic vein tributary in a right lateral sector graft. Liver Transpl 2005; 11: 309-313.
4. Couinaud C. Surgical anatomy of the liver revisited. 1989. [ISBN 2-903672-01-6]
5. Radtke A, Nadalin S, Sotiropoulos GC, Molmenti EP, Schroeder T, Valentin-Gamazo C, Lang H, Bockhorn M, Peitgen HO, Broelsch CE, Malago M. Computer-assisted operative planning in adult living donor liver transplantation: a new way to resolve the dilemma of the middle hepatic vein. World J Surg 2007; 31: 175-185.
6. Kaneko T, Sugimoto H, Hirota M, Kure S, Kiuchi T, Nakao A. Intrahepatic venous anastomosis formation of the right liver in living donor liver transplantation: evaluations by Doppler ultrasonography and pulse-inversion ultrasonography with Levovist. Surgery 2005; 138: 21-27.
7. Nakamura S, Tsuzuki T. Surgical anatomy of the hepatic veins and the inferior vena cava. Surg Gynecol Obstet 1981; 152: 43-50.

8. Kawasaki S, Makuuchi M, Miyagawa S, Matsunami H, Hashikura Y, Ikegami T, Kakazu T, Hayashi K, Takayama T, Kawarazaki H. Extended lateral segmentectomy using intraoperative ultrasound to obtain a partial liver graft. Am J Surg 1996; 171: 286-288.
9. Satou S, Sugawara Y, Kokudo N, Makuuchi M. Preoperative detection of hepatic venous collaterals in right liver graft. Liver Transpl 2005; 11: 708-709.
10. Masselot R, Leborgne J. Anatomical study of the hepatic veins. Anat Clin 1978; 1: 109-125.
11. Sano K, Makuuchi M, Miki K, Maema A, Sugawara Y, Imamura H, Matsunami H, Takayama T. Evaluation of hepatic venous congestion: proposed indication criteria for hepatic vein reconstruction. Ann Surg 2002; 236: 241-247.
12. Kaneko T, Kaneko K, Sugimoto H, Inoue S, Hatsuno T, Sawada K, Ando H, Nakao A. Intrahepatic anastomosis formation between the hepatic veins in the graft liver of the living related liver transplantation: observation by Doppler ultrasonography. Transplantation 2000; 70: 982-985.
13. Yamamoto H, Maetani Y, Kiuchi T, Ito T, Kaihara S, Egawa H, Itoh K, Kamiyama Y, Tanaka K. Background and clinical impact of tissue congestion in right-lobe living-donor liver grafts: a magnetic resonance imaging study. Transplantation 2003; 76: 164-169.
14. Kim BS, Kim TK, Kim JS, Lee MG, Kim JH, Kim KW, Sung KB, Kim PN, Ha HK, Lee SG, Kang W. Hepatic venous congestion after living donor liver transplantation with right lobe graft: two-phase CT findings. Radiology 2004; 232: 173-180.
15. Lee S, Park K, Hwang S, Lee Y, Choi D, Kim K, Koh K, Han S, Choi K, Hwang K, Makuuchi M, Sugawara Y, Min P. Congestion of right liver graft in living donor liver transplantation. Transplantation 2001; 71: 812-814.
16. Mizuno S, Iida T, Yagi S, Usui M, Sakurai H, Isaji S, Uemoto S. Impact of venous drainage on regeneration of the anterior segment of right living-related liver grafts. Clin Transplant 2006; 20: 509-516.
17. Marcos A, Fisher RA, Ham JM, Olzinski AT, Shiffman ML, Sanyal AJ, Luketic VA, Sterling RK, Posner MP. Emergency portacaval shunt for control of hemorrhage from a parenchymal fracture after adult-to-adult living donor liver transplantation. Transplantation 2000; 69: 2218-2221.
18. Ringe B, Braun F, Laabs S, Matamoros M, Lorf T, Canelo R. Graft rupture after living donor liver transplantation. Transplant Proc 2002; 34: 2268-2271.
19. Moon DB, Lee SG, Hwang S, Park KM, Kim KH, Ahn CS, Chu CW, Lee YJ, Na YW, Ha TY, Cho SH, Oh KB. Massive subcapsular hematoma of liver graft after living donor liver transplantation: a case report. Transplant Proc 2003; 35: 1469-1472.
20. Kasahara M, Kozaki K, Yoshida T, Yamamoto H, Ogawa K, Ogura Y, Tanaka K. Subcapsular hematoma after right-lobe living-donor liver transplantation. J Hepatobiliary Pancreat Surg 2004; 11: 330-332.
21. Maetani Y, Itoh K, Egawa H, Shibata T, Ametani F, Kubo T, Kiuchi T, Tanaka K, Konishi J. Factors influencing liver regeneration following living-donor liver transplantation of the right hepatic lobe. Transplantation 2003; 75: 97-102.
22. Testa G, Malago M, Nadalin S, Hertl M, Lang H, Frilling A, Broelsch CE. Right-liver living donor transplantation for decompensated end-stage liver disease. Liver Transpl 2002; 8: 340-346.
23. Icoz G, Kilic M, Zeytunlu M, Celebi A, Ersoz G, Killi R, Memis A, Karasu Z, Yuzer Y, Tokat Y. Biliary reconstructions and complications encountered in 50 consecutive right-lobe living donor liver transplantations. Liver Transpl 2003; 9: 575-580.
24. Goldstein MJ, Salame E, Kapur S, Kinkhabwala M, LaPointe-Rudow D, Harren N P P, Lobritto SJ, Russo M, Brown RS Jr, Cataldegirmen G, Weinberg A, Renz JF, Emond JC. Analysis of failure in living donor liver transplantation: differential outcomes in children and adults. World J Surg 2003; 27: 356-364.
25. Kam I. Adult-adult right hepatic lobe living donor liver transplantation for status 2a patients: too little, too late. Liver Transpl 2002; 8: 347-349.
26. Marcos A, Ham JM, Fisher RA, Olzinski AT, Posner MP. Single-center analysis of the first 40 adult-to-adult living donor liver transplants using the right lobe. Liver Transpl 2000; 6: 296-301.
27. Bak T, Wachs M, Trotter J, Everson G, Trouillot T, Kugelmas M, Steinberg T, Kam I. Adult-to-adult living donor liver transplantation using right-lobe grafts: results and lessons learned from a single-center experience. Liver Transpl 2001; 7: 680-686.
28. Sugawara Y, Makuuchi M, Kaneko J, Kokudo N. MELD score for selection of patients to receive a left liver graft. Transplantation 2003; 75: 573-574.
29. Fan ST, Lo CM, Liu CL, Yong BH, Wong J. Determinants of hospital mortality of adult recipients of right lobe live donor liver transplantation. Ann Surg 2003; 238: 864-870.
30. Inomata Y, Uemoto S, Asonuma K, Egawa H. Right lobe graft in living donor liver transplantation. Transplantation 2000; 69: 258-264.
31. Marcos A, Fisher RA, Ham JM, Olzinski AT, Shiffman ML, Sanyal AJ, Luketic VA, Sterling RK, Olbrisch ME, Posner MP. Selection and outcome of living donors for adult to adult right lobe transplantation. Transplantation 2000; 69: 2410-2415.
32. Sugawara Y, Makuuchi M, Takayama T, Imamura H, Kaneko J, Ohkubo T. Safe donor hepatectomy for living related liver transplantation. Liver Transpl 2002; 8: 58-62.
33. Cattral MS, Molinari M, Vollmer CM Jr, McGilvray I, Wei A, Walsh M, Adcock L, Marks N, Lilly L, Girgrah N, Levy G, Greig PD, Grant DR. Living-donor right hepatectomy with or without inclusion of middle hepatic vein: comparison of morbidity and outcome in 56 patients. Am J Transplant 2004; 4: 751-757.
34. Scatton O, Belghiti J, Dondero F, Goere D, Sommacale D, Plasse M, Sauvanet A, Farges O, Vilgrain V, Durand F. Harvesting the middle hepatic vein with a right hepatectomy does not increase the risk for the donor. Liver Transpl 2004; 10: 71-76.
35. Cho EH, Suh KS, Lee HW, Shin WY, Yi NJ, Lee KU. Safety of modified extended right hepatectomy in living liver donors. Transpl Int 2007; 20: 779-783.
36. Chen TY, Chen CL, Huang TL, Tsang LL, Wang CC, Wang SH, Yang CH, Concejero AM, Cheng YF. Remnant liver regeneration and spleen volume changes after living liver donation: influence of the middle hepatic vein. Clin Transplant 2006; 20: 725-731.
37. Hata S, Sugawara Y, Kishi Y, Niiya T, Kaneko J, Sano K, Imamura H, Kokudo N, Makuuchi M. Volume regeneration after right liver donation. Liver Transpl 2004; 10: 65-70.
38. Chan SC, Lo CM, Liu CL, Wong Y, Fan ST, Wong J. Tailoring donor hepatectomy per segment 4 venous drainage in right lobe live donor liver transplantation. Liver Transpl 2004; 10: 755-762.
39. Lee SG, Park KM, Hwang S, Kim KH, Chi DN, Joo SH, Anh CS, Nah YW, Jeon JY, Park SH, Koh KS, Han SH, Choi KT, Hwang KS, Sugawara Y, Makuuchi M, Min PC. Modified right liver graft from a living donor to prevent congestion. Transplantation 2002; 74: 54-59.
40. Sugawara Y, Makuuchi M, Sano K, Imamura H, Kaneko J, Ohkubo T, Matsui Y, Kokudo N. Vein reconstruction in modified right liver graft for living donor liver transplantation. Ann Surg 2003; 237: 180-185.
41. Kornberg A, Heyne J Schotte U, Hommann M, Scheele J. Hepatic venous outflow reconstruction in right lobe living-donor liver graft using recipient's superficial femoral vein. Am J Transplant 2003; 3: 1444-1447.
42. Cattral MS, Greig PD, Muradali D, Grant D. Reconstruction of middle hepatic vein of a living-donor right lobe liver graft with recipient left portal vein. Transplantation 2001; 71: 1864-1866.
43. Dong G, Sankary HN, Malago M, Oberholzer J, Panaro F, Knight PS, Jarzembowski TM, Benedetti E, Testa G. Cadaver iliac vein outflow reconstruction in living donor right lobe liver transplantation. J Am Coll Surg 2004; 199: 504-507.
44. Kinkhabwala MM, Guarrera JV, Leno R, Brown RS, Prowda J, Kapur S, Emond JC. Outflow reconstruction in right hepatic live donor liver transplantation. Surgery 2003; 133: 243-250.

45. Wu H, Yang JY, Yan LN, Li B, Zeng Y, Wen TF, Zhao JC, Wang WT, Xu MQ, Lu Q, Chen ZY, Ma YK, Li J. Hepatic venous outflow reconstruction in adult right lobe living donor liver transplantation without middle hepatic vein. Chin Med J (Engl) 2007; 120: 947-951.
46. Soejima Y, Shimada M, Suehiro T, Yoshizumi T, Kishikawa K, Maehara Y. Reconstruction of the middle hepatic vein tributaries using the recipient's recanalized umbilical vein in right-lobe living-donor liver transplantation. Surgery 2006; 139: 442-445.
47. Eguchi S, Takatsuki M, Soyama A, Hidaka M, Tokai H, Hamasaki K, Miyazaki K, Miyamoto S, Tajima Y, Kanematsu T. A modified triangular venoplasty for reconstruction of middle hepatic vein tributaries in living donor liver transplantation. Surgery 2007; 141: 829-830.
48. Kilic M, Aydin U, Sozbilen M, Ozer I, Tamsel S, Demirpolat G, Atay Y, Alper M, Zeytunlu M. Comparison between allogenic and autologous vascular conduits in the drainage of anterior sector in right living donor liver transplantation. Transpl Int 2007; 20: 697-701.
49. Hwang S, Lee SG, Song GW, Lee HJ, Park JI, Ryu JH. Use of endarterectomized atherosclerotic artery allograft for hepatic vein reconstruction of living donor right lobe graft. Liver Transpl 2007; 13: 306-308.
50. Malago M, Molmenti EP, Paul A, Nadalin S, Lang H, Radtke A, Liu C, Frilling A, Biglarnia R, Broelsch CE. Hepatic venous outflow reconstruction in right live donor liver transplantation. Liver Transpl 2005; 11: 364-365.
51. Sugawara Y, Makuuchi M, Akamatsu N, Kishi Y, Niiya T, Kaneko J, Imamura H, Kokudo N. Refinement of venous reconstruction using cryopreserved veins in right liver grafts. Liver Transpl 2004; 10: 541-549.
52. Ito T, Kiuchi T, Yamamoto H, Maetani Y, Oike F, Kaihara S, Itoh K, Tanaka K. Efficacy of anterior segment drainage reconstruction in right-lobe liver grafts from living donors. Transplantation 2004; 77: 865-868.
53. Morioka D, Sekido H, Matsuo K, Takeda K, Sugita M, Kubota T, Tanaka K, Endo I, Togo S, Shimada H. Middle hepatic vein tributary reconstruction could not act as a complete substitute for an entirely preserved middle hepatic vein. Hepatogastroenterology 2005; 52: 208-211.
54. Kim DG, Moon IS, Kim SJ, Lee YJ, Lee MD. Effect of middle hepatic vein reconstruction in living donor liver transplantation using right lobe. Transplant Proc 2006; 38: 2099-2101.
55. Sano K, Makuuchi M. Patency of reconstructed MHV or its tributaries in living-donor liver transplantation using right liver graft (Abstract). J Japan Surg Soc 2006; 107(Suppl 2): 97.
56. Ben-Haim M, Emre S, Fishbein TM, Sheiner PA, Bodian CA, Kim-Schluger L, Schwartz ME, Miller CM. Critical graft size in adult-to-adult living donor liver transplantation: impact of the recipient's disease. Liver Transpl 2001; 7: 948-953.
57. Asakuma M, Fujimoto Y, Bourquain H, Uryuhara K, Hayashi M, Tanigawa N, Peitgen HO, Tanaka K. Graft selection algorithm based on congestion volume for adult living donor liver transplantation. Am J Transplant 2007; 7: 1788-1796.
58. Yonemura Y, Taketomi A, Soejima Y, Yoshizumi T, Uchiyama H, Gion T, Harada N, Ijichi H, Yoshimitsu K, Maehara Y. Validity of preoperative volumetric analysis of congestion volume in living donor liver transplantation using three-dimensional computed tomography. Liver Transpl 2005; 11: 1556-1562.
59. de Villa VH, Chen CL, Chen YS, Wang CC, Lin CC, Cheng YF, Huang TL, Jawan B, Eng HL. Right lobe living donor liver transplantation-addressing the middle hepatic vein controversy. Ann Surg 2003; 238: 275-282.

7. Biliary complications of right liver LDLT

Introduction

Living donor liver graft by itself is one of the independent significant variables contributing to biliary complications after liver transplantation.[1] At the early phase of development of adult-to-adult right liver living donor liver transplantation (LDLT), the biliary complication rate in the recipients was high, ranging from 43%–64%.[2-4] There has been a reduction in the biliary complication rate in recent years,[5-9] but the incidence is still higher than that of deceased donor liver transplantation.[10] Moreover, the donors may suffer from biliary complications too. In this chapter, various factors that may cause biliary complications in right liver LDLT are discussed.

Anatomy

The arterial blood supply of the right hepatic duct (RHD) and left hepatic duct (LHD) and their confluence are provided by the arterial arcade that runs in the ductal wall[11] (Figure 7.1). The arcade itself is derived from the right gastric artery, gastroduodenal artery, right hepatic artery (RHA), left hepatic artery, and arteries of the caudate lobe and hilar plate.[12] Sizable arterial branches are present in the hilar plate and are recognized on dividing such structure, indicating that collaterals are present between the right and left livers.[13] Although the arcades provide excellent blood supply, once the RHD, hilar plate and caudate lobe are divided, the arterial supply to the RHD becomes precarious and depends on tiny branches that come off from the RHA. Therefore, such tiny arterial branches from the RHA must be preserved at all costs (Figure 7.2A). However, such arterial branches are visible only occasionally. To avoid damaging them, dissection into the space in between the RHD and RHA must be avoided. In our early phase of development of right liver LDLT, the RHA was isolated for a long length deep into the right liver hilum, hoping that a sufficiently long RHA would be available for anastomosis. Such procedure has been found not necessary and probably accounts for the high incidence of biliary leakage in the early part of the series.

The venous drainage of the RHD is seldom mentioned in the literature. It is probably via the parabiliary venous plexus through which blood returns to the adjacent liver parenchyma.[14] Therefore, we advocate deviating the liver transection plane to the left side of the gallbladder fossa to meet the proposed transection site of the RHD (Figure 7.2B). By such design, the RHD is not denuded and liver tissue is preserved around the RHD for venous drainage.

The RHD and LHD confluence is variable in

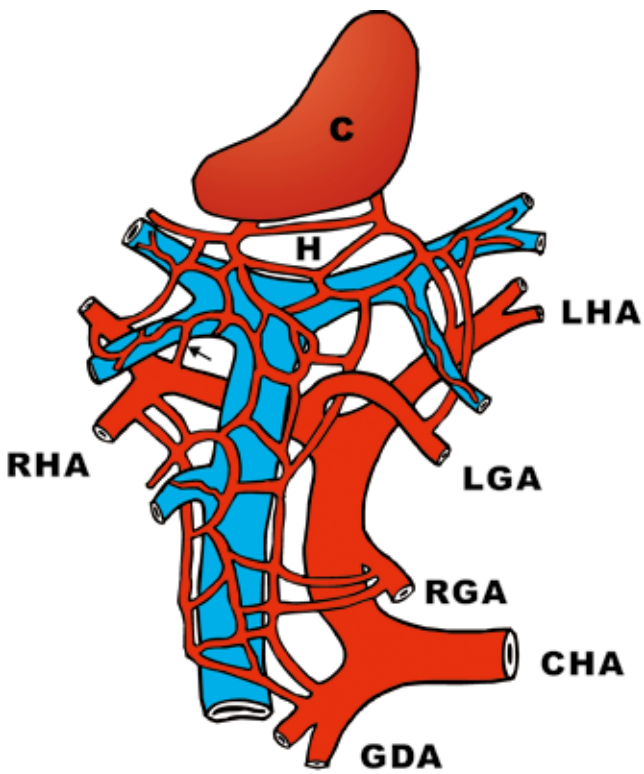

Figure 7.1. Arterial blood supply of the right hepatic duct. The arcade is derived from the right gastric artery (RGA), gastroduodenal artery (GDA), left gastric artery (LGA), right hepatic artery (RHA), and left hepatic artery (LHA). After division of the right hepatic duct, the blood supply will depend on the twigs from the RHA (arrow). C, caudate lobe; H, hilar plate. (Modified from Vellar[11])

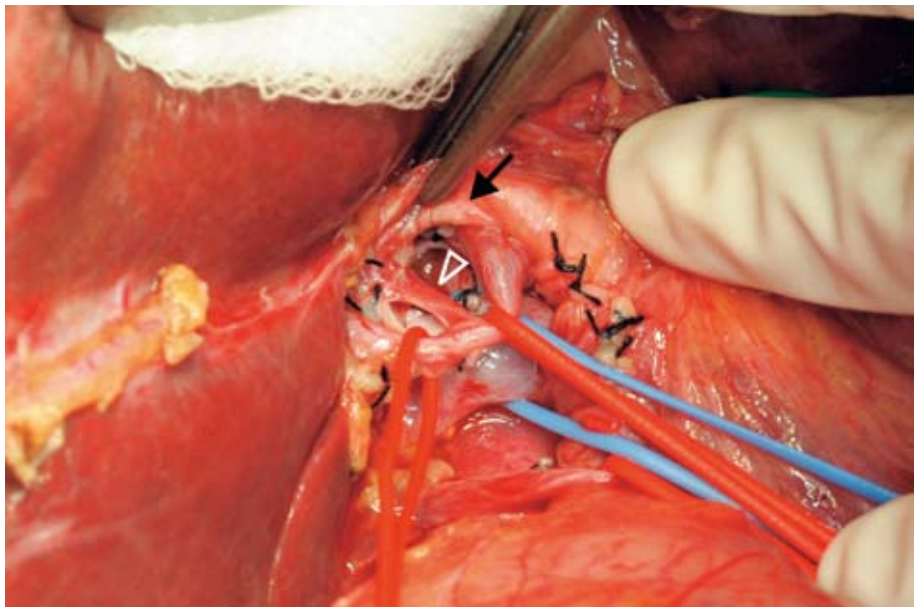

A

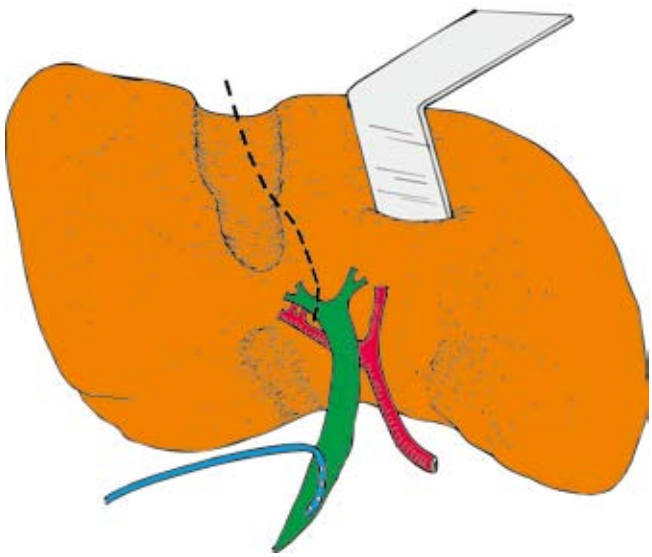

B

Figure 7.2A,B. A small branch from the right hepatic artery (▷) supplying the right hepatic duct (arrow) **(A)**; The liver transection line should deviate to the left side of the gallbladder fossa to meet the proposed point of right hepatic duct division. Sufficient liver tissue is then preserved for venous return of the right hepatic duct **(B)**.

configuration.[15] The confluence may be high and closely associated with the hilar plate, making the RHD and LHD almost horizontal and difficult to isolate from the hilar plate extrahepatically. The confluence may be low and away from the hilar plate. In the latter situation, the extrahepatic course of the RHD is long, and is advantageous for hilar dissection in the donor because its early division will facilitate subsequent hilar dissection. However, before dividing the right hepatic duct or its branches, the surgeon must liaise with the recipient team to ascertain that the recipient operation will proceed.

In case of low extrahepatic confluence of hepatic ducts, a relatively long RHD stump will facilitate the implantation procedure, but it is not known whether the long RHD stump has the same degree of arterial blood supply as the one close to the hilar plate. It would be safer to trim the RHD to near the hilar plate before biliary anastomosis.

The number of RHD joining the common hepatic duct may range from one to four or even five. Increase in the number of RHD orifices in the graft is definitely an adverse factor leading to biliary leakage and stenosis[16] (Figure 7.3). Three or more tiny RHD openings are a relative contraindication for choosing the right liver graft. If the size of the left liver is marginally sufficient for the recipient and only one LHD is present, the left liver may be chosen instead.[17] On many occasions, the RHD is short. In this situation, defining an exact point of RHD division is necessary to avoid two or more ductal openings in the graft and injury to the hepatic duct confluence. An intraoperative cholangiogram is mandatory before RHD division (Figure 5.17).

At the hilar plate, several tiny hepatic ducts from the caudate lobe join the RHD and LHD.[18] Such tiny branches are seen on dividing the hilar plate by scissors or a knife, but they would be missed if the hilar plate is encircled and ligated before division. If seen, the ductal openings must be sutured meticulously. Ligating the hilar plate may be less desirable because loosening of ligature may expose the hilar hepatic duct openings and be responsible for postoperative bile leakage. Therefore, the preferred practice would be sharp division of the hilar plate, observation for possible caudate ductal openings, followed by suturing. It must be noted that sometimes the caudate duct openings are segregated from the biliary tract and could not be detected by methylene blue injected via the cystic duct. To detect such openings, a clean gauze pressing onto the hilar plate is needed but patience and diligence are essential.



Figure 7.3. An operative cholangiogram shows separate right anterior and posterior hepatic ducts. It is for certain that segment VI and VII ducts will be divided separately, leading to three hepatic duct orifices. In this donor, the left liver was chosen for donation.

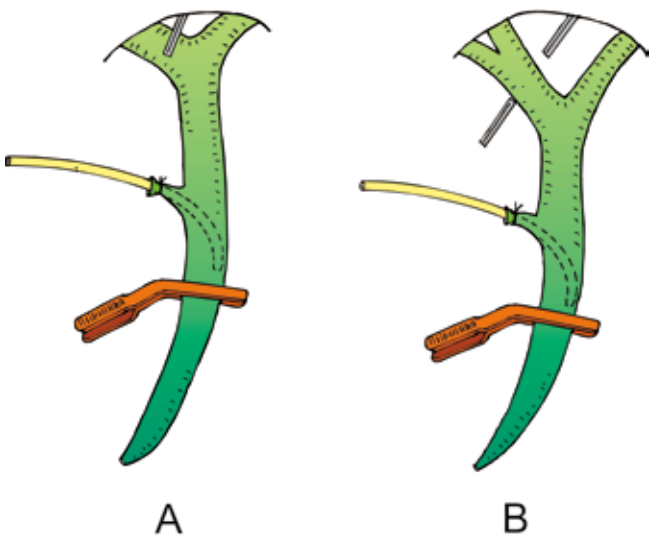

Figure 7.4. A metal clip is attached to the liver capsule at the proposed site of division of the right hepatic duct **(A)**; If the confluence of the hepatic ducts is low, clipping to the liver capsule is irrelevant. Instead, clipping to the edge or loose tissue of the right hepatic duct would be more appropriate **(B)**.

Preoperative recognition of biliary anatomy

Since information of RHD anatomy may be essential for donor selection, attempts are made to study the biliary anatomy before laparotomy. Using iodipamide meglumine and multi-detector computed tomography (CT), it is possible to evaluate the biliary tract anatomy, particularly the second-order branches and the accuracy may be higher than magnetic resonance cholangiopancreatography.[19] However, because CT cholangiography or magnetic resonance cholangiopancreatography could not depict the second-order branches accurately in every case, the values of these examinations are limited (Figure 2.11). Recently, a high-quality CT cholangiogram could be obtained by using the MeVis software (MeVis Technology, Bremen, Germany) after intravenous injection of bilioscopin (meglumine iotroxate), but occasional cases of allergic reaction to the intravenous contrast are observed. Perhaps, currently, no other examination is safer and more accurate than a meticulously performed intraoperative cholangiography.

Donor intraoperative cholangiography

Intraoperative cholangiogram is obtained by cannulating the cystic duct after cholecystectomy. To avoid damaging the RHD or its sectoral branches in case of anomaly, the cystic duct should not be ligated until the entire gallbladder is detached from the gallbladder fossa and the "T" junction is verified. In case of previous cholecystectomy, sometimes the cystic duct stump could be dissected out for cannulation. As explained in the previous chapters, the cholangiogram is obtained by slow instillation of undiluted radiographic contrast and sequence of filling of intrahepatic duct is observed[16] (Figure 5.1). The site of the proposed RHD division is marked by clipping a large-size Liga clip (Ethicon Ltd, Edinburgh, UK) to the liver capsule, rather than the



Figure 7.5. Rotation of the X-ray tube in the anticlockwise direction produces a more accurate and transverse display of the right and left hepatic ducts.

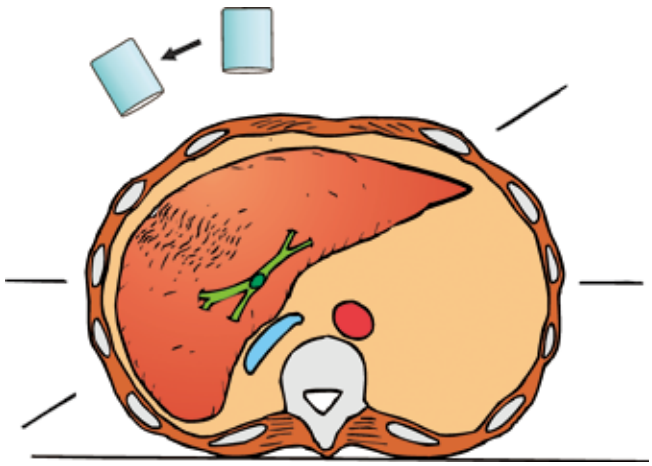

Figure 7.6. The transverse axis of the liver hilum is in the oblique plane when the donor is lying in the flat position.

RHD itself, to avoid damaging the RHD (Figure 7.4). The caveat, however, is that after parenchymal transection, the site marked on the liver capsule may not correspond exactly to the site of the proposed RHD division. That is why another cholangiogram is needed before the RHD is divided. Another situation that leads to inexactness is when the extrahepatic RHD is long, the metal clip placed at the liver capsule is far away from the RHD (Figure 7.4). In such situation, gentle dissection is made to define the confluence of hepatic ducts and the Liga clip is placed on the loose tissue around the RHD itself (Figure 7.4B).

As shown in the previous chapter, it is preferred to rotate the X-ray tube counterclockwise to produce a true antero-posterior view of the right and left intrahepatic ducts because the transverse axis of the liver is oblique in relation to the body (Figures 7.5–7.11). After rotation of the X-ray tube, the segmental branches could be readily recognized and the RHD will appear longer and not overlying the confluence, allowing precise marking of the site of division of the duct. Moreover, counterclockwise rotation of the X-ray tube may reveal a long extrahepatic right posterior hepatic duct joining the right or posterior wall of the common hepatic duct (Figures 7.9A–C). The maneuver is equally applicable to left liver donation (Figures 7.8 and 7.11).

Filling of the segment IV duct could be difficult when the segment IV duct joins the segment III duct, despite occlusion of the lower end of the common bile duct by either a balloon catheter (Figure 7.12) or direct compression. This is not a major problem because the segment IV duct if joining the left duct or common hepatic duct will appear early and be readily recognized.

A second cholangiogram is mandatory at the time of division of the RHD, especially when the RHD stump is short. Injury to the confluence of the hepatic ducts is undesirable and must be avoided at all costs. Creation of two or more RHD openings in the graft is equally undesirable (Figures 3.11, 7.13 and 7.14). Another advantage of performing the cholangiogram at the time of RHD division is that after separation of the right and left livers, the segmental hepatic ducts at the liver hilum do not

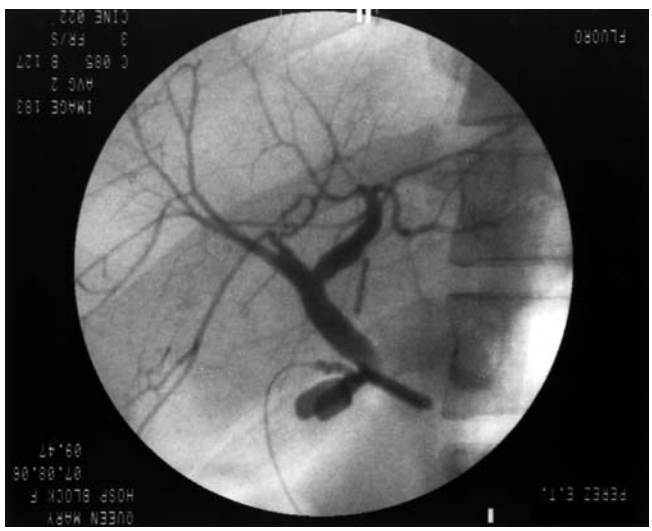

A



B

Figure 7.7A,B. Cholangiogram taken with the X-ray tube in the antero-posterior position. There is much overlapping of the segment IV and VIII hepatic ducts causing difficulty in interpretation **(A)**; Cholangiogram taken with X-ray tube rotated counterclockwise. Now, the right and left hepatic duct branches spread out and interpretation of the segmental branches becomes easier **(B)**.

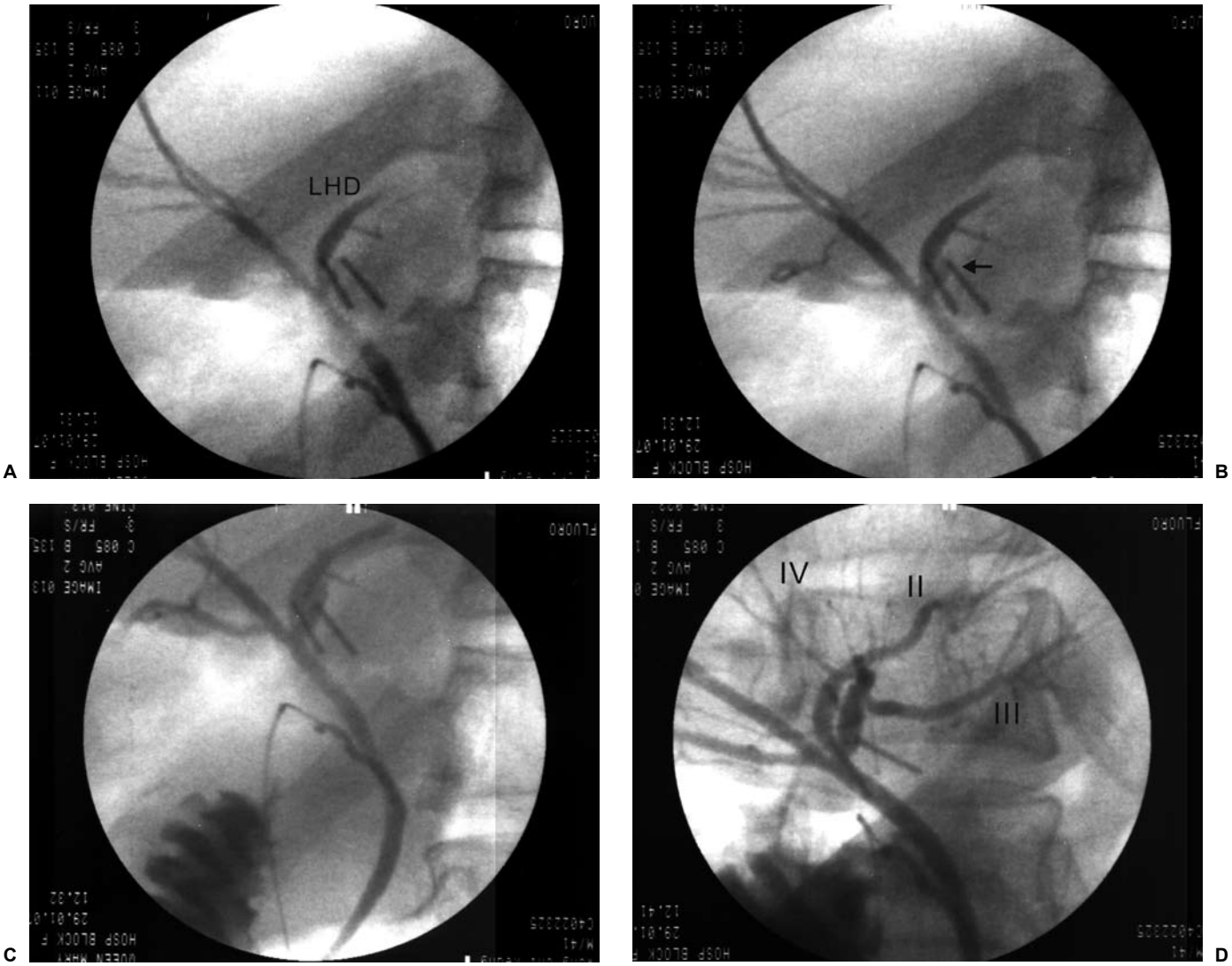

Figure 7.8A-D. Initial cholangiogram of a left liver donor showed a single left hepatic duct (LHD) **(A)**; Further injection of contrast showed a branch of uncertain nature (arrow) **(B)**; Further injection of contrast showed overlapping of the two left hepatic branches, again, of uncertain nature **(C)**; By rotation of the X-ray tube and injection of contrast under compression of the lower end of the common bile duct, complete filling of the intrahepatic branches was obtained and the nature of the hepatic ducts became clear. The duct that was shown first in the previous cholangiogram was the segment II duct. The duct of uncertain nature was the segment III/IV duct, which was shown later due to its more ventral position. The two left intrahepatic ducts joined at a position very near to the common hepatic duct. Two ductal orifices in the graft were inevitable or preferable to avoid damage to the donor hepatic duct confluence **(D)**.

overlap with each other and clear display of the difficult hepatic duct anatomy is possible (Figures 7.10 and 7.15). It allows clear identification of the biliary anatomy if the previous cholangiogram produces a confusing picture.

Other than using the Liga clip as a reference for the exact site of division of the RHD, some surgeons use the radio-opaque wire loop for guidance[20] or direct probing by a dilator inserted through a choledochotomy.[21] The former procedure requires encircling of the hilar plate which we do not do nowadays because the blind passage of the instrument that encircles the hilar plate may damage the caudate pedicle or the right posterior hepatic duct. The latter procedure is quite invasive. The long-term outcome of the donor receiving such invasive manipulation is not known. In general, one should maintain integrity of the common hepatic/bile duct of the donor at all times.

Bile leakage in the donor

Bile leakage in the donor could occur from the liver

transection surface, caudate branches, RHD stump and cystic duct stump. Bile leakage from the transection surface is uncommon if the transection is exactly at the midplane and all suspected branches are clipped or ligated rather than coagulated. It is useful to remember that the midplane is oblique and the segment IV is on top of the segment VIII (Figure 7.16). If the middle hepatic vein is exposed

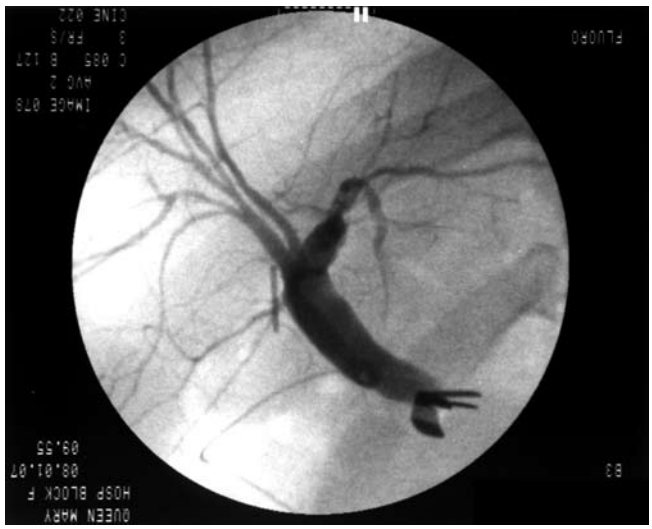
A


B

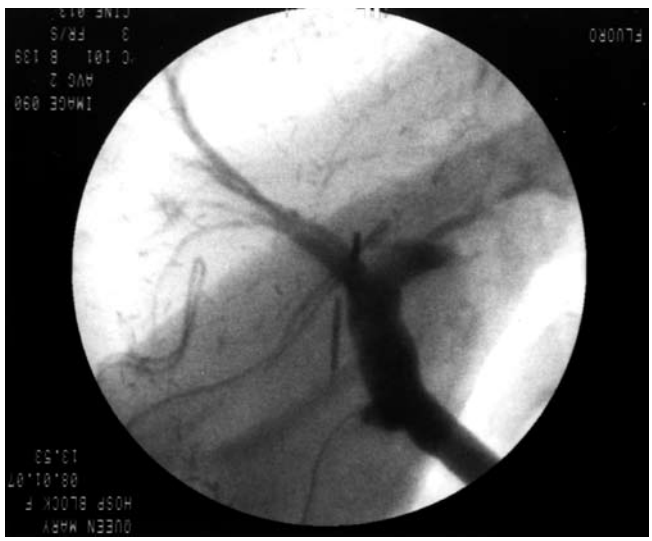
C

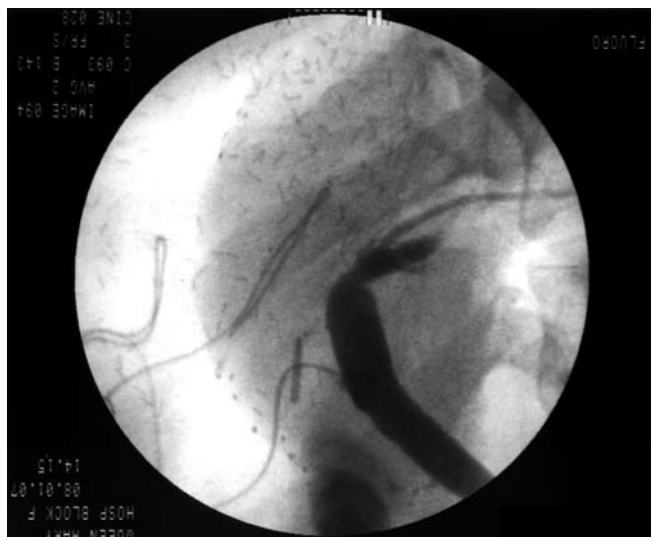
D


E

Figure 7.9A-E. Cholangiogram of a donor with the film taken in the antero-posterior position. It appears that there are three independent right hepatic ducts (A); After rotation of the X-ray tube in a counterclockwise direction, the right posterior hepatic duct joining the posterior wall of the common bile duct became obvious, while the right anterior hepatic duct was only a single trunk. The extrahepatic right posterior duct was divided first for subsequent hilar dissection (B); Before division of the right anterior hepatic duct, another cholangiogram was performed. There were two metal clips marking the proposed site of division. A single right anterior hepatic duct orifice was obtained in the graft (C); After closure of the right hepatic duct stump, the cholangiogram showed suspicious narrowing of the confluence of the hepatic ducts (D); On pulling down the common bile duct and displacing the left liver toward the right, the duct was straightened and the narrowing was not obvious. The previous cholangiogram finding was an artifact due to folding of the duct and left displacement of the left liver (E).



A



B

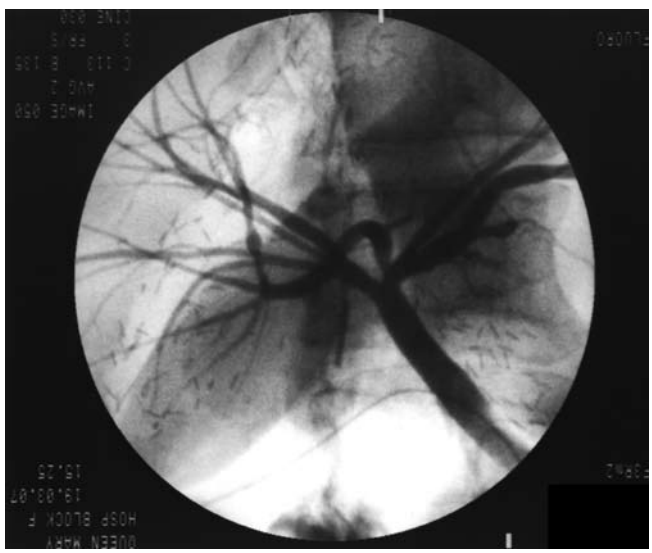

C

Figure 7.10A-C. Operative cholangiogram of a right liver donor. It shows a large branch from the left side (arrows). The display at the liver hilum was not clear. It was initially thought to be the segment IV duct **(A)**; Counterclockwise rotation of the X-ray tube did not produce a better display **(B)**; After liver division, cholangiogram was performed again in preparation for right hepatic duct division. Further counterclockwise rotation of the X-ray tube produced a clear display of the hepatic ducts. The hepatic duct in question was the right posterior duct joining the left hepatic duct near the confluence. The degree of rotation could be appreciated from the position of the spine in relation to the liver hilum **(C)**.

and followed and used as a guide for the transection plane, major branches of the segment IV duct would not be divided or coagulated during the liver transection. On approaching the inferior vena cava, a thick trunk of segment Ir (i.e. right side of segment I) pedicle may be encountered.[18] It should be ligated and sutured to prevent bile leakage from the segment Ir bile duct. Indiscriminate use of argon beam coagulation on the liver transection surface may cause sloughing of ligature and bile leakage afterward. Small-bite suturing is preferred for hemostasis at the area near to ligature. Fine needle suturing of the RHD stump by 6-0 PDS may prevent leakage from the needle hole. Dilute methylene blue instillation into the common hepatic duct may detect bile leakage, but it cannot detect leakage from caudate branches, which are segregated from the main duct. Thorough saline irrigation to dislodge blood clot on the hilar plate or pressing the transection surface (including the hilar plate) by a piece of clean gauze may help to detect bile leakage. Similar to the graft side, the hilar plate is sutured by 6-0 prolene to close any tiny caudate hepatic duct openings.

Injury to the confluence of hepatic ducts in the donor

During liver transection, on approaching the hilar plate, caution should be exercised to avoid thermal injury to the hepatic duct by diathermy or ultrasonic dissector (Cavitron Ultrasonic Surgical Aspirator, CUSA, Valley Lab, Boulder, CO, USA). The ultrasonic dissector should not be used to dissect the hilar plate from the RHD. The RHD and hilar plate should be considered as one single structure. After closure of the RHD stump in the donor, a third cholangiogram is performed to detect if the closure has narrowed the confluence. If this has occurred, the suture should be taken down and the orifice closed over the horizontal limb of a T-tube (Figure 7.17). The long-term consequence of such repair is not

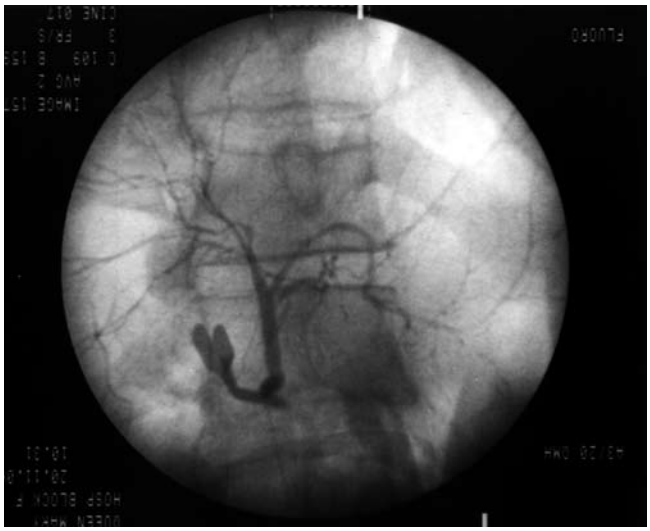

A



B



C

Figure 7.11A-C. Operative cholangiogram shows a left hepatic duct with segment II and III/IV ducts joining to form a single trunk **(A)**; After rotating the X-ray tube in a counterclockwise direction, the segment II and III/IV hepatic ducts were found to be separate **(B)**; The left liver graft was used in this situation. In the recipient, a hepatico-jejunostomy was made to the two ductal orifices **(C)**.

known, but it is preferred to immediate conversion to hepatico-jejunostomy because the injury to the duct wall is not circumferential. However, meticulous long-term follow-up is mandatory to detect early signs of bile duct stenosis. An occasional case of secondary biliary cirrhosis in a donor has been reported.[22] Sometimes, folding of the common hepatic duct on itself may appear as stenosis of the common hepatic duct on the cholangiogram. Stretching of the common bile duct in the caudal direction would produce a better cholangiogram. On other occasions, the left liver might have been pushed much to the left side during the cholangiography, causing stretching of the confluence of the hepatic ducts and

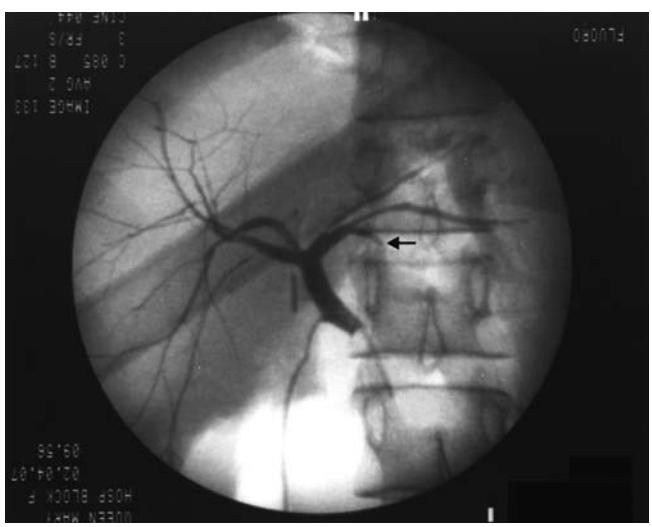

A

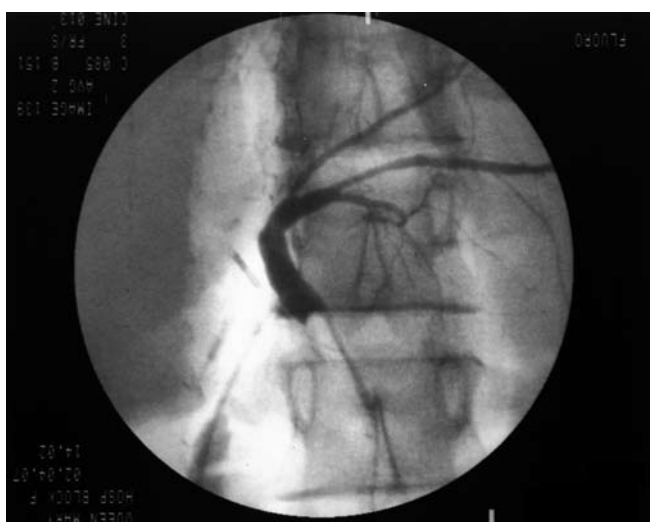

B

Figure 7.12A,B. Cholangiogram by using balloon catheter. All segmental branches were filled by contrast, except segment IV, which was filled for a short segment only (arrow) **(A)**; After graft retrieval, another cholangiogram showed complete filling of all left liver segmental branches **(B)**.

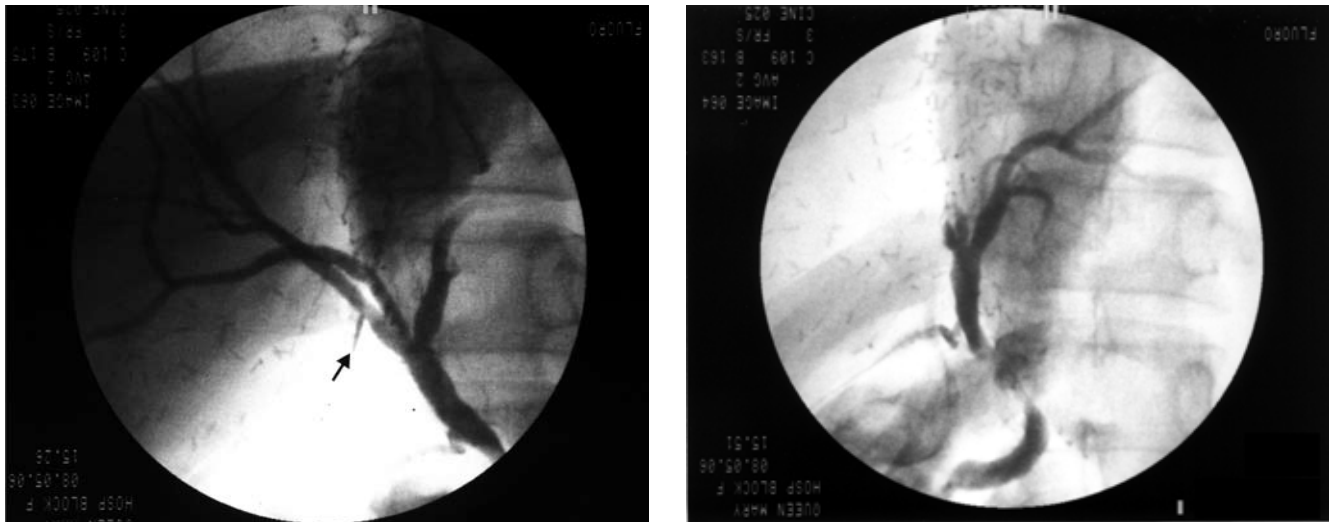

A B

Figure 7.13A,B. Cholangiogram obtained at the time of right hepatic duct division. The metal clip (arrow) was not at the appropriate position. Further cholangiogram was not done before right hepatic duct division. It was assumed that dividing the duct a short distance to the left side of the metal clip would be appropriate **(A)**; After division of the right hepatic duct, two ductal orifices were found on the graft side. The cholangiogram after closure of the stump showed that the mistake could have been avoided **(B)**.

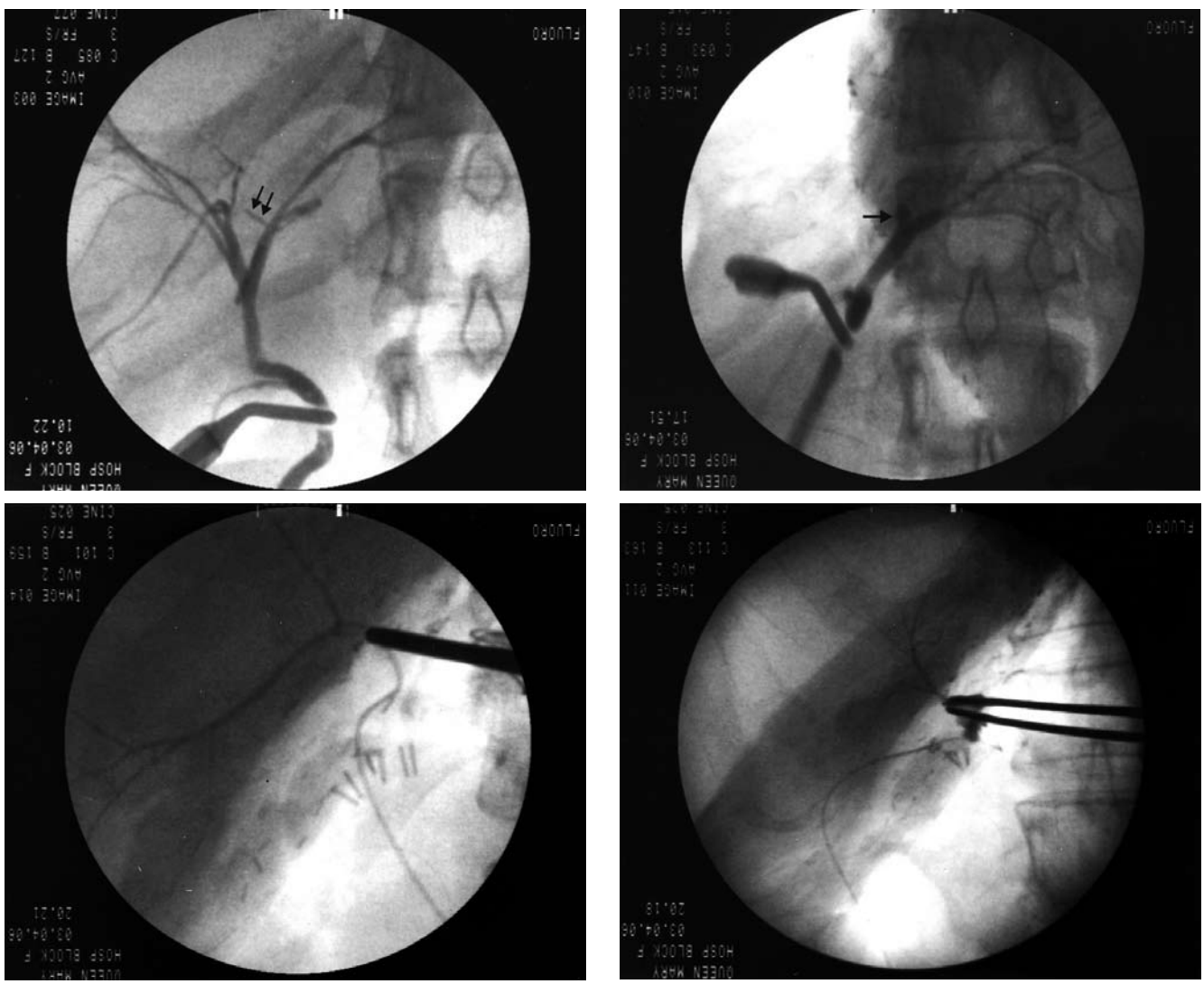

A B C D

Figure 7.14A-D. Failure of accurate placement of the clip (arrows) led to an inaccurate division line of the right hepatic duct and two ductal orifices in the graft. The confluence of the hepatic ducts was low and the clip had been applied to the liver capsule **(A)**; A long right hepatic stump (arrow) was present **(B)**; Cannulation of right anterior and posterior hepatic ducts and cholangiograms were performed for confirmation before biliary reconstruction. The hepatic duct orifices were narrow and the risk of anastomosis stenosis was increased **(C and D)**;



A

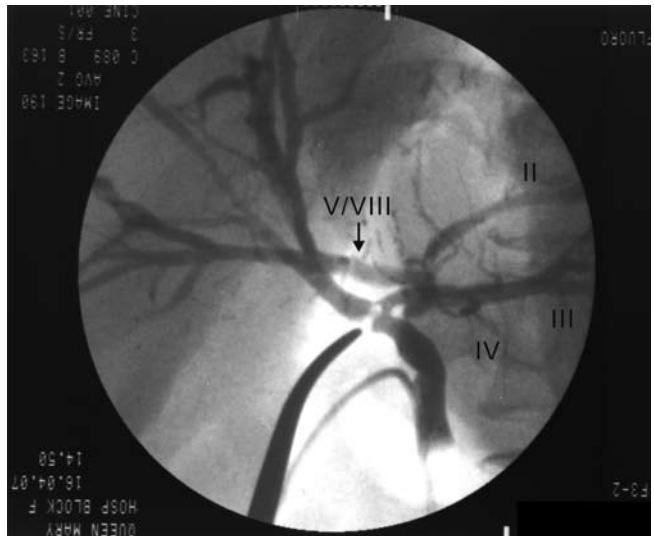

B

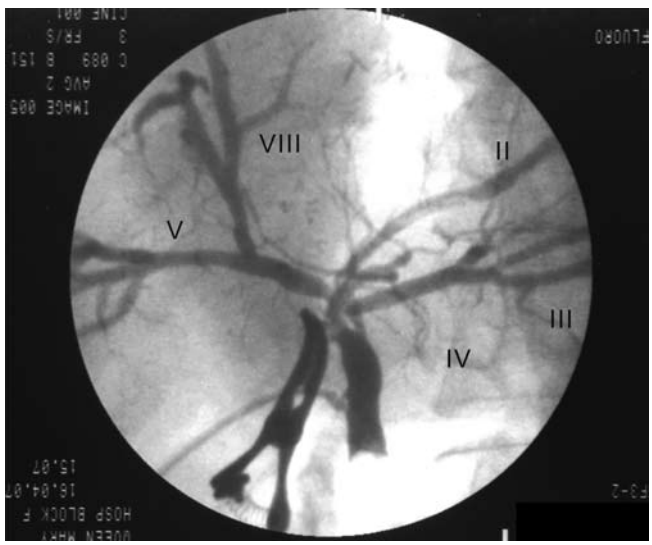

C

Figure 7.15A-C. Cholangiogram showed crowding of hepatic ducts at the liver hilum. The differentiation was not clear even with rotation of the X-ray tube to the right side **(A)**; After separation of the liver, repeated cholangiogram showed a clearer display of the hepatic ducts. The bulldog clamp was at the position of the right posterior hepatic duct **(B)**; After clamping the right posterior hepatic duct, the cholangiogram showed that the segment II, IV and right posterior hepatic ducts had the same confluence, whereas the segment III and right anterior hepatic ducts joined together before draining into the common hepatic duct **(C)**.

false appearance of narrowing (Figures 7.9D and E). Occasionally, a RHA crossing in front of the common hepatic duct may also produce appearance of stenosis when the left liver is displaced to the left side (Figure 7.18). To produce a reassuring cholangiogram, the left liver should be pushed back to its original position.

Preparation of recipient common hepatic duct for duct-to-duct anastomosis

The length and blood supply of the common hepatic duct in the recipient are preserved if a duct-to-duct anastomosis is planned. Therefore, dissection of the common hepatic duct is made near to the hilar plate, and the tissue around the common hepatic duct is preserved. The RHA is dissected in the right liver hilum to preserve the arterial branches that supply the common hepatic duct as the RHA crosses behind it (Figure 7.19). The common hepatic duct is divided close to but not into the hilar plate because the exposed caudate hepatic duct may be missed and responsible for bile leakage afterward. The common hepatic duct is not ligated to preserve length. Bleeding site at the transected duct wall and peridochal tissue is sutured meticulously using fine needles



Figure 7.16. The middle hepatic vein (▷) was dorsal to the segment IV pedicle (arrow). A vertical transection plane would injure the segment IV hepatic duct, which could be a cause of postoperative bile leakage.

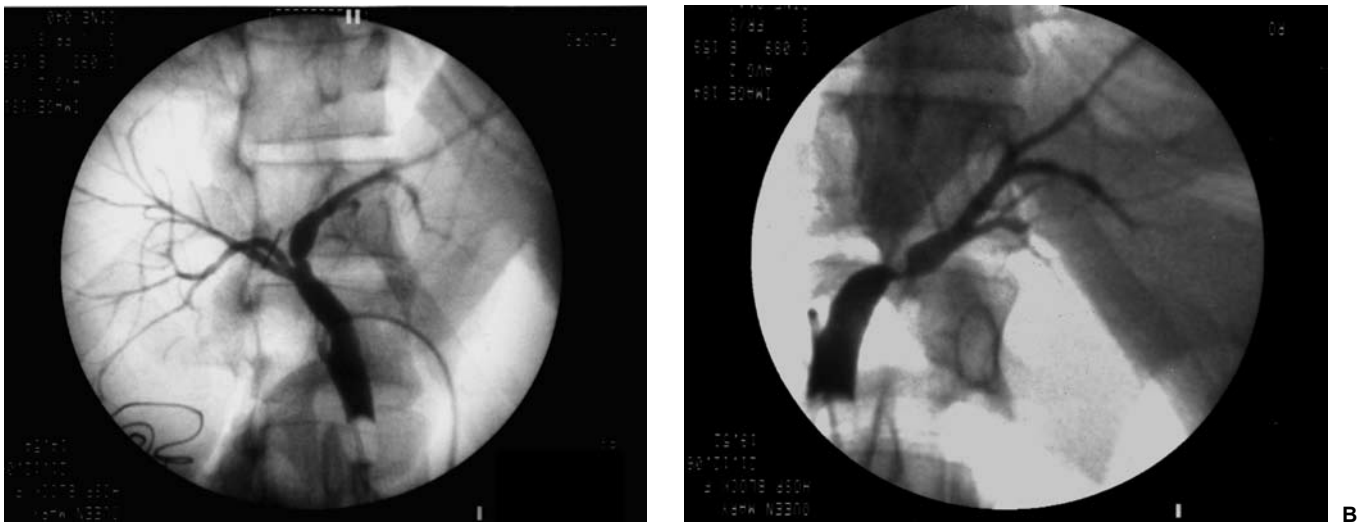

Figure 7.17A-C. Operative cholangiogram showed a short right hepatic duct. The metal clip was not placed at the appropriate position. Further adjustment and cholangiogram were not performed before the duct was divided **(A)**; After closure of the right hepatic duct stump, the cholangiogram showed narrowing of the confluence of the hepatic ducts. The suture was removed and suturing was performed over the transverse limb of a T-tube **(B)**; Cholangiogram showed the T-tube splinting the confluence of the hepatic ducts **(C)**.

rather than coagulation by diathermy. Otherwise, troublesome bleeding may occur during cross-clamping of the portal vein and inferior vena cava. The cystic duct could be cannulated for instillation of diluted methylene blue for bile leakage detection or cholangiogram after completion of duct-to-duct anastomosis (Figure 7.20). The cystic duct can also be preserved for anastomosis if it is large and the graft contains more than one duct orifice.[23] In case a gallstone is present inside the gallbladder or suspected within the common bile duct, we perform choledochoscopy for the lower end of the common bile duct before anastomosis (Figure 7.21).

Duct-to-duct anastomosis

Duct-to-duct anastomosis is the most frequent method nowadays because it can avoid bacterial contamination of the operation field, the operation time is shorter and rapid gastrointestinal tract recovery allows early feeding and oral drug administration. In case of biliary complication, endoscopic intervention via the ampulla can be carried out.

A single duct orifice in the graft is the most favorable type for duct-to-duct anastomosis. In case of two ductal orifices which are close to each other, they can be joined together to form a common orifice.[16] Ductoplasty may not be suitable for duct orifices that are more than 3 mm apart. Approximation of the two duct orifices in this situation may cause tension, ischemia and subsequent stenosis of the anastomosis. Hepatico-jejunostomy is then the preferred method.

The long-term outcome of ductoplasty is not known. Contrary to the experience reported by Shah et al,[8] recently, we have observed a higher incidence of biliary stenosis in patients having ductoplasty (16/42, 38% vs 49/215, 22.7%, P=0.032). It is not known whether the ductoplasty itself or the multiple ductal orifices predisposes to the biliary stenosis. The inference is that the ductoplasty could not eliminate the adverse effect of multiple ductal orifices in the liver graft. A better design is still awaited.

The duct orifice of the graft and common hepatic

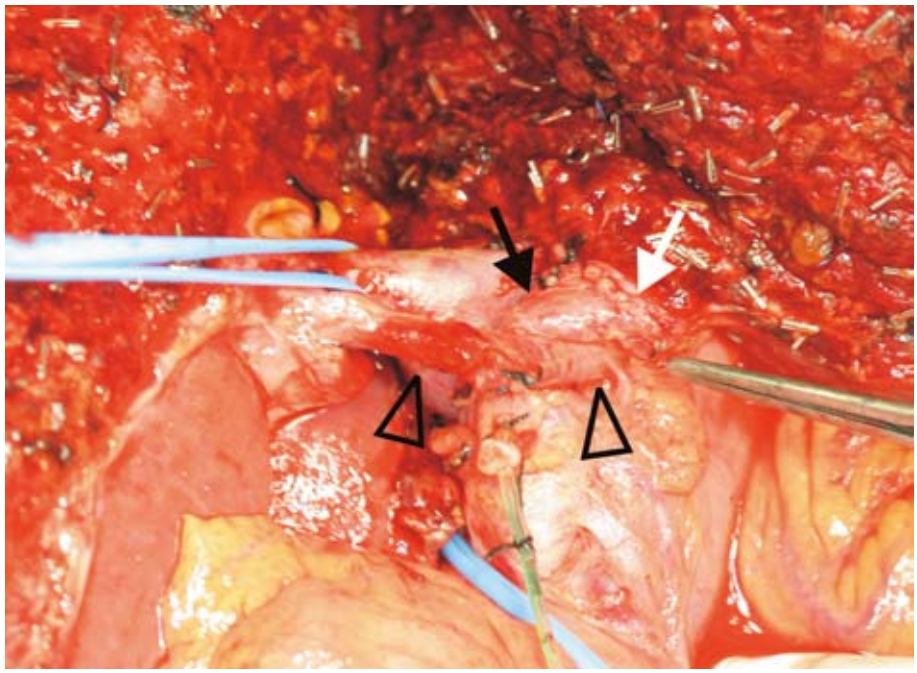

Figure 7.18. The common hepatic duct (black arrow) was kinked by the right hepatic artery (▷), which was anterior to it. A cholangiogram obtained at this time might produce a false perception that the common hepatic duct was occluded after suturing of the right hepatic duct stump. The white arrow points to the right hepatic duct suture line.

duct may not match in size. Usually, it is the recipient common hepatic duct that is larger. It may be necessary to close part of the common hepatic duct orifice. However, it should not be done exactly to the same diameter as the graft duct orifice because partial closure may narrow its antero-posterior diameter, rendering the common hepatic duct smaller in size than desired (Figure 7.22). Occasionally, the graft duct orifice is larger than the recipient common hepatic duct. If the confluence of the RHD and LHD of the recipient has been preserved, opening of the confluence to form a single opening may allow better matching with the graft ductal orifice. In case of low confluence of the hepatic ducts, the graft duct orifice is joined to the RHD and LHD of the recipient as a single orifice.

Duct-to-duct anastomosis is also applicable to the left liver graft operation[24] (Figure 7.23).

The major controversies of duct-to-duct anastomosis are the suturing method, suture material and use of stent.

Suturing method

Interrupted sutures are preferred to avoid strangling the ductal wall. However, for the posterior wall, difficulty may be encountered on placing the knots outside the lumen. Therefore, many surgeons prefer to employ continuous suturing at the posterior wall. It is simpler to do so, but gentle pulling of the suture is needed to avoid tissue strangulation. Interrupted sutures are placed at the anterior wall. The space between the sutures is about 1 mm. A prospective randomized comparative study of the continuous suturing method with the interrupted suturing method has not been done. It is therefore not known which type of suturing is better. A retrospective analysis suggested that both methods yield similar outcomes,[25] but another retrospective study showed that continuous anastomosis tended to be associated with a high incidence of stenosis in duct-to-duct anastomosis.[9] Since there could be many factors affecting biliary complications, a single factor may not substantially alter the outcome. Perhaps careful handling of tissue during suturing is equally important as the blood supply of the ductal wall. Crushing injury to the ductal wall

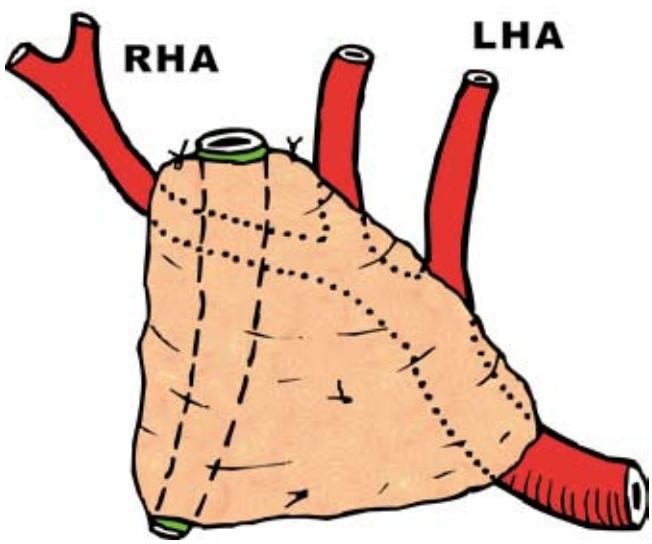

Figure 7.19. Preservation of arterial supply to the common hepatic duct. The right hepatic artery (RHA) is dissected preferably in the right liver hilum. The tissue around the common hepatic duct and the arterial branches are preserved. LHA, left hepatic artery.

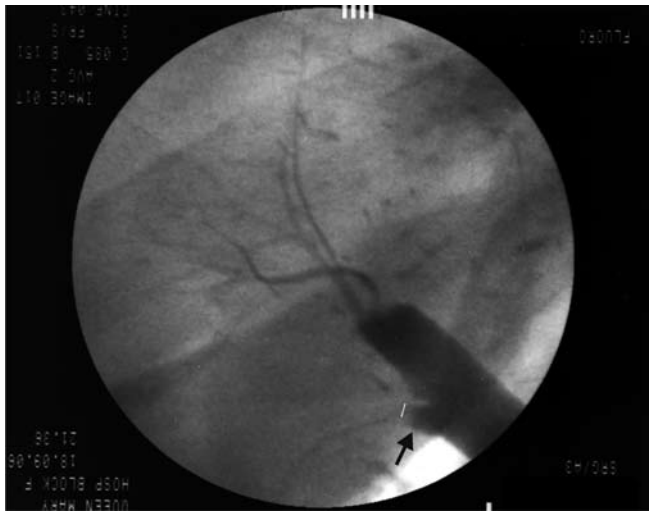

Figure 7.20. Postoperative cholangiogram via cystic duct cannulation (arrow). In this case, the graft ductal orifice was in the form of a single cuff with two orifices.

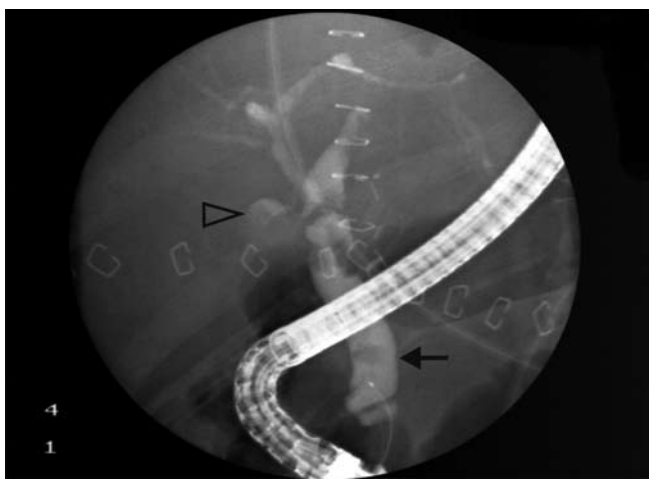

Figure 7.21. Endoscopic retrograde cholangiogram shows a stone in the common bile duct (arrow) and leakage (▷) from the anastomosis of a patient after transplantation.

by forceps should be avoided. Therefore, the ductal wall should not be picked up by the forceps directly during suturing.

The anastomosis is normally performed under 2.5 times loupe magnification. The operating microscope has been used for accurate placement of sutures. Whether it will decrease the biliary complication rate is not known.

Suture material

The choice is between prolene and PDS. Intuitively, PDS is the material of choice, but there is suspicion that in the presence of steroid, the PDS suture could not hold the tissues together for long duration, leading to impaired wound healing and leakage. Therefore, prolene has been used for biliary anastomosis.[6,26,27] The additional advantages are that bacterial adherence to prolene is less and prolene induces less inflammatory changes and therefore less fibrosis. However, on re-exploration of cases of biliary leakage or stenosis, we found prolene sutures inside the lumen and encrustation upon it. Similar finding has been reported by Tsujino et al.[28] It is not known whether the non-absorbable suture material migrates into the lumen or is simply dislodged into it upon ductal wall necrosis. If duct ischemia or necrosis is the reason for anastomotic stenosis, the latter is the more likely explanation.

Up to now, there has not been any prospective randomized study showing that one type of suture material is better than the others. In animal experiments, the use of absorbable or non-absorbable materials makes no difference in the outcome.[29] Currently, we have been using PDS for construction of biliary anastomosis since we stopped using steroid in the postoperative period.[30]

Stenting of anastomosis

Due to the small size of the RHD, stenting is thought to be necessary.[31,32] Its presence may facili-

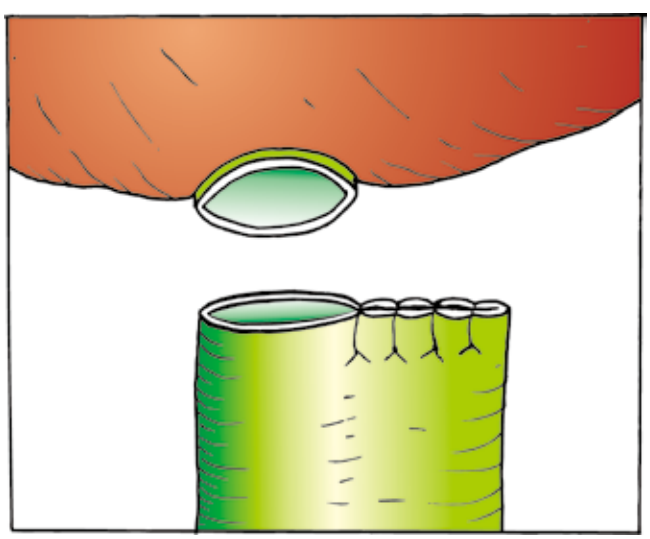

Figure 7.22. Closure of the common hepatic duct to the same transverse diameter as that of the graft ductal orifice may narrow the antero-posterior dimension of the common hepatic duct, rendering the orifice of the common hepatic duct smaller than expected. Such method is therefore not advisable.

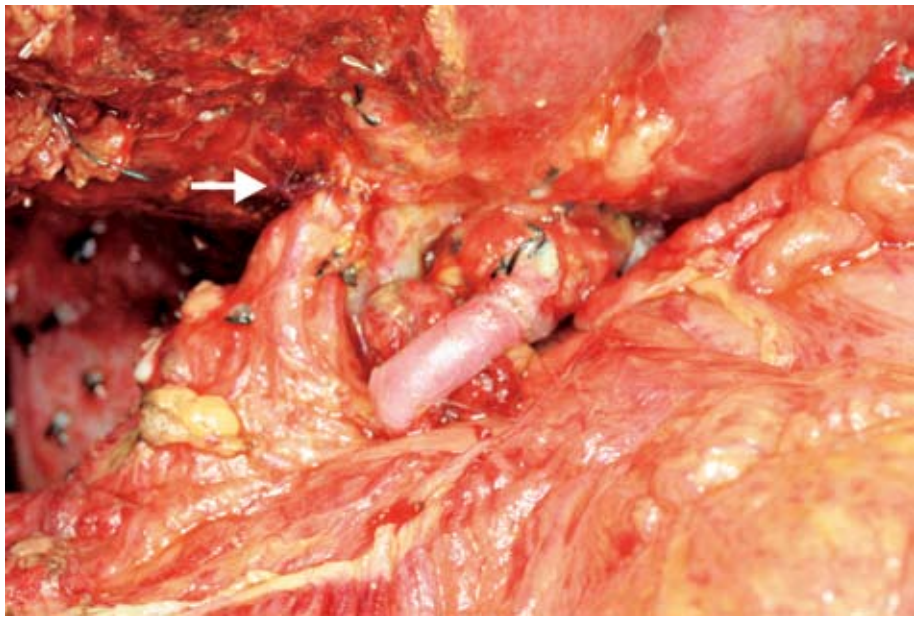

Figure 7.23. Operative photo shows the completion of duct-to-duct anastomosis (arrow) in left liver living donor liver transplantation.

tate accurate placement of sutures but may not prevent leakage. Whether it can prevent anastomosis stenosis is not known. Its presence may predispose to obstruction of duct because of encrustation. It may be used if the RHD is very small, e.g. 2 mm. An external type of stent is preferred for subsequent early removal. The exit of the stent may be via the cystic duct, anterior wall of the common hepatic duct or ampulla. We prefer not to use any stent. The incidences of leakage and stenosis without stenting are 7% and 24%, respectively,[33] which are not significantly higher than that when a stent is used.[31,34] A prospective randomized study to determine the role of the stent is not yet available.

The presence of the stent inside a normal biliary tract may induce sludge formation either within or outside the stent. If an external stent has been used, it is preferred that it is always kept opened and removed early when anastomosis healing is thought to be complete or secure. Plugging the external stent with the hope that bile will return to the gastrointestinal tract is wrong. The patient will suffer from acute cholangitis because encrustation within or outside the stent may have occluded the anastomosis.

Hepatico-jejunostomy

Hepatico-jejunostomy is used when the recipient common hepatic duct is not suitable for anastomosis or when the graft contains two or more ductal orifices that are far apart and not suitable for ductoplasty. To make a good anastomosis, an opening of the jejunum of the exact size as the ductal orifice is made by cutting current rather than coagulation current.[16] In case of two or more hepatic duct orifices, the distance between the openings of the jejunum should be at least three times of the distance between the hepatic duct openings because contraction of bowel after openings are made will lead to difficulty in placement of sutures (Figure 7.24). The posterior wall is constructed by continuous sutures, whereas the anterior wall is formed by interrupted sutures. The Roux loop is brought up through a window of transverse mesocolon. If feasible, a retrogastric route is preferred for its straight path. After jejunojejunostomy, the mesocolon window and mesenteric gap are meticulously closed using non-absorbable material, because we have observed several cases of dehiscence of mesenteric window which were sutured by absorbable

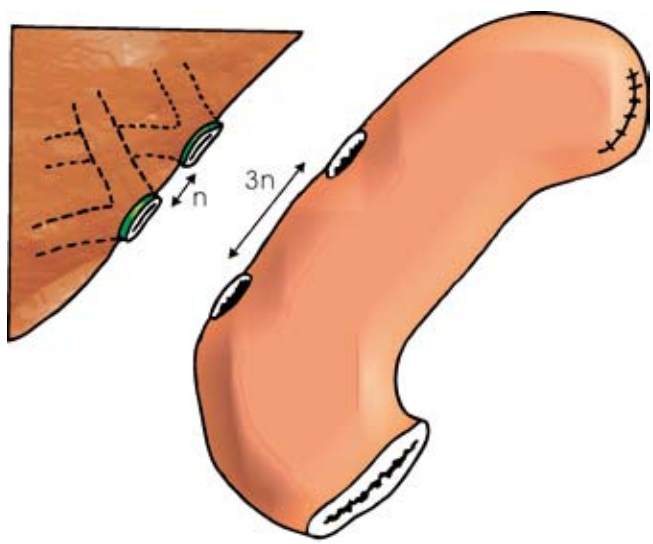

Figure 7.24. The distance between the jejunal openings should be at least three times of the distance between the ductal orifices.

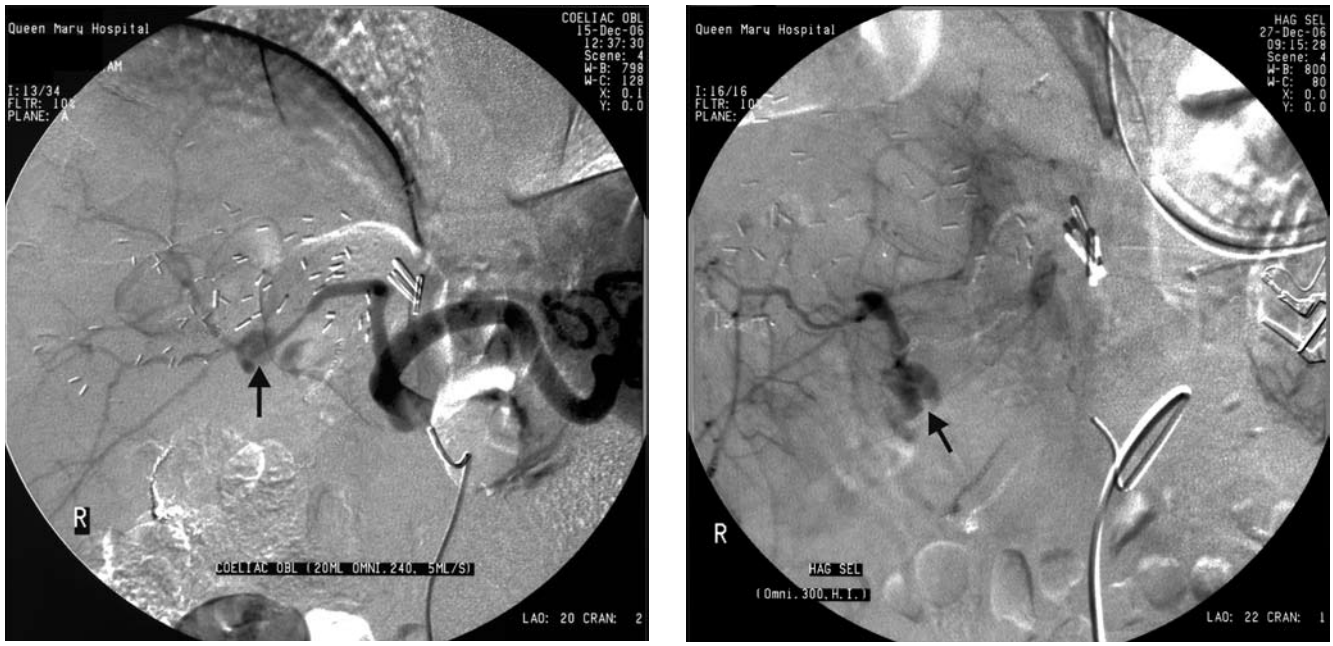

A B

Figure 7.25A,B. Hepatic angiogram was done in a patient with obstructive jaundice and gastrointestinal bleeding several months after right liver living donor liver transplantation and hepatico-jejunostomy. Hepatic angiogram shows a pseudoaneurysm of the hepatic artery (arrow), likely at the anastomosis **(A)**; There was bleeding into the jejunal lumen (arrow). Exploration showed an abscess cavity next to the right hepatic duct orifice, which was necrotic. A bleeding point was found in the wall of the abscess cavity. The complication was likely a result of bile leakage leading to abscess formation and erosion into the adjacent hepatic artery and jejunum. At laparotomy, the bleeding point was sutured by 6-0 prolene, the anastomosis was taken down, the graft duct orifice was intubated. Another hepatico-jejunostomy was performed 8 weeks later successfully **(B)**.

material[35] in patients who had been given steroid. If the division of the mesentery has been long and deep into the root, there may be a third window near the root of mesentery that must be closed.

The hepatico-jejunostomy is a more prolonged procedure than duct-to-duct anastomosis. If bile leakage occurs, the outcome is more devastating because unlike the situation of duct-to-duct anastomosis, intestinal content also leaks into the peritoneal cavity. Abscess and acute cholangitis may occur. Sometimes, the abscess may erode into the hepatic artery causing pseudoaneurysm (Figure 7.25) or the surrounding inflammatory changes may predispose to portal vein stenosis. Sometimes, the hepatico-jejunostomy is difficult to construct because the small intestine remains edematous after a prolonged period of portal vein clamping. A recent prospective randomized trial suggested that hepatico-jejunostomy carries a worse result.[36] We have similar experience (Table 7.1), but four other studies, though retrospective, showed that hepatico-jejunostomy is superior[6,37-39] and one study showed similar outcome between the two methods.[8] However, the situation leading to a choice of one procedure over the other is variable from case to case. Therefore, it is impossible to conclude that one procedure is definitely inferior to the other. A flexible approach is needed, especially if there are more than one hepatic duct opening in the graft.

Bile leakage in the recipient

Bile leakage may be occult or obvious. An abdomi-

Table 7.1. Biliary complications in right liver living donor liver transplantation at Queen Mary Hospital, The University of Hong Kong.

	HJ (n=82)	Duct-to-duct anastomosis (n=164)	Combined HJ and duct-to-duct (n=7)
Bile leakage	6 (7.3%)	9 (5.5%)	0 (0%)
Anastomosis stenosis	25 (30.5%)	33 (20.1%)	2 (28.6%)

HJ, hepatico-jejunostomy

nal drainage tube may not be useful for detection of bile leakage. If a biliary drainage tube is present, the cholangiogram may demonstrate the site of leakage. Even with a normal cholangiogram, when the patient's serum bilirubin level does not normalize, or when sepsis appears, bile leakage must be excluded as the responsible cause. CT scan may detect large collection. Minor bile leakage may defy detection by CT scan but could significantly affect the clinical course. In other words, the decision of re-laparotomy should be based on clinical judgment alone.

Bile leakage may occur from the liver transection surface, the anastomosis itself, the hilar plate (caudate branches) of the graft or caudate branches that are missed on the recipient's RHD or LHD. The segment Ir caudate branch at the inferior part of the liver transection surface may also be the source of bile leakage. At laparotomy, the leakage site from the hilar plate should be sutured by non-absorbable material. If leakage occurs from anastomosis, re-construction should be considered. On many occasions, leakage from the anastomosis is not simply a technical problem. Rather, the graft RHD stump is necrotic, rendering re-anastomosis impossible. It may be possible to construct the anastomosis over the splintage tube if necrosis is not circumferential. In other cases, it would be better to disconnect the anastomosis and intubate the graft ductal orifices and allow fibrosis to set in around the tube and consider reconstruction 2–3 months later. The advantage is that sepsis would be better controlled especially when the patient has a previous hepatico-jejunostomy. The disadvantage is that bile is no longer present inside the gastrointestinal tract. Re-feeding of bile via a fine bore tube placed through the nose and with the tip in the duodenum (if the patient can tolerate) is recommended to eliminate all the adverse effects of absence of bile in the intestine.

Minor leakage from the anastomosis may be concealed and responsible for the late anastomosis stenosis. Minor leakage may come from suture holes, which are present if a large-size needle is used or when tension exists along the suture line. Minor leakage may also exist if there is minor ischemia or traction injury after anastomosis. Traction injury may occur if much manipulation is made for hemostasis. Therefore, during rotation of the liver graft and exposure of hepatoduodenal ligament for hemostasis, the manipulation must be gentle. To avoid traction injury to the anastomosis, complete hemostasis must be made before biliary reconstruction. However, there are patients in whom hemostasis is difficult and incomplete until the liver graft regains functions and therefore bleeding may continue or recur after biliary reconstruction. Previous studies indicate that a high Model for End-stage Liver Disease score[33] or serum bilirubin level[1] are predictors of biliary complications. They are patients with poor premorbid condition and coagulopathy. It is not unlikely that complete hemostasis in this group requires much liver graft rotation and therefore the biliary anastomosis sustains traction injury. An additional adverse effect of hyperbilirubinemia is that a high unconjugated bilirubin level may impair fibroblast replication.[40]

Anastomotic stenosis

Late anastomosis stenosis occurs in about 20%–30% of patients.[9] The incidence is quite high and disturbing. The etiology could be multifactorial including ischemia of the RHD in the graft or common hepatic duct in the recipient, prolonged cold/warm ischemic time, intraoperative or postoperative prolonged hypotension, postoperative hepatic artery complications, cytomegalovirus infection,[6] minor bile leakage, tissue trauma and inaccurate matching of the size of the duct openings. Liver biochemistry abnormality is the hint to the development of stenosis, but acute cholangitis is the usual presentation. Endoscopic retrograde cholangiopancreatography and balloon dilatation would be useful for patients with duct-to-duct reconstruction, but it may be difficult if stricture extends into the graft and segregates the right anterior and posterior hepatic ducts. Percutaneous transhepatic biliary drainage (PTBD) is the alternative. However, it carries the risk of damaging the portal vein and hepatic artery because the intrahepatic ducts are not very dilated and difficult to aim at. Complications such as hemobilia, pseudoaneurysm of the hepatic artery, arterio-portal fistula, and portal vein thrombosis have been reported.[16] In view of the risk of repeated PTBD, we advocate early re-laparotomy and hepatico-jejunostomy once stenosis is difficult to dilate or the guidewire could

not be negotiated through the stricture. During laparotomy, the location of stenosis could be determined by palpation of the PTBD tube or instillation of methylene blue. Conversion of duct-to-duct anastomosis to hepatico-jejunostomy should be considered in most of the cases. During the re-laparotomy, the hepatic artery is vulnerable to damage. Dissection at the liver hilum has to be performed carefully. The long-term outcome of re-laparotomy and reconstruction is satisfactory. About 70% of patients are free from recurrence of stenosis or cholangitis afterward.

Our current results

The biliary complication rate in the early part of our series was quite high and devastating. Leakage and stenosis occurred in 52% in the first 37 patients. After recognition of the possible causes of leakage, the leakage rate was markedly reduced, but late stenosis still occurred. The overall biliary complication rate in the subsequent patients (No. 38–257) was 20.4% ($P<0.05$ compared with the first 37 patients). There is a decrease in the complication rate over the years as experience accumulated. The complication rate has decreased from 30.6% of the cases No. 38–100 to 16.6% of the cases No. 101–257 ($P<0.05$). However, it must be noted that biliary stenosis may occur several years later. Longer follow-up is required to ascertain a valid comparison. Nevertheless, an improvement of the early result has indeed been observed.

Conclusion

Many of the factors leading to complications of biliary tract in donors and recipients are now recognized. Theoretically, they are preventable but case-to-case variation could be large. To achieve optimum results, the surgeon must be conversant with the biliary anatomy and meticulous in all steps of the transplant operation.

References

1. Qian YB, Liu CL, Lo CM, Fan ST. Risk factors for biliary complications after liver transplantation. Arch Surg 2004; 139: 1101-1105.
2. Lo CM, Fan ST, Liu CL, Wei WI, Lo RJ, Lai CL, Chan JK, Ng IO, Fung A, Wong J. Adult-to-adult living donor liver transplantation using extended right lobe grafts. Ann Surg 1997; 226: 261-269.
3. Grewal HP, Shokouh-Amiri MH, Vera S, Stratta R, Bagous W, Gaber AO. Surgical technique for right lobe adult living donor liver transplantation without venovenous bypass or portocaval shunting and with duct-to-duct biliary reconstruction. Ann Surg 2001; 233: 502-508.
4. Olthoff KM, Merion RM, Ghobrial RM, Abecassis MM, Fair JH, Fisher RA, Freise CE, Kam I, Pruett TL, Everhart JE, Hulbert-Shearon TE, Gillespie BW, Emond JC; A2ALL Study Group. Outcomes of 385 adult-to-adult living donor liver transplant recipients: a report from the A2ALL Consortium. Ann Surg 2005; 242: 314-323.
5. Pomposelli JJ, Verbesey J, Simpson MA, Lewis WD, Gordon FD, Khettry U, Wald C, Ata S, Morin D, Garrigan K, Jenkins RL, Pomfret EA. Improved survival after live donor adult liver transplantation (LDALT) using right lobe grafts: program experience and lessons learned. Am J Transplant 2006; 6: 589-598.
6. Kasahara M, Egawa H, Takada Y, Oike F, Sakamoto S, Kiuchi T, Yazumi S, Shibata T, Tanaka K. Biliary reconstruction in right lobe living-donor liver transplantation: Comparison of different techniques in 321 recipients. Ann Surg 2006; 243: 559-566.
7. Yazumi S, Yoshimoto T, Hisatsune H, Hasegawa K, Kida M, Tada S, Uenoyama Y, Yamauchi J, Shio S, Kasahara M, Ogawa K, Egawa H, Tanaka K, Chiba T. Endoscopic treatment of biliary complications after right-lobe living-donor liver transplantation with duct-to-duct biliary anastomosis. J Hepatobiliary Pancreat Surg 2006; 13: 502-510.
8. Shah SA, Grant DR, McGilvray ID, Greig PD, Selzner M, Lilly LB, Girgrah N, Levy GA, Cattral MS. Biliary strictures in 130 consecutive right lobe living donor liver transplant recipients: results of a Western center. Am J Transplant 2007; 7: 161-167.
9. Soejima Y, Taketomi A, Yoshizumi T, Uchiyama H, Harada N, Ijichi H, Yonemura Y, Ikeda T, Shimada M, Maehara Y. Biliary strictures in living donor liver transplantation: incidence, management, and technical evolution. Liver Transpl 2006; 12: 979-986.
10. Liu CL, Fan ST, Lo CM, Wei WI, Chan SC, Yong BH, Wong J. Operative outcomes of adult-to-adult right lobe live donor liver transplantation: a comparative study with cadaveric whole-graft liver transplantation in a single center. Ann Surg 2006; 243: 404-410.
11. Vellar ID. Preliminary study of the anatomy of the venous drainage of the intrahepatic and extrahepatic bile ducts and its relevance to the practice of hepatobiliary surgery. ANZ J Surg 2001; 71: 418-422.
12. Stapleton GN, Hickman R, Terblanche J. Blood supply of the right and left hepatic ducts. Br J Surg 1998; 85: 202-207.
13. Gunji H, Cho A, Tohma T, Okazumi S, Makino H, Shuto K, Mochizuki R, Matsubara K, Hayano K, Mori C, Murakami G, Ochiai T. The blood supply of the hilar bile duct and its relationship to the communicating arcade located between the right and left hepatic arteries. Am J Surg 2006; 192: 276-280.
14. Couinaud C. The parabiliary venous system. Surg Radiol Anat 1988;10: 311-316.
15. Ohkubo M, Nagino M, Kamiya J, Yuasa N, Oda K, Arai T, Nishio H, Nimura Y. Surgical anatomy of the bile ducts at the hepatic hilum as applied to living donor liver transplantation. Ann Surg 2004; 239: 82-86.
16. Fan ST, Lo CM, Liu CL, Tso WK, Wong J. Biliary reconstruction and complications of right lobe live donor liver transplantation. Ann Surg 2002; 236: 676-683.
17. Liu CL, Lo CM, Chan SC, Tso WK, Fan ST. The right may not be always right: biliary anatomy contraindicates right lobe live donor liver transplantation. Liver Transpl 2004; 10: 811-812.

18. Nimura Y, Hayakawa N, Kamiya J, Kondo S, Shionoya S. Hepatic segmentectomy with caudate lobe resection for bile duct carcinoma of the hepatic hilus. World J Surg 1990; 14: 535-544.
19. Yeh BM, Breiman RS, Taouli B, Qayyum A, Roberts JP, Coakley FV. Biliary tract depiction in living potential liver donors: comparison of conventional MR, mangafodipir trisodium-enhanced excretory MR, and multi-detector row CT cholangiogrpahy – initial experience. Radiology 2004; 230: 645-651.
20. Takatsuki M, Eguchi S, Tokai H, Hidaka M, Soyama A, Tajima Y, Kanematsu T. A secured technique for bile duct division during living donor right hepatectomy. Liver Transpl 2006; 12: 1435-1436.
21. Testa G, Malago M, Porubsky M, Marinov M, Sankary H, Oberholzer J, Nadalin S, Benedetti E. Hilar early division of the hepatic duct in living donor right hepatectomy: the probe-and-clamp technique. Liver Transpl 2006; 12: 1337-1341.
22. Morelli G, Reed A, Firpi RJ, Machicao V, Abdelmalek MF, Soldevilla-Pico C, Nelson DR. Late presentation of a biliary tract complication after right hepatic donation resulting in secondary biliary cirrhosis. Liver Transpl 2006; 12: 306-309.
23. Asonuma K, Okajima H, Ueno M, Takeichi T, Zeledon Ramirez ME, Inomata Y. Feasibility of using the cystic duct for biliary reconstruction in right-lobe living donor liver transplantation. Liver Transpl 2005; 11: 1431-1434.
24. Soejima Y, Shimada M, Suehiro T, Kishikawa K, Minagawa R, Hiroshige S, Ninomiya M, Shiotani S, Harada N, Sugimachi K. Feasibility of duct-to-duct biliary reconstruction in left-lobe adult-living-donor liver transplantation. Transplantation 2003; 75: 557-559.
25. Castaldo ET, Pinson CW, Feurer ID, Wright JK, Gorden DL, Kelly BS, Chari RS. Continuous versus interrupted suture for end-to-end biliary anastomosis during liver transplantation gives equal results. Liver Transpl 2007; 13: 234-238.
26. Azoulay D, Marin-Hargreaves G, Castaing D, ReneAdam, Bismuth H. Duct-to-duct biliary anastomosis in living related liver transplantation: the Paul Brousse technique. Arch Surg 2001; 136: 1197-1200.
27. Wilson BJ, Marsh JW, Makowka L, Stieber AC, Koneru B, Todo S, Tzakis A, Gordon RD, Starzl TE. Biliary tract complications in orthotopic adult liver transplantation. Am J Surg 1989; 158: 68-70.
28. Tsujino T, Sugawara Y, Kawabe T, Makuuchi M, Omata M. Foreign body (suture thread) in the bile duct after living donor liver transplantation. Liver Transpl 2007; 13: 1065-1066.
29. Wong FL, Wei WI. Histologic and scanning electron microscopic study of bile duct healing. Asian J Surg 2001; 24: 7-10.
30. Liu CL, Fan ST, Lo CM, Chan SC, Ng IO, Lai CL, Wong J. Interleukin-2 receptor antibody (basiliximab) for immunosuppressive induction therapy after liver transplantation: a protocol with early elimination of steroids and reduction of tacrolimus dosage. Liver Transpl 2004; 10: 728-733.
31. Ishiko T, Egawa H, Kasahara M, Nakamura T, Oike F, Kaihara S, Kiuchi T, Uemoto S, Inomata Y, Tanaka K. Duct-to-duct biliary reconstruction in living donor liver transplantation utilizing right lobe graft. Ann Surg 2002; 236: 235-240.
32. Takatsuki M, Yanaga K, Okudaira S, Furui J, Kanematsu T. Duct-to-duct biliary reconstruction in adult-to-adult living donor liver transplantation. Clin Transplant 2002; 16: 345-349.
33. Liu CL, Lo CM, Chan SC, Fan ST. Safety of duct-to-duct biliary reconstruction in right-lobe live-donor liver transplantation without biliary drainage. Transplantation 2004; 77: 726-732.
34. Kobayashi T, Sato Y, Yamamoto S, Takeishi T, Oya H, Hirano K, Nakatsuka H, Watanabe T, Hatakeyama K. Characteristics of biliary reconstruction, using a T-tube, as compared to those with other methods, in left-lobe adult living-donor liver transplantation. J Hepatobiliary Pancreat Surg 2007; 14: 177-182.
35. Liu CL, Lo CM, Chan SC, Fan ST, Wong J. Internal hernia of small bowel after right lobe live donor liver transplantation. Clin Transplant 2004; 18: 211-213.
36. Malago M, Liu C, Paul A, Nadalin S, Lang H, Broelsch CE. Prospective randomized study of hepaticojejunostomy versus duct-duct anastomosis in right living donor liver transplantation (Abstract). Proceedings of the 11th Annual Congress of the International Liver Transplantation Society, Los Angeles, USA, 2005: LB-6.
37. Suh KS, Yi NJ, Cho JY, Kwon CH, Lee KU. Hepaticojejunostomy shows better long-term outcome than duct-to-duct anastomosis in adult living donor liver transplantation (Abstract). Proceedings of the 11th Annual Congress of the International Liver Transplantation Society, Los Angeles, USA, 2005: 27.
38. Hwang S, Lee SG, Sung KB, Park KM, Kim KH, Ahn CS, Lee YJ, Lee SK, Hwang GS, Moon DB, Ha TY, Kim DS, Jung JP, Song GW. Long-term incidence, risk factors, and management of biliary complications after adult living donor liver transplantation. Liver Transpl 2006; 12: 831-838.
39. Yi NJ, Suh KS, Cho JY, Kwon CH, Lee KU. In adult-to-adult living donor liver transplantation hepaticojejunostomy shows a better long-term outcome than duct-to-duct anastomosis. Transpl Int 2005; 18: 1240-1247.
40. Taube M, Elliot P, Ellis H. Toxicity of bilirubin and bilirubin diglucuronide to rat tissue culture fibroblasts. Eur Surg Res 1998; 20: 190-194.

8. Small-for-size graft and injury

Small-for-size graft injury has been a major concern in designing the liver graft for living donor liver transplantation (LDLT). Virtually, all living donor liver grafts in adult recipients are small-for-size and such grafts may sustain serious damage on reperfusion. The degree of injury is probably inversely proportional to the graft size. Not well-defined, however, is the lowest limit of the graft size beyond which repair and regeneration are impossible and the graft is no longer salvageable. Many cases of graft failure in the early attempts of adult-to-adult LDLT were ascribed to small-for-size graft injury. On hindsight, graft size may not be the only critical factor in these failed cases. Better understanding of the mechanisms of small-for-size graft injury in recent years has modified the concept and improved the outcome.

Minimum graft size required for a recipient

Apart from isolated studies showing that the patient might survive with a graft of 25% of the estimated standard liver volume (ESLV)[1] or 0.49% of the body weight,[2] it is generally accepted that a graft that provides 40% of the ESLV or estimated standard liver weight (ESLW)[3,4] or 0.8%–0.85% of the body weight of the recipient[2] is necessary for recipient survival. Such numbers were based on small-scale clinical studies but appear to stand the test of time. To be truly scientific, the most important question would be: how is the ESLV or ESLW derived? Earlier studies that utilized postmortem liver specimen provided weight (g) as the end-product,[5] whereas recent studies that utilized imaging of the liver provide volume (mL) as the end-product.[6] It has been assumed that weight and volume of the liver are equivalent but, in fact, based on our study using computed tomography volumetry and graft weight measured at the back table, a conversion factor 1.19 mL/g is required.[7] Moreover, data derived from different races may not be applicable to each other.[8,9] The liver size is also affected by the age and sex of the population, with older people and females having smaller liver volumes.[10-12] The scientific value of some of the formulae is doubtful because the estimations of body surface area were based on the formula of DuBois and DuBois,[13] which was based on 9 subjects spanning a wide age range and a study carried out in 1916. Errors of using the ESLV could be reduced by using the patient's own body weight as a denominator. However, the patient's body weight may fluctuate and depends on the amount of fluid retained rather than the true lean body mass. Whatever formula or denominator is used, researchers must be aware of the latent deficiency.

Definitions

Small-for-size graft is defined as graft size smaller than the required liver weight or volume. Small-for-size graft injury means injury related to the graft size on top of ischemia-reperfusion injury. Small-for-size syndrome is thought to be related to the small graft and manifests as coagulopathy, encephalopathy, intractable ascites and prolonged jaundice.[14] Patients surviving the graft injury showed recovery from encephalopathy and coagulopathy in the early postoperative period, but intractable ascites and cholestasis may demand prolonged hospitalization for 2–3 months.

Histopathological changes

The histopathological features of small-for-size graft injury include hepatocyte ballooning, steatosis, apoptosis, sinusoidal congestion,[14,15] endothelial denudation, and focal hemorrhage into the portal tract[16] in the early postoperative period (Figures 8.1 and 8.2), and parenchymal cholestasis in the later period. Portal tract infiltration by inflammatory cells is present.[17]

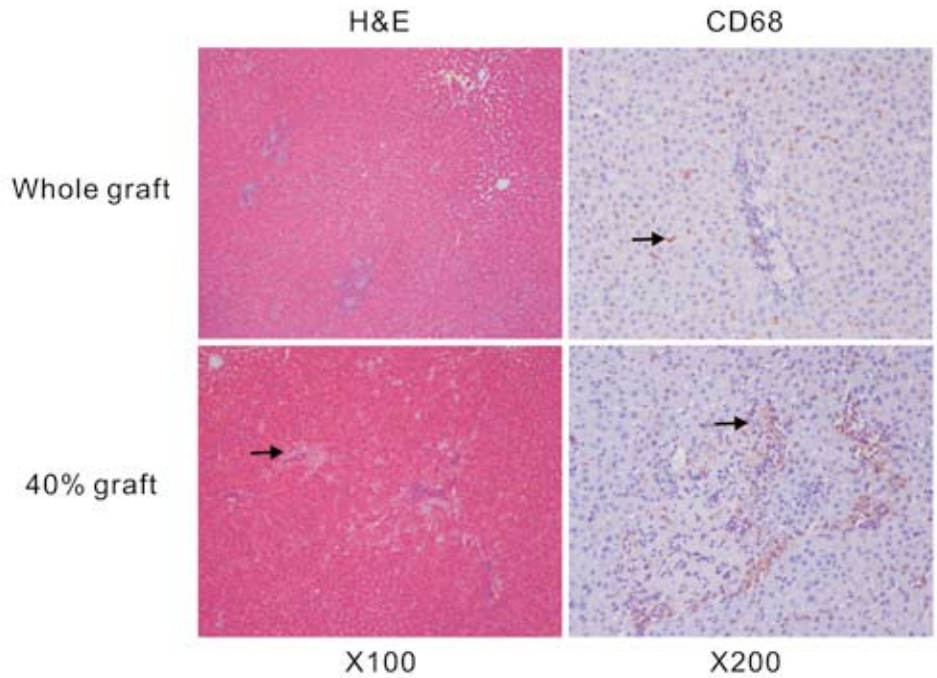

Figure 8.1. Histology of the small-for-size (40%) liver graft in the early phases after reperfusion (24 hours) shows scattered areas of necrosis and macrophage infiltration of portal tract (CD68 immunohistochemical staining). The specimen was obtained from a rat experiment. Arrows indicate necrotic areas by hematoxylin and eosin (H&E) staining and $CD68^+$ cells by immunohistochemistry, respectively.

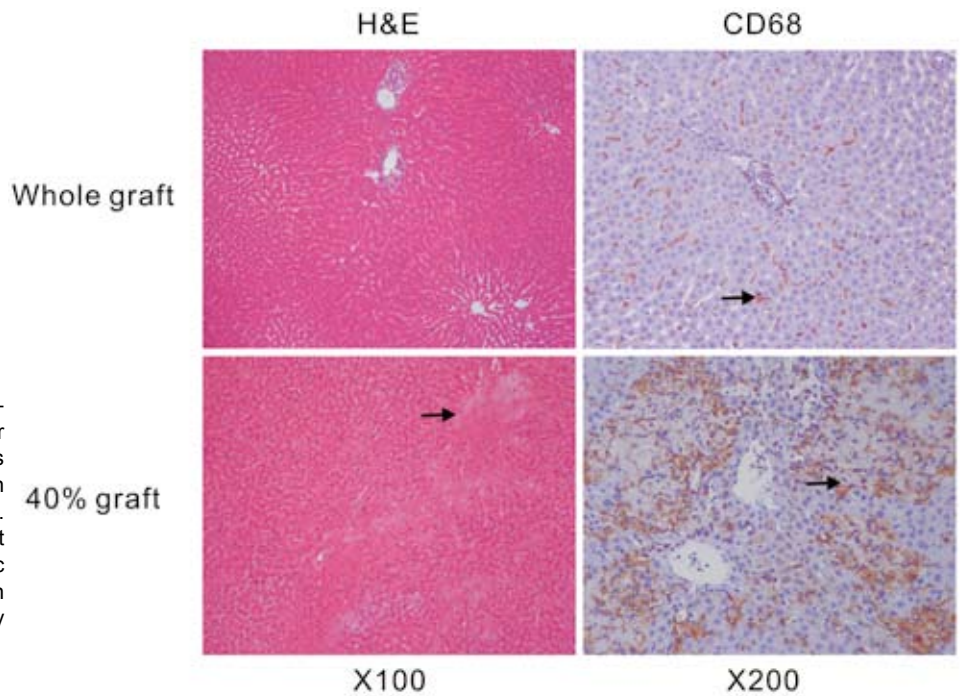

Figure 8.2. Histology of the small-for-size (40%) liver graft 48 hours after reperfusion shows extensive areas of necrosis and portal tract infiltration (CD68 immunohistochemical staining). The specimen was obtained from a rat experiment. Arrows indicate necrotic areas by hematoxylin and eosin (H&E) staining and $CD68^+$ cells by immunohistochemistry, respectively.

Under electron microscopy, mitochondrial swelling and vacuolar changes are found within the cytoplasm of hepatocytes about 3 hours after reperfusion. Irregular large gaps between the sinusoidal lining cells are also seen (Figure 8.3). Twenty-four hours after reperfusion, loss of microvilli in the space of Disse is observed and the integrity of the endothelial cells is disrupted[18] (Figure 8.4).

The histopathological changes of small-for-size living donor liver graft injury are somewhat similar to those of ischemia-reperfusion or preservation injury in a deceased donor liver graft and the sinusoidal epithelium bears the brunt of injury.[16,19] Since the duration of cold ischemia is short in LDLT, the histopathological pattern of small-for-size graft injury is likely related to the graft size itself. However, whatever the duration of cold and warm ischemia, ischemia-reperfusion injury is inevitable in any type of liver grafts. What is observed under the microscope represents the final common manifestation of

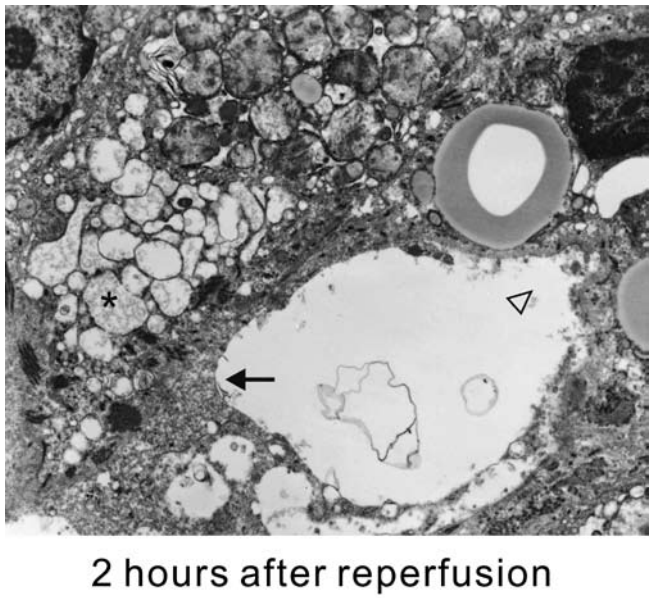

Figure 8.3. Ultrastructure of the small-for-size graft of a human specimen by electron microscopy shows mitochondrial swelling (asterisk), irregular large gaps between sinusoidal lining cells (▷), and loss of microvilli in the space of Disse (arrow).

liver injury and may not be specific to any type of injury. Thus, it is reasonable to define small-for-size graft injury as that occurring on top of ischemia-reperfusion injury.

Mechanism of injury

The initiating event is thought to be hyperdynamic portal flow through a small liver graft leading to shear stress injury of sinusoidal endothelial cells[18] (Figure 8.5). With the loss of integrity of endothelial cells, leukocytes adhere to the hepatocytes and initiate the cascades of coagulation within the damaged sinusoids and impaired blood flow. The subsequent event is upregulation of vasoconstrictive genes, e.g. endothelin-1 and early growth response-1, which is a master switch coordinating upregulation of divergent gene families related to ischemia-reperfusion injury.[20,21] Upregulation of adhesion molecules and pro-inflammatory cytokine release will lead to activation of macrophages and infiltration around the portal tract.[17] During the early period (within 24 hours) after reperfusion, local tissue macrophages (mainly Kupffer cells) are cells that initiate portal tract infiltration. Later (24–48 hours) circulatory monocytes deposit in the portal tract and are converted into macrophages. Tissue-damaging reactive oxygen species are released from infiltrating macrophages, leading to more liver damage.[19,22] Increased vascular endothelial growth factor (VEGF) secreted by replicating hepatocytes during rapid liver regeneration and angiogenesis also contributes to portal tract infiltration by macrophages because VEGF could induce Flk-1-dependent macrophage migration and activation in the liver graft.[23] As a result, there is enhanced alloantigen presentation leading to exacerbated acute rejection.[24-26] Thus, small-for-size graft injury could be viewed as a combination of mechanical injury, exacerbated inflammatory response,[20] and subsequent accelerated immune reaction on top of ischemia-reperfusion injury (Figure 8.5). Macrophages play a central role in these processes. Activation of macrophages preceded by

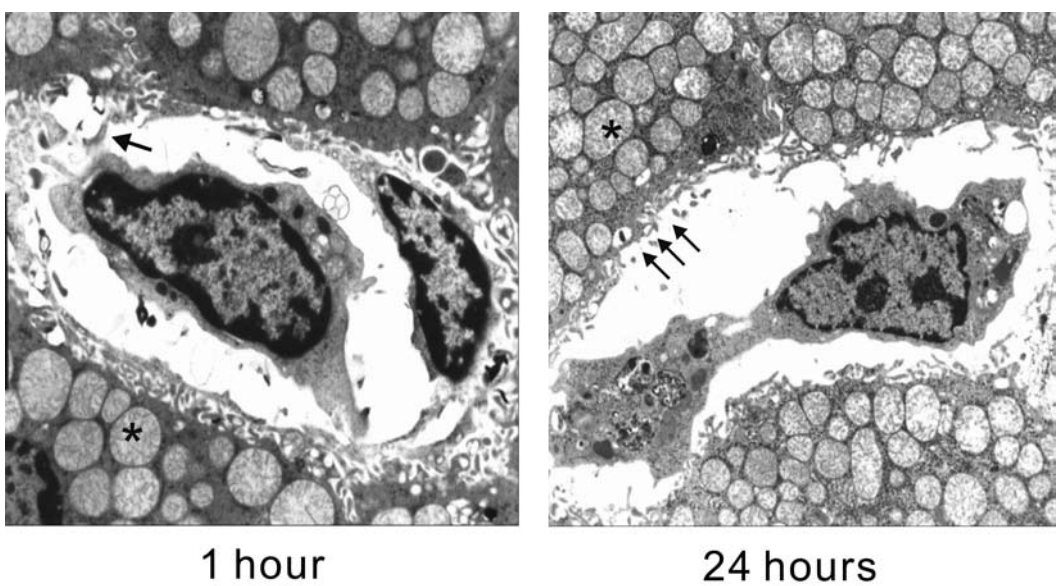

Figure 8.4. Ultrastructure of the small-for-size graft of the samples from a rat orthotopic liver transplantation model by electron microscopy shows mitochondrial swelling (asterisk) and irregular large gaps between sinusoidal lining cells (single arrow) at 1 hour after transplantation. Total disruption of hepatic sinusoid (arrows) was present at 24 hours after reperfusion.

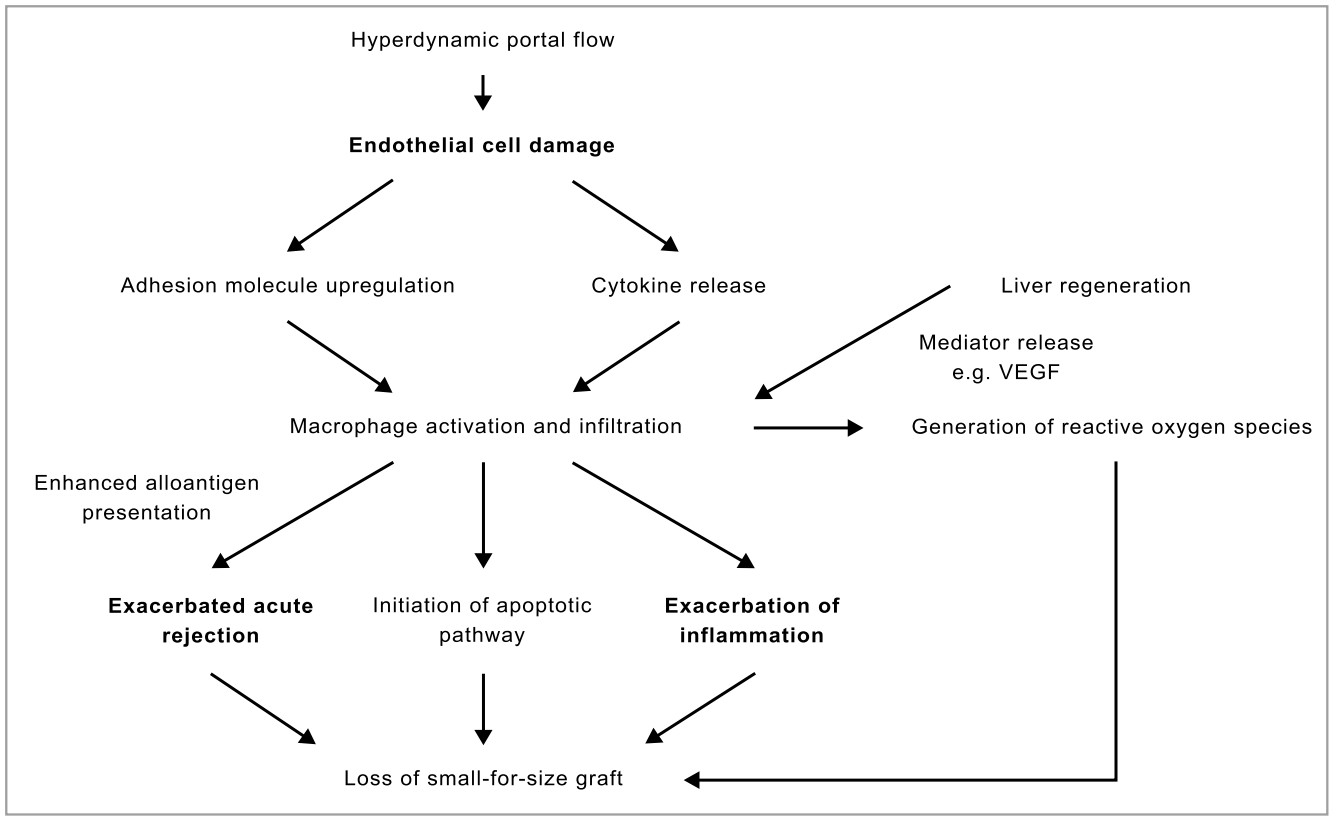

Figure 8.5. Possible reasons for loss of a small-for-size graft.

upregulation of allograft inflammatory factor-1 may generate more reactive oxygen species and release more pro-inflammatory and pro-apoptotic molecules, leading to graft loss.[27]

Strategies to rescue small-for-size graft after reperfusion

With the understanding of the mechanism of small-for-size graft injury, several surgical procedures have been devised to reduce the extent of injury (Figure 8.6). For example, to reduce portal flow, splenic artery ligation,[28,29] splenectomy,[29,30] portal vein-superior mesenteric vein disconnection and superior mesenteric vein-inferior vena cava shunt[31,32] or partial porto-caval shunt[33-36] have been tested and claimed successful in a small number of patients. However, modulation of the portal blood flow is frequently made basing on the portal venous pressure or flow rate after implantation. Since graft damage may occur immediately on restoration of portal vein blood flow and portal venous pressure is then a reflection of the graft damage, the portal inflow modulation may not be totally effective in salvaging the small-for-size graft. Therefore, these procedures must be performed in anticipation of the injury.[37,38] When small-for-size syndrome is full-blown, it is doubtful if reduction of portal blood flow can still salvage the liver graft. Therefore, pre-implantation portal pressure, graft size, Model for End-stage Liver Disease score, and expected congestion liver volume should be parameters taken into consideration for portal inflow modulation before reperfusion. Cutoff values for such parameters are not yet available.

In the animal experiments, several studies have also claimed success in ameliorating small-for-size graft injury (Figure 8.6). For example, low-dose somatostatin (20 μg/kg) may reduce portal pressure, thus attenuating acute-phase shear stress during the early phase of reperfusion.[39] Sodium salicylate could decrease macrophage infiltration by reversing the upregulation of Flk-1 on macrophages by VEGF, reduce generation of reactive oxygen species and inducible nitric oxide synthase production.[23] Interleukin-10, which is a multi-potent cytokine, may be superior to sodium salicylate. It was shown to inhibit allograft inflammatory factor-1-mediated pro-inflammatory and pro-apoptotic activities of

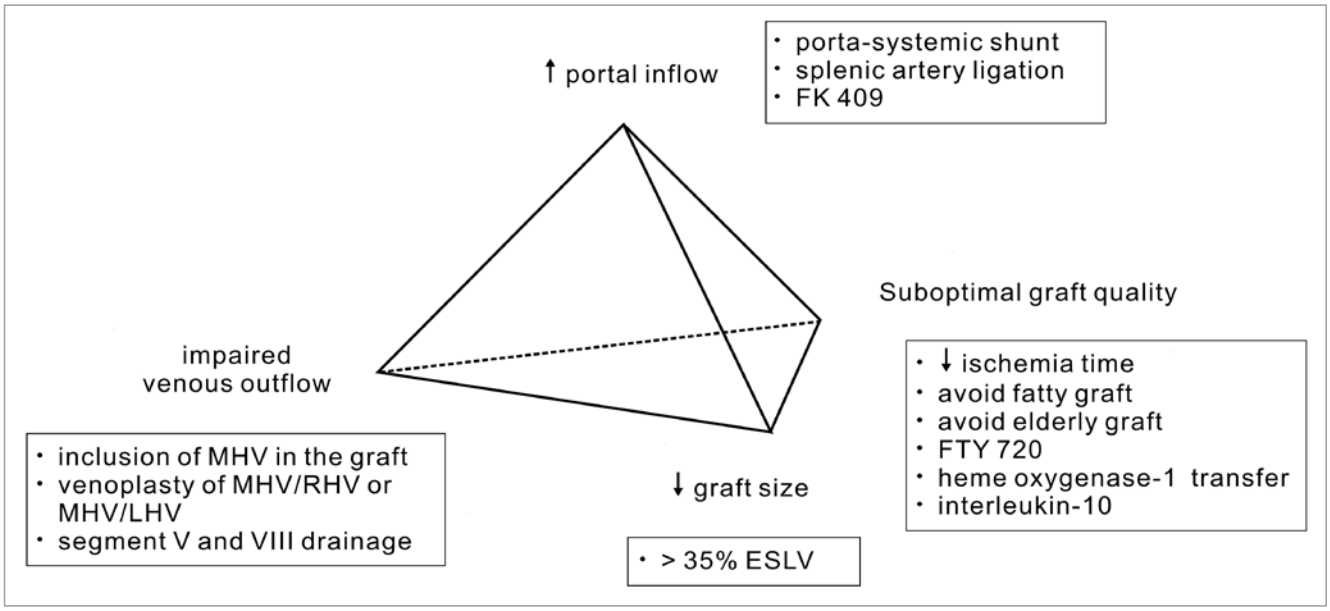

Figure 8.6. Pyramidal relationship of portal inflow, graft quality, portal outflow and graft size in determining the outcome of a small-for-size graft. The boxes include some of the clinical and experimental procedures that may alleviate small-for-size graft injury.

macrophages during the early period after ischemia-reperfusion,[27] leading to improved graft histology and survival. Heme oxygenase-1 gene transfer into the graft can reduce inflammatory cell infiltrate, adhesion molecules, cytokine release and promote vasodilatation.[40] FK409, a nitric oxide donor, may reduce portal pressure, decrease the production of inflammatory cytokine and chemokine such as inducible nitric oxide synthase, tumor necrosis factor-alpha, macrophage inflammatory protein-2, and increase the production of interleukin-10 and heme oxygenase-1, resulting in improvement of microcirculation and intracellular homeostasis.[41] FTY720, an immunomodulator acting via sequestration of peripheral blood lymphocytes to secondary lymphoid organs, may attenuate small-for-size graft injury by activation of cell-survival Akt signaling and down-regulation of the MAPK pathway.[42] FTY720 also provides vaso-regulatory protection of the integrity of the hepatic sinusoids. Combined with adiponectin, a fat-derived hormone that is shown to be effective for the treatment of obesity-associated metabolic syndromes, almost all small-for-size fatty grafts could be salvaged.[43] However, these experimental strategies have not been tested in human beings.

Impact of small-for-size graft injury

Patients receiving small-for-size grafts have worse survival rates than those with an adequate graft size. Even they survive the operation, their hospital course is more arduous and the hospital fee is enormous. It is also possible that hepatocellular carcinoma is more likely to recur in patients receiving small-for-size grafts44 because the aggravated inflammatory changes and rapid liver regeneration may set a favorable microenvironment for circulating cancer cells to deposit and proliferate. Given such negative impact, accurate calculation of graft volume and selection of the appropriate donor and recipient are mandatory to avoid untoward consequences of small-for-size graft injury.

On careful scrutiny of the clinical data of small-for-size graft reports, not every patient receiving small-for-size grafts (<40% of the ESLV) lost their grafts,45 whereas some patients receiving grafts larger than the required liver weight succumbed. The survivors of small-for-size grafts are mostly those without severe portal hypertension (therefore, less portal inflow injury to the graft), but there may be other factors that determine the graft outcome. In the early development of LDLT, much attention was paid to the design of portal inflow reconstruction, diversion or reduction to avert graft injury, but not so much to the venous outflow of the graft. The venous outflow of the right anterior sector was even ignored when early investigators embarked on right liver LDLT. In one pathologic study, outflow tract obstruction is identified to be a definite cause

of graft failure.46 In the absence of uniform and adequate outflow, the inflow impedance, graft hypoperfusion and therefore portal hypertension are aggravated. It is questionable whether manipulation of portal pressure in the face of relative outflow obstruction is wise because portal pressure is now a reflection of portal inflow obstruction rather than the cause of graft injury. It is useful to recall the Ohm's law, $\Delta P = Q \times R$, in which ΔP is portal pressure gradient (the difference between the portal pressure and the inferior vena cava pressure), Q is blood flow, and R is vascular resistance. The portal pressure is not related to portal blood flow alone. Resistance to flow also contributes. Splenic artery ligation, splenectomy or shunting operation in the attempt to manipulate the inflow in the presence of outflow obstruction or established graft injury would not be effective and would even be dangerous (leading to portal vein thrombosis). Recognizing the importance of outflow, surgeons now pay meticulous attention to outflow reconstruction and obtain much better results. For example, with middle and right hepatic vein venoplasty, the graft size limit could be reduced down to 35% of the ESLV.47 In addition to the right and middle hepatic veins, all other hepatic veins should be preserved and implanted as far as possible.

There could be other factors that influence the outcome of the patients receiving small-for-size grafts. Suboptimal grafts such as steatotic grafts and grafts from elderly persons are likely to sustain more serious injuries if they are small-for-size (Figure 8.6). In case of prolonged cold and warm ischemia, graft injury could also be aggravated. To shorten the cold ischemic time to the minimum, the donor and recipient operations must be matched well in timing. Prolonged bench surgery thus exposing part of the liver graft to room temperature is undesirable. The liver graft must be immersed in cold preservation solution and the exposed part covered by ice-cold pad as far as possible during bench procedure. Finally, the implantation procedure must be simple and expeditious to avoid prolonged warm ischemia.

Summary

The outcome of a small-for-size graft in the clinical setting could be viewed as a pyramidal relationship among the graft size itself, graft quality, portal inflow and venous outflow[48] (Figure 8.6). To improve the outcome, the surgeon should be meticulous in eliminating all possible adverse factors. Perfect venous outflow is perhaps the most essential element for the success in small-for-size graft implantation after optimal graft quality is assured.

References

1. Lo CM, Fan ST, Chan JK, Wei W, Lo RJ, Lai CL. Minimum graft volume for successful adult-to-adult living donor liver transplantation for fulminant hepatic failure. Transplantation 1996; 62: 696-698.
2. Kiuchi T, Tanaka K, Ito T, Oike F, Ogura Y, Fujimoto Y, Ogawa K. Small-for-size graft in living donor liver transplantation: how far should we go? Liver Transpl 2003; 9: S29-S35.
3. Fan ST, Lo CM, Liu CL, Yong BH, Chan JK, Ng IO. Safety of donors in live donor liver transplantation using right lobe grafts. Arch Surg 2000; 135: 336-340.
4. Lo CM, Fan ST, Liu CL, Chan JK, Lam BK, Lau GK, Wei WI, Wong J. Minimum graft size for successful living donor liver transplantation. Transplantation 1999; 68: 1112-1116.
5. Heinemann A, Wischhusen F, Puschel K, Rogiers X. Standard liver volume in the Caucasian population. Liver Transpl Surg 1999; 5: 366-368.
6. Urata K, Kawasaki S, Matsunami H, Hashikura Y, Ikegami T, Ishizone S, Momose Y, Komiyama A, Makuuchi M. Calculation of child and adult standard liver volume for liver transplantation. Hepatology 1995; 21: 1317-1321.
7. Chan SC, Liu CL, Lo CM, Lam B, Lee E, Wong Y, Fan ST. Estimating liver weight of adults by body weight and gender. World J Gastroenterol 2006; 12: 2217-2222.
8. Yu HC, You H, Lee H, Jin ZW, Moon JI, Cho BH. Estimation of standard liver volume for liver transplantation in the Korean population. Liver Transpl 2004; 10: 779-783.
9. Chandramohan A, Eapen A, Govil S, Govil S, Jeyaseelan V. Determining standard liver volume: assessment of existing formulae in Indian population. Indian J Gastroenterol 2007; 26: 22-25.
10. DeLand FH, North WA. Relationship between liver size and body size. Radiology 1968; 91: 1195-1198.
11. Chouker A, Martignoni A, Dugas M, Eisenmenger W, Schauer R, Kaufmann I, Schelling G, Lohe F, Jauch KW, Peter K, Thiel M. Estimation of liver size for liver transplantation: the impact of age and gender. Liver Transpl 2004; 10: 678-685.
12. Hashimoto T, Sugawara Y, Tamura S, Hasegawa K, Kishi Y, Kokudo N, Makuuchi M. Estimation of standard liver volume in Japanese living liver donors. J Gastroenterol Hepatol 2006; 21: 1710-1713.
13. DuBois D, DuBois EF. A formula to estimate the approximate surface area if height and weight be known. Arch Intern Med 1916; 17: 863.
14. Emond JC, Renz JF, Ferrell LD, Rosenthal P, Lim RC, Roberts JP, Lake JR, Ascher NL. Functional analysis of grafts from living donors. Implications for the treatment of older recipients. Ann Surg 1996; 224: 544-554.
15. Man K, Lo CM, Ng IO, Wong YC, Qin LF, Fan ST, Wong J. Liver transplantation in rats using small-for-size grafts: a study of hemodynamic and morphological changes. Arch Surg 2001; 136: 280-285.

16. Demetris AJ, Kelly DM, Eghtesad B, Fontes P, Wallis Marsh J, Tom K, Tan HP, Shaw-Stiffel T, Boig L, Novelli P, Planinsic R, Fung JJ, Marcos A. Pathophysiologic observations and histopathologic recognition of the portal hyperperfusion or small-for-size syndrome. Am J Surg Pathol 2006; 30: 986-993.
17. Yang ZF, Ho DW, Chu AC, Wang YQ, Fan ST. Linking inflammation to acute rejection in small-for-size liver allografts: the potential role of early macrophage activation. Am J Transplant 2004; 4: 196-209.
18. Man K, Fan ST, Lo CM, Liu CL, Fung PC, Liang TB, Lee TK, Tsui SH, Ng IO, Zhang ZW, Wong J. Graft injury in relation to graft size in right lobe live donor liver transplantation: a study of hepatic sinusoidal injury in correlation with portal hemodynamics and intragraft gene expression. Ann Surg 2003; 237: 256-264.
19. Starzl TE, Demetris AJ. Liver transplantation: a 31-year perspective. Chicago: Year Book Medical Publishers, 1990.
20. Liang TB, Man K, Kin-Wah Lee T, Hong-Teng Tsui S, Lo CM, Xu X, Zheng SS, Fan ST, Wong J. Distinct intragraft response pattern in relation to graft size in liver transplantation. Transplantation 2003; 75: 673-678.
21. Man K, Lo CM, Lee TK, Li XL, Ng IO, Fan ST. Intragraft gene expression profiles by cDNA microarray in small-for-size liver grafts. Liver Transpl 2003; 9: 425-432.
22. Zhong Z, Connor HD, Froh M, Bunzendahl H, Lind H, Lehnert M, Mason RP, Thurman RG, Lemasters JJ. Free radical-dependent dysfunction of small-for-size rat liver grafts: prevention by plant polyphenols. Gastroenterology 2005; 129: 652-664.
23. Yang ZF, Poon RT, Luo Y, Cheung CK, Ho DW, Lo CM, Fan ST. Up-regulation of vascular endothelial growth factor (VEGF) in small-for-size liver grafts enhances macrophage activities through VEGF receptor 2-dependent pathway. J Immunol 2004; 173: 2507-2515.
24. Yang ZF, Ho DW, Lau CK, Lam CT, Lum CT, Poon RT, Fan ST. Allograft inflammatory factor-1 (AIF-1) is crucial for the survival and pro-inflammatory activity of macrophages. Int Immunol 2005; 17: 1391-1397.
25. Omura T, Nakagawa T, Randall HB, Lin Z, Huey M, Ascher NL, Emond JC. Increased immune responses to regenerating partial liver grafts in the rat. J Surg Res 1997; 70: 34-40.
26. Shiraishi M, Csete ME, Yasunaga C, Drazan KE, Jurim O, Cramer DV, Busuttil RW, Shaked A. Regeneration-induced accelerated rejection in reduced-size liver grafts. Transplantation 1994; 57: 336-340.
27. Yang ZF, Ho DWY, Ngai P, Lau CK, Zhao Y, Poon RTP, Fan ST. Antiinflammatory properties of IL-10 rescue small-for-size liver grafts. Liver Transpl 2007; 13: 558-565.
28. Lo CM, Liu CL, Fan ST. Portal hyperperfusion injury as the cause of primary nonfunction in a small-for-size liver graft-successful treatment with splenic artery ligation. Liver Transpl 2003; 9: 626-628.
29. Shimada M, Ijichi H, Yonemura Y, Harada N, Shiotani S, Ninomiya M, Terashi T, Yoshizumi T, Soejima Y, Suehiro T, Maehara Y. The impact of splenectomy or splenic artery ligation on the outcome of a living donor adult liver transplantation using a left lobe graft. Hepatogastroenterology 2004; 51: 625-629.
30. Yagi S, Iida T, Hori T, Taniguchi K, Yamamoto C, Yamagiwa K, Uemoto S. Optimal portal venous circulation for liver graft function after living-donor liver transplantation. Transplantation 2006; 81: 373-378.
31. Boillot O, Delafosse B, Mechet I, Boucaud C, Pouyet M. Small-for-size partial liver graft in an adult recipient; a new transplant technique. Lancet 2002; 359: 406-407.
32. Masetti M, Siniscalchi A, De Pietri L, Braglia V, Benedetto F, Di Cautero N, Begliomini B, Romano A, Miller CM, Ramacciato G, Pinna AD. Living donor liver transplantation with left liver graft. Am J Transplant 2004; 4: 1713-1716.
33. Troisi R, Cammu G, Militerno G, De Baerdemaeker L, Decruyenaere J, Hoste E, Smeets P, Colle I, Van Vlierberghe H, Petrovic M, Voet D, Mortier E, Hesse UJ, de Hemptinne B. Modulation of portal graft inflow: a necessity in adult living-donor liver transplantation? Ann Surg 2003; 237: 429-436.
34. Troisi R, Ricciardi S, Smeets P, Petrovic M, Van Maele G, Colle I, Van Vlierberghe H, de Hemptinne B. Effects of hemi-portocaval shunts for inflow modulation on the outcome of small-for-size grafts in living donor liver transplantation. Am J Transplant 2004; 5: 1397-1404.
35. Takada Y, Ueda M, Ishikawa Y, Fujimoto Y, Miyauchi H, Ogura Y, Ochiai T, Tanaka K. End-to-side portocaval shunting for a small-for-size graft in living donor liver transplantation. Liver Transpl 2004; 10: 807-810.
36. Taniguchi M, Shimamura T, Suzuki T, Yamashita K, Oura T, Watanabe M, Kamiyama T, Matsushita M, Furukawa H, Todo S. Transient portacaval shunt for a small-for-size graft in living donor liver transplantation. Liver Transpl 2007; 13: 932-934.
37. Umeda Y, Yagi T, Sadamori H, Matsukawa H, Matsuda H, Shinoura S, Iwamoto T, Satoh D, Iwagaki H, Tanaka N. Preoperative proximal splenic artery embolization: a safe and efficacious portal decompression technique that improves the outcome of live donor liver transplantation. Transpl Int 2007; 20: 947-955.
38. Cheng YF, Huang TL, Chen TY, Concejero A, Tsang LL, Wang CC, Wang SH, Sun CK, Lin CC, Liu YW, Yang CH, Yong CC, Ou SY, Yu CY, Chiu KW, Jawan B, Eng HL, Chen CL. Liver graft-to-recipient spleen size ratio as a novel predictor of portal hyperperfusion syndrome in living donor liver transplantation. Am J Transplant 2006; 6: 2994-2999.
39. Xu X, Man K, Zheng SS, Liang TB, Lee TK, Ng KT, Fan ST, Lo CM. Attenuation of acute phase shear stress by somatostatin improves small-for-size liver graft survival. Liver Transpl 2006; 12: 621-627.
40. Yang ZF, Tsui TY, Ho DW, Tang TC, Fan ST. Heme oygenase-1 potentiates the survival of small-for-size liver graft. Liver Transpl 2004; 10: 784-793.
41. Man K, Lee TKW, Liang TB, Lo CM, Fung PC, Tsui SH, Li XL, Ng KT, Fan ST. FK409 ameliorates small-for-size liver graft injury by attenuation of portal hypertension and down-regulation of Egr-1 pathway. Ann Surg 2004; 240: 159-168.
42. Zhao Y, Man K, Lo CM, Ng KT, Li XL, Sun CK, Lee TK, Dai XW, Fan ST. Attenuation of small-for-size liver graft injury by FTY720: significance of cell-survival Akt signaling pathway. Am J Transplant 2004; 4: 1399-1407.
43. Man K, Zhao Y, Xu A, Lo CM, Lam KS, Ng KT, Ho JW, Sun CK, Lee TK, Li XL, Fan ST. Fat-derived hormone adiponectin combined with FTY720 significantly improves small-for-size fatty liver graft survival. Am J Transplant 2006; 6: 467-476.
44. Man K, Ng KTP, Lo CM, Ho JWY, Sun CKW, Lam S, Lee TKW, Chu ACY, Poon RTP, Fan ST. Ischemia-reperfusion of small liver remnant promotes liver tumor metastases – activation of cell invasion pathways. Liver Transpl – in press.
45. Nishizaki T, Ikegami T, Hiroshige S, Hashimoto K, Uchiyama H, Yoshizumi T, Kishikawa K, Shimada M, Sugimachi K. Small graft for living donor liver transplantation. Ann Surg 2001; 233: 575-580.
46. Pantanowitz L, Pomfret EA, Pomposelli JJ, Lewis WD, Gordon FD, Jenkins RL, Khettry U. Pathologic analysis of right-lobe graft failure in adult-to-adult live donor liver transplantation. Int J Surg Pathol 2003; 11: 283-294.
47. Fan ST, Lo CM, Liu CL, Yong BH, Wong J. Determinants of hospital mortality of adult recipients of right lobe live donor liver transplantation. Ann Surg 2003; 238: 864-870.
48. Fan ST. Live donor liver transplantation in adults. Transplantation 2006; 82: 723-732.

9. Donor results

Our results

From 28 September 1993 to 31 December 2006, we performed 253 right liver donor hepatectomies, 32 left liver donor hepatectomies and 44 segment II/III ± part of IV graft operations. In this section, the results of right liver donor hepatectomies are presented.

The donors are arbitrarily divided into five eras, each 50 consecutives cases, for comparison. All except one right liver graft (case No. 85) included the middle hepatic vein (MHV). In the donor of case No. 85, the segment III hepatic vein drained into the MHV more caudally than the segment VIII hepatic vein. Only the segment VIII hepatic vein was retained in the right liver graft. After portal vein reperfusion, there was an extensive dusky area in segment V (Figure 6.12). Nowadays, such anatomical arrangement of hepatic veins is not considered a contraindication for MHV inclusion in the right liver graft (Figure 5.16).

Donor characteristics are listed in Table 9.1. There was significant reduction in the operation time (Table 9.2). It took about 50 cases for the learning curve to plateau (Figure 9.1). There was also gradual reduction of the median blood loss volume throughout these years. The recent increase in the operation time and blood loss is related to the fact that junior surgeons are trained to perform the operations. Only one donor received exogenous blood transfusion in the first era. The median inten-

Table 9.1. Donor characteristics of the five eras.

Era	1 May 1996 – Sep 2000	2 Sep 2000 – May 2002	3 Jun 2002 – Feb 2004	4 Feb 2004 – Apr 2005	5 Apr 2005 – Sep 2006
Age (years)	37 (18–57)	39 (18–56)	35 (21–56)	33.5 (18–54)	34 (19–53)
Gender (M : F)	19:31	18:32	22:28	15:35	18:32
Body weight (kg)	53.0 (41.0–84.1)	57.8 (44.0–81.0)	55.4 (44.0–108.5)	56.6 (37.0–75.0)	57.5 (39–83.2)
Body height (cm)	160.7 (146–188)	160 (150–178.5)	163 (148–181.3)	161 (144.5–177)	163 (145–183)
Body mass index (kg/m^2)	20.9 (16.5–28.1)	22.5 (17.6–28.7)	20.9 (17.1–35.6)	21.7 (15.6–29.1)	20.9 (16.2–28.9)
Remnant left liver to total liver volume ratio	0.34 (0.24–0.45)	0.34 (0.26–0.44)	0.36 (0.29–0.50)	0.37 (0.27–0.46)	0.36 (0.30–0.45)
Ethnicity					
Chinese	50	49	46	49	49
Filipino	0	0	1	0	0
Caucasian	0	1	1	0	0
Indian	0	0	1	0	0
Burmese	0	0	0	1	0
Japanese	0	0	1	0	0
Vietnamese	0	0	0	0	1

Values are expressed in median with range in parentheses.

Table 9.2. Donor outcomes of the five eras.

Era	1 May 1996 – Sep 2000	2 Sep 2000 – May 2002	3 Jun 2002 – Feb 2004	4 Feb 2004 – Apr 2005	5 Apr 2005 – Sep 2006
Operation time (mins)	598 (378–932)	469 (388–640)	414 (310–602)	391 (304–635)	496.5 (278–638)
Blood loss (mL)	500 (200–1600)	410 (42–1250)	286 (46–716)	251 (95–595)	341.5 (71–1402)
Blood transfusion (%)	1 (2)	0	0	0	0
Intensive care unit stay (days)	2 (1–8)	1 (1–5)	1 (0–4)	1 (1–3)	1 (1–3)
General ward stay (days)	8 (3–35)	8 (3–20)	6 (2–18)	5 (2–14)	6 (3–14)
Total hospital stay (days)	10 (5–38)	9 (6–22)	7.5 (5–19)	6.5 (4–16)	7 (5–15)

Values are expressed in median with range in parentheses.

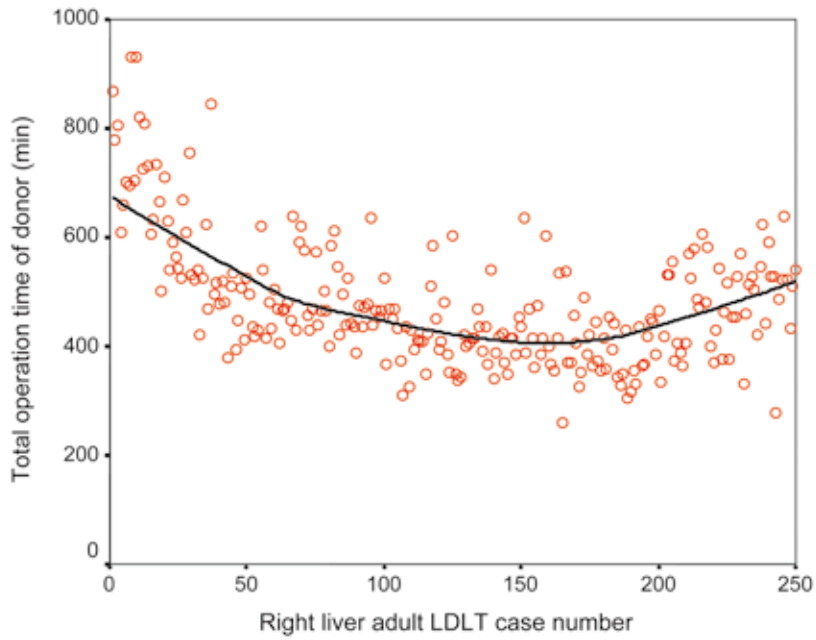

Figure 9.1. Operation time of donor right hepatectomy of 250 cases.

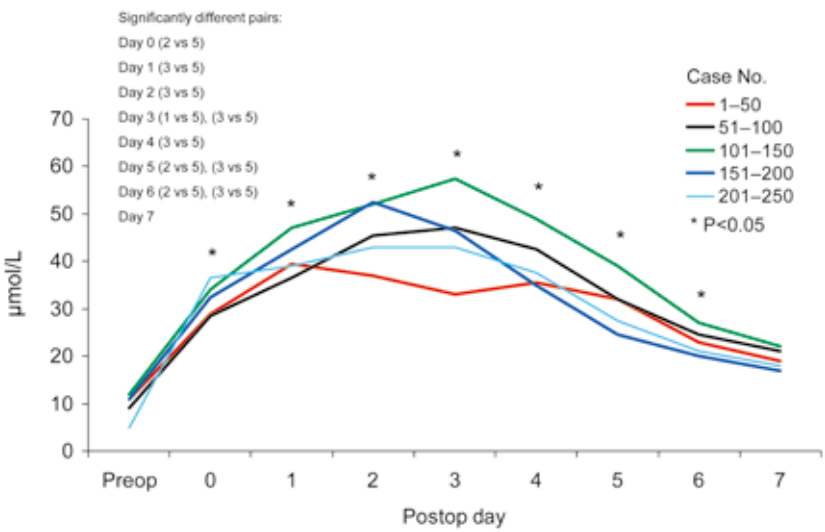

Figure 9.2. Serum total bilirubin levels before operation and at the first operative week.

sive care unit stay was 1 day in the recent era. The median stay in hospital was 10 days in era 1 and was shortened to 7 days in era 5.

The median serum total bilirubin, alanine aminotransferase (ALT), and aspartate aminotransferase (AST) levels, prothrombin time and hemoglobin levels before and during the first week after donor operations of the five eras are shown in Figures 9.2–9.6. The peak value of the serum bilirubin level was recorded on postoperative day 2 or 3. Although there were some significant differences of the serum ALT and AST levels amongst donors of different eras, the difference was in fact small and inconsequential. The peak prothrombin time values were found on postoperative days 1 and 2. Thereafter, the prothrombin time was rapidly normalized. There was a gradual decline in the hemoglobin level in the first three days after the operation. It was a reflection of hemodilution rather than actual blood loss.

Morbidity and mortality

Complications of donor operations graded by the Clavien classification[1] are listed in Table 9.3. The complication rates of the five eras were 34%, 16%, 16%, 16% and 14%, respectively. Serious complications included biliary stricture,[2] portal vein thrombosis, intestinal obstruction, and hemoperitoneum. One donor in era 4 (case No. 165) without a history of duodenal ulcer and asymptomatic after the donor operation was re-admitted 10 weeks later for fever, seizure and coffee ground vomiting. She developed cardiac arrest during upper endoscopy. Postmortem examination showed that she had duodeno-caval fistula complicating chronic duodenal ulcer. The overall complication and mortality rates were 18% and 0.4%, respectively. Judging from the types of complications, there are inherent risks of the procedure unrelated to technical reasons, but hopefully, such complications could be avoided if we exercise meticulous attention to perioperative care.

Results of other centers

The intraoperative and postoperative complications of donors in the reported series varied from 9%–67%.[3-9] The donor complication rate is higher for right liver than left liver donation.[10,11] The wide range in the incidence of complications is a reflection of maturation of the surgical technique but is

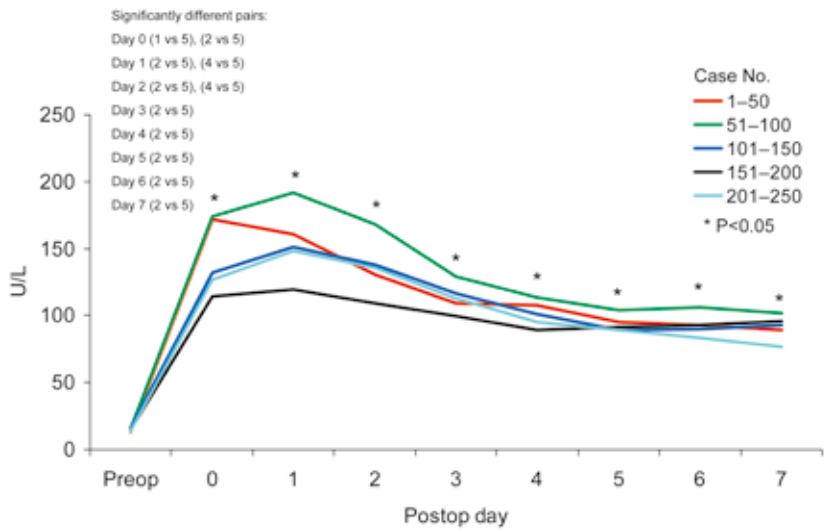

Figure 9.3. Serum alanine aminotransferase levels before operation and at the first operative week.

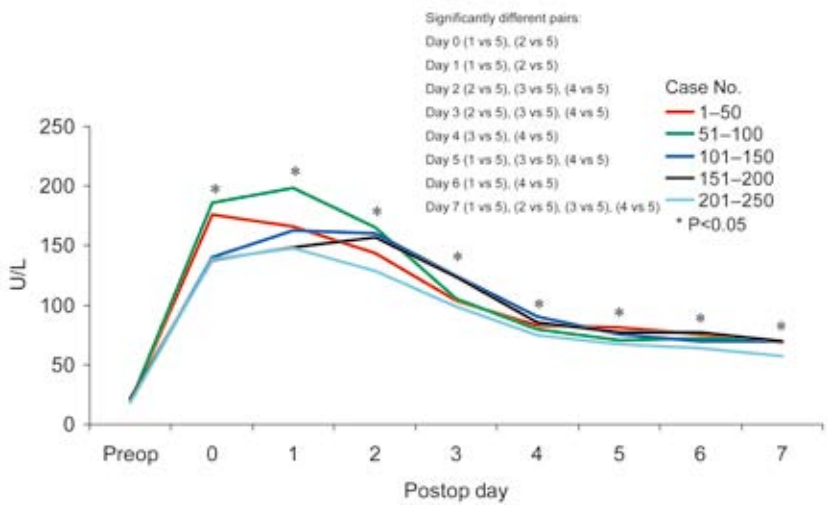

Figure 9.4. Serum aspartate aminotransferase levels before operation and at the first operative week.

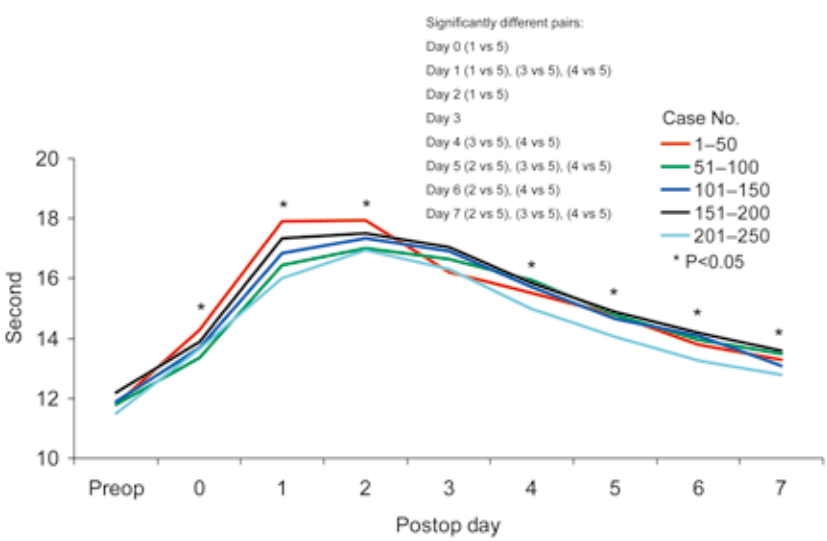

Figure 9.5. Prothrombin time before operation and at the first operative week.

also an indication on how surgeons reported their complications. By definition, a complication is an event that deviates from the normal path of recovery. Thus, any event must be counted as a complication. It is also necessary to grade the severity of complications according to the Clavien system.[1] Not well stipulated in the Clavien classification system is the time of occurrence of the complication, which must be reported. Late donor mortalities have been reported, but late occurrence of incision hernia and portal vein thrombosis are seldom reported.[12] Perhaps for the sake of full documentation and for potential donor's information, all late events should be recorded and counted as complications.

The types of complications from recent reports[11,13-29] are compiled in Table 9.4.

There are 18 known donor mortalities (Table 9.5).[4,8,20,30-42] Among them, 13 were right liver donors, three were left liver donors, and two were not known exactly. Amongst these donor deaths, only 12 are reported in detail. There are unconfirmed reports of deaths from India[43] (1) and Brazil[13] (1). The donor mortality rate is estimated to be 0.08%–0.5%. Since the total number of donor hepatectomies performed in the world and the actual number of donor deaths are not known, the donor mortality rate remains an estimate only. The causes of some of the mortalities were quite unexpected. It is not known whether more vigilant donor evaluation, selection and perioperative care could have prevented these donor mortalities. On hindsight, many of these donors might not have been completely healthy persons. Therefore, the threshold of donor acceptance must not be low and the donor evaluation protocol

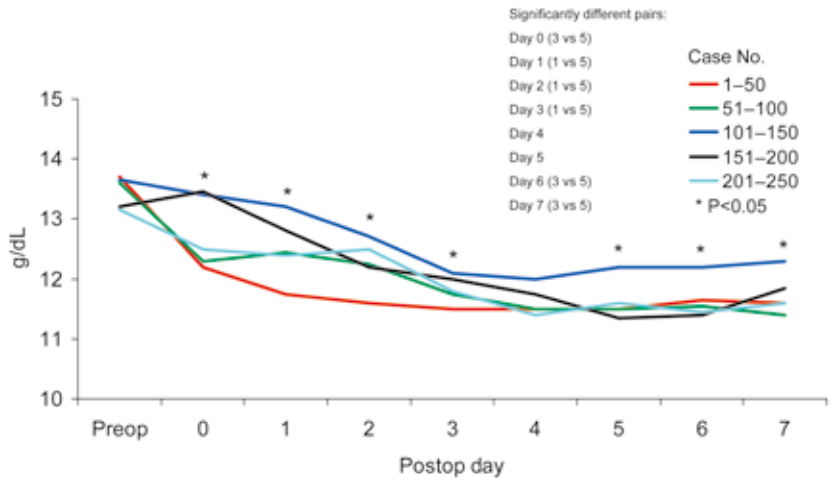

Figure 9.6. Hemoglobin before operation and at the first operative week.

must be adhered to all the time, irrespective of the recipient condition.

Comments on donor hepatectomy complications

Similar to any major surgery, accumulation of experience will lead to reduction of the complication rate. Comparing with partial hepatectomy on cirrhotic patients bearing tumors, the goal of achieving a zero percent hospital mortality rate and a near-zero morbidity rate appears easier, provided that the liver is completely normal and the donor is free from any co-morbidity and the surgeon is fully conversant with the liver anatomy and experienced in liver transection. However, the operation by itself is ultra-major in nature and complications may be inevitable. It requires the effort and cooperation of the entire team – anesthesiologists, nurses, support staff and the surgeon – to achieve the goal, while the surgeon himself should lead the team to ensure safety of the donor. Thus, he should be present right from the beginning of the operation to ensure that positioning of the donor is not potentially injurious, catheterization of bladder is performed properly, skin preparation is carried out meticulously, prophylactic antibiotic and H_2-receptor antagonist have been given, and anti-deep vein thrombosis measures are implemented. He should stay until the wound is closed properly and ensure that the donor is hemodynamcially stable before he leaves.

Table 9.3. Donor complications graded by the Clavien system.

Grade	1st 50	2nd 50	3rd 50	4th 50	5th 50
I	8 4 Wound infection 1 Intraoperative pneumothorax 1 Cholestasis 1 Peroneal nerve palsy 1 Occiput pressure sore	5 2 Wound infection 2 Cholestasis 1 Lung collapse	8 6 Wound infection 1 Occiput sore 1 Pleural effusion	3 3 Wound infection	4 2 Wound infection 2 Occiput pressure sore
II	4 2 Wound infection 2 Urinary tract infection	2 1 Wound infection 1 Required parenteral nutrition	0	2 1 Urinary tract infection 1 Pleural effusion	1 1 Urinary tract infection
IIIa	1 1 Bleeding duodenal ulcer	1 1 Bile duct stricture	0	1 1 Dog-ear appearance of wound	2 1 Deep vein thrombosis 1 Ascites
IIIb	4 1 Bile duct stricture 1 Intestinal obstruction 1 Incision hernia 1 Intraoperative portal vein thrombosis	0	0	1 1 Hemoperitoneum	0
IVa	0	0	0	0	0
IVb	0	0	0	0	0
V	0	0	0	1 1 Duodeno-caval fistula	0
Rate (%)	34	16	16	16	14

Table 9.4. Complications of living liver donors compiled from reported series.

Complications
Intraoperative injuries
Pneumothorax
Portal vein thrombosis, kinking
Bile duct damage
Hepatic artery injury
Cardiopulmonary complications
Pleural effusion
Pulmonary edema
Pulmonary embolism
Bronchopneumonia
Lung collapse
Aspiration
Respiratory arrest
Congestive heart failure
Myocardial infarction
Pleural empyema
Abdominal / gastrointestinal tract complications
Prolonged ileus
Duodenal ulcer / bleeding / perforation
Small bowel obstruction
Pancreatitis
Intra-abdominal bleeding / collection / abscess
Gastric perforation
Gastric outlet obstruction
Diaphragmatic hernia
Hepatobiliary complications
Portal vein stenosis / thrombosis
Biliary tract stenosis
Bile leakage
Biloma
Liver failure (liver transplantation)
Cholestasis
Ascites
Secondary biliary cirrhosis
Encephalopathy
Wound complications
Wound infection
Dehiscence
Leakage of ascites
Incision hernia
Dog-ear appearance
Other complications
Aborted laparotomy
Deep vein thrombosis
Urinary tract infection
Ankle sores
Occiput sores
Vasovagal shock
Septicemia
Dural puncture during epidural catheter placement
Intrathecal migration of epidural catheter
Oozing at the epidural insertion site
Air embolism
Major hemolytic reaction
Urinary retention
Drain retention
Nonautologous blood transfusion
Renal failure
Psychiatric complications
Suicide
Drug overdose
Depression
Anxiety
Obsessive-compulsive disorder
Bipolar disorder
Neurological complications
Hemiparesis
Hoarseness
Brachial plexus injury
Transient blurry vision
Peroneal nerve injury
Seizure

Table 9.5. Known donor mortalities.

Author	Country	Type of graft	Cause of mortality
Akabayashi[36]	Japan	Rt liver (w/ MHV)	Nonalcoholic steatohepatitis
–	India[40]	Not known	Suspected pulmonary embolism
Boillot[32]	France	Rt liver (w/o MHV)	Right pleural effusion, multiple organ failure
Broering[4]	Germany	Segment II/III	Massive pulmonary embolism
Brown[8]	United States	Rt liver (w/o MHV)	Pancreatitis
–	United States	Not known	Not known
Malago[33]	Germany	Rt liver (w/o MHV)	Congenital lipodystrophy
Malago[37]	Germany	Lt liver	Pulmonary embolism
Miller[34]	United States	Rt liver (w/o MHV)	Gas gangrene of stomach
Wiederkehr[35]	Brazil	Rt liver (w/o MHV)	Cerebral hemorrhage
Chan[31]	Hong Kong	Rt liver (w/ MHV)	Duodeno-caval fistula complicating chronic duodenal ulcer
Polido[41]	Singapore	Rt liver	Heart attack
Coelho[38]	Brazil	Rt liver	Cardiac arrhythmia
–	Korea	Rt liver	Liver failure, steatosis
–	India[39]	Rt liver	Cardiac arrest – unknown cause
–	France	Rt liver	Multiple myeloma
Abofetouh[20]	Egypt	Rt liver	Sepsis, bile leakage
Ringe[42]	USA	Segment II/III	Drug overdose

Bleeding volume is the most important indicator of performance of hepatectomy and prediction of postoperative complications.[44] It depends on the experience and skill of the surgeon. However, the bleeding volume is also dependent on the transection surface. Therefore, to be accurate scientifically, the bleeding volume is preferably expressed as mL/cm^2.[45] The bleeding volume is likely higher on approaching the deeper part of the transection plane. Therefore, a large-size donor with a deep abdominal cavity may have more bleeding. In this regard, Asian surgeons are more fortunate because most of the donors have normal body mass indices and small body sizes.[31] The bleeding volume could be reduced if the central venous pressure is low, operating table is tilted up head-end, or by inflow vascular occlusion. Full muscle relaxation is also important to supplement the effect of low central venous pressure. The intravascular volume could be restored after graft retrieval. Inflow vascular occlusion is normally not employed during liver transection, but if major bleeding occurs, it should be used immediately for clear visualization of the bleeding site in the MHV or its branches. The bleeding volume is also dependent on the anatomical arrangement of the hepatic vein at the junction with the inferior vena cava. Nakamura type I (i.e. segment IVb hepatic vein predominant drainage into the left hepatic vein) is the most favorable type.[46] For the other Nakamura types, recognition of the segment IVb hepatic vein will be helpful in preventing its damage and is made possible by keeping the transection plane close to the MHV and using the ultrasonic dissector (Cavitron Ultrasonic Surgical Aspirator, CUSA, Valley Lab, Boulder, CO, USA). Bleeding volume could be much reduced if the liver transection proceeds cautiously and slowly. Spending a long time on liver transection is not shameful, but inducing bleeding to the extent that blood transfusion is required or major complications occur is undesirable. Bleeding from the root of the MHV or inferior vena cava is potentially fatal, external compression by maneuver as described in the previous chapter will be helpful, and help from additional surgeons must be solicited before a disaster occurs.

Protection of the liver remnant is the most important aspect in ensuring speedy recovery of the donor.[47] Prolonged liver rotation and compression onto the liver hilum by retractors must be avoided. Meticulous hemostasis, preservation of hepatic vein outflow, accurate suturing of hepatic duct stump, and meticulous checking for bile leakage sites are all important. Reconstitution of the falciform ligament is always necessary. Deliberate rotation of the left liver to occupy the right subphrenic cavity is absolutely wrong. Before wound closure, thorough flushing of the operation site by a large volume of normal saline can remove debris and clot and detect minor bleeding points and bile leakage. The surgeon retreats only when a pool of normal saline in the right subphrenic cavity is completely clear. Such steps appear minor or excessive but are important for smooth recovery of the donor.

Wound pain is never listed as a complication, but to the donor, wound pain is the most unbearable part of the operation. Perhaps, they do not anticipate that wound pain could be so severe. Inadequate wound pain control may lead to atelectasis and generate ill-feeling toward the donor operation. On the other hand, too much morphine may lead to respiratory depression. Accumulation of morphine dosage will lead to nausea, vomiting, ileus, and delayed gastric emptying. The incidence is about 20% in the donors.[48] Such side effects may be tolerated by patients undergoing an operation for their own diseases, but may be unacceptable to the donors who undergo operations for the others. An alternative to morphine is non-steroid anti-inflammatory drugs and cyclooxygenase-2 inhibitors, but the risk of serious peptic ulcer complications is real.[49] Epidural anesthesia is also a possible alternative, but the risk of nerve injury, infection and bleeding complications, though low, may be too high for the donors.[50] In case the prothrombin time is prolonged or platelet count is low after the donor hepatectomy, the epidural anesthesia catheter cannot be removed for several days after the operation. Administration of fresh frozen plasma or platelet concentrates just for the purpose of catheter removal is undesirable for the donors, who should not receive any exogenous blood or blood products. Moreover, pain relief is not complete with epidural anesthesia.[50,51] Recently, a catheter that is implanted adjacent to the abdominal wound and delivers constant and regulated doses of local anesthetic has been approved for use in patients.[51] The possible side effects are wound hematoma and infection, although the incidence is negligible. A simpler alternative is

injection of marcaine (0.5%) into the wound at the layer between the peritoneum and muscle where the nerves lie. The maximum tolerating dose is 3 mg/kg. The analgesic effect may last for 4–6 hours. The donor will feel more comfortable on waking up from general anesthesia. Perhaps the subsequent demand for morphine injection could be reduced. Another strategy to reduce wound pain, which is probably the most important one, is to avoid pulling the running suture tightly. The principle of wound closure should be approximation of wound edges by strong sutures without strangulation of the tissues in between the wound. Too tight suturing is undesirable because the subsequent severe inflammatory reaction to ischemia and necrosis could be the cause of severe pain. The knots should be secure but the tissues should not be occluded tightly and rendered ischemic or necrotic.

Postoperative care of the donor should be the same as any patient having hepatectomy. The surgeon should not overestimate the donor's ability to recover from a major hepatectomy. Chest physiotherapy, incentive spirometry and early mobilization are prerequisite to speedy recovery. However, only optimum liver function and rapid liver regeneration will allow speedy recovery. Liver regeneration will initiate early only if the liver remnant is protected during the operation.[47]

If the donor shows early signs of liver failure, e.g. increasing international normalized ratio, rising serum bilirubin, metabolic acidosis, oliguria, or fluid retention, no time should be wasted to send the donor to the intensive care unit for supportive care. Attention is paid to oxygen saturation and blood pressure. Normal liver perfusion and oxygenation are important for liver recovery and regeneration. The surgeon should not hesitate in giving low-dose inotrope to improve the blood pressure and urine output. Parenteral nutrition consisting of branched-chain amino acid-enriched solution, low-dose glucose, phosphate and medium-chain triglyceride may be useful for liver regeneration.[52] If the donor is not suffering from delayed gastric emptying, oral preparation of branched-chain amino acid-enriched solution is also useful.[53] Continuous veno-venous hemofiltration may have to be used for eliminating ill effects of renal function impairment. The most important step, however, is to identify the cause of liver failure and implement remedial measures. Doppler ultrasonography and contrast-enhanced computed tomography (CT) scan are performed urgently for identification of abnormality of blood flow in the portal vein, hepatic artery and hepatic vein, hematoma around the liver hilum causing compression of the portal vein, and infected collection, etc. Empirical antibiotic cover is given because bacterial translocation is a common event in hepatic decompensation patients. The liver biopsy taken at the end of the recipient operation should be reviewed for any unsuspected pathology of the liver. The threshold for re-laparotomy should be low for any donor who continues to deteriorate even though the cause could not be identified by imaging.

All such measures may induce immense anxiety among the family members, but the surgeon must not be too optimistic and should provide all treatments to prevent the donor from further deterioration and enhance recovery. The donor must not die from the operation, whatever cause it may be.

If the donor liver function continues to deteriorate despite negative finding on vigilant search for the remedial cause, the Molecular Adsorbent Recirculation System should be instituted hoping for spontaneous recovery or preparing for liver transplantation.[8] The exact timing for the Molecular Adsorbent Recirculation System treatment is not well defined. It should be used as a prophylactic treatment against further deterioration, rather than as a salvage procedure. It should therefore be given if the donor is oliguric and his serum creatinine increases rapidly beyond normal level. The decision for liver transplantation is drastic but should not be deferred until the donor's condition is beyond salvage by liver transplantation.

Long-term outcome

There are not many data on the long-term outcome of the donors. It is undeniable that the majority of donors suffer physically, mentally, and socially in the first few months after the donor operation.[54] By the end of the first year, almost half of them had minor symptoms, be it related to the operation or not. However, our survey indicated that none of them received any on-going medical treatment. Two-thirds of the donors considered their recover-

ies complete. Ninety percent of them have returned to the same jobs. The median time to return to work was 9 weeks. The mean Karnofsky Performance Scale returned to 95% after 12 months and was statistically lower than the preoperative score (100%). The donor health transition score dropped precipitously in the first month and returned gradually in the following months but worsening of health was still perceivable in a few donors at the end of the first year. About three-quarters of donors felt that they benefited from the donation, but about 10% of donors would not donate again if there was such a need. Using "willingness to donate again" as a surrogate marker of their experience of the donor operation, donors >35 years of age were found to have more difficulty in adjusting to the operation. Considering that the donor operation is an ultra-major surgery and the recipient outcome is generally satisfactory, despite less satisfactory perception of the operation in a small number of donors, right liver donor hepatectomy is still an acceptable procedure.

The long-term assessment of the donor could have been influenced by the recipient outcome. While a survey in the USA indicated that donors overwhelmingly endorsed donation regardless of the recipient outcome,[55] in a survey conducted in Japan, donors with recipients dying after the operation were more likely unhappy with the donor operation and lost to follow up.[13] Similarly, in Europe, donors with recipient deaths are more likely to report various unspecific complaints and psychosocial conflicts.[56] On this issue, the surgeons must be vigilant in both donor and recipient selections. Donors who have a history of psychological illness are not suitable candidates. Liver pathology that is likely to recur after transplantation should only be accepted for LDLT after careful consideration and discussion. It is the current consensus that living donor donation should only be performed if the risk to the donor is justified by the expectation of an acceptable outcome in the recipient.[13]

Liver regeneration is immense and said to be complete after partial hepatectomy in previous studies on cancer patients. However, studies on living donors indicated that regeneration to the pre-resection volume is less than complete even after 2.5 years of follow-up, though the difference in between pre-resection liver volume and regeneration liver volume is statistically insignificant.[57] There was paradoxically a trend of incompleteness of regeneration in relation to the original liver volume for those with a larger remnant left liver. It may be argued that incomplete regeneration was related to absence of the MHV in the left liver remnant, but studies showed that the lack of regeneration of segment IV is compensated by that of segment II/III.[58] Perhaps the extent of regeneration is related to the metabolic demand of individual donors. Another possible explanation of incomplete regeneration is that bile ducts and blood vessels do not regenerate in proportion to the liver parenchyma. A study on hepatocellular proliferation and changes in architecture of the right liver graft indicated that there is a decrease in the number of portal tracts despite volume restoration.[59]

It has been demonstrated that the donor had thrombocytopenia after right liver donor operation.[12] We did not identify such abnormality among donors (without the MHV in the liver remnant) in our series. Rather, their white blood cell counts were lower, while their serum bilirubin, AST, ALT, and creatinine levels were higher than those before the operation at a median follow-up period of 47.4 months. The difference, though significant, had no clinical consequence because all the changes remained within normal limits.[57] Could the relatively low white cell count be related to hypersplenism? The answer is not clear, but splenomegaly was not discernible on CT scan of the donors under the study. Longer duration of follow-up is needed to unveil other adverse effects of liver donation, similar to living kidney donation.[60]

Conclusion

The outcome of donor operation continues to improve in experienced centers, but it is disheartening to read more and more reports of donor deaths. Donor death has occurred in both experienced and inexperienced centers. Lack of vigilance and loosening of acceptance criteria are the major reasons for the donor mortalities. To avoid further donor death, the transplant surgeon should maintain his/her role as the gatekeeper in preventing unjustified and risky donor operations. Finally, he/she should have full commitment of life-long and holistic care of the donors.

References

1. Dindo D, Demartines N, Clavien PA. Classification of surgical complications: a new proposal with evaluation in a cohort of 6336 patients and results of a survey. Ann Surg 2004; 240: 205-213.
2. Fan ST, Lo CM, Liu CL. Donor hepatectomy for living-donor liver transplantation. Hepatogastroenterology 1998; 45: 34-39.
3. Lo CM, Fan ST, Liu CL, Wei WI, Lo RJW, Lai CL, Chan JKF, Ng IO, Fung A, Wong J. Adult-to-adult living donor liver transplantation using extended right lobe graft. Ann Surg 1997; 226: 261-270.
4. Broering DC, Wilms C, Bok P, Fischer L, Mueller L, Hillert C, Lenk C, Kim JS, Sterneck M, Schulz KH, Krupski G, Nierhaus A, Ameis D, Burdelski M, Rogiers X. Evolution of donor morbidity in living related liver transplantation: a single-center analysis of 165 cases. Ann Surg 2004; 240: 1013-1026.
5. Humar A, Carolan E, Ibrahim H, Horn K, Larson E, Glessing B, Kandaswamy R, Gruessner RW, Lake J, Payne WD. A comparison of surgical outcomes and quality of life surveys in right lobe vs. left lateral segment liver donors. Am J Transplant 2005; 5: 805-809.
6. Pomfret EA, Pomposelli JJ, Lewis WD, Gordon FD, Burns DL, Lally A, Raptopoulos V, Jenkins RL. Live donor adult liver transplantation using right lobe grafts: donor evaluation and surgical outcome. Arch Surg 2001; 136: 425-433.
7. Olthoff KM, Merion RM, Ghobrial RM, Abecassis MM, Fair JH, Fisher RA, Freise CE, Kam I, Pruett TL, Everhart JE, Hulbert-Shearon TE, Gillespie BW, Emond JC; A2ALL Study Group. Outcomes of 385 adult-to-adult living donor liver transplant recipients: a report from the A2ALL Consortium. Ann Surg 2005; 242: 314-325.
8. Brown RS Jr, Russo MW, Lai M, Shiffman ML, Richardson MC, Everhart JE, Hoofnagle JH. A survey of liver transplantation from living adult donors in the United States. N Engl J Med 2003; 348: 818-825.
9. Trotter JF, Hill-Callahan MM, Gillespie BW, Nielsen CA, Saab S, Shrestha R, Talamantes MM, Weinrieb RM; A2ALL Study Group. Severe psychiatric problems in right hepatic lobe donors for living donor liver transplantation. Transplantation 2007; 83: 1506-1508.
10. Umeshita K, Fujiwara K, Kiyosawa K, Makuuchi M, Satomi S, Sugimachi K, Tanaka K, Monden M; Japanese Liver Transplantation Society. Operative morbidity of living liver donors in Japan. Lancet 2003; 362: 687-690.
11. Lo CM. Complications and long-term outcome of living liver donors: a survey of 1,508 cases in five Asian centers. Transplantation 2003; 75(3 Suppl): S12-S15.
12. Rudow DL, Brown RS Jr, Emond JC, Marratta D, Bellemare S, Kinkhabwala M. One-year morbidity after donor right hepatectomy. Liver Transpl 2004; 10: 1428-1431.
13. Barr ML, Belghiti J, Villamil FG, Pomfret EA, Sutherland DS, Gruessner RW, Langnas AN, Delmonico FL. A report of the Vancouver Forum on the care of the live organ donor: lung, liver, pancreas, and intestine data and medical guidelines. Transplantation 2006; 81: 1373-1385.
14. Morelli G, Reed A, Firpi RJ, Machicao V, Abdelmalek MF, Soldevilla-Pico C, Nelson DR. Late presentation of a biliary tract complication after right hepatic donation resulting in secondary biliary cirrhosis. Liver Transpl 2006; 12: 306-309.
15. Sozen H, Karakayali H, Moray G, Dalgic A, Emiroglu R, Haberal M. Analysis of postsurgical complications in 75 living liver transplantation donors. J Gastrointest Surg 2006; 10: 646-651.
16. Poon KS, Fung ST, Jeng LB, Wu RS. Seizure attack during partial hepatectomy in a living donor for liver transplantation under sevoflurane anesthesia. Acta Anaesthesiol Taiwan 2006; 44: 123-126.
17. Hawxby AM, Mason DP, Klein AS. Diaphragmatic hernia after right donor and hepatectomy: a rare donor complication of partial hepatectomy for transplantation. Hepatobiliary Pancreat Dis Int 2006; 5: 459-461.
18. Erim Y, Beckmann M, Valentin-Gamazo C, Malago M, Frilling A, Schlaak JF, Gerken G, Broelsch CE, Senf W. Quality of life and psychiatric complications after adult living donor liver transplantation. Liver Transpl 2006; 12: 1782-1790.
19. Vohra V. Liver transplantation in India. Int Anesthesiol Clin 2006; 44: 137-149.
20. Abofetouh F, Khater Y, Mukhtar A, Salah M, Khedr H, Hamed H, Badawy S. Perioperative management in adult and pediatric living related liver transplantation: an Egyptian experience. Int Anesthesiol Clin 2006; 44: 127-136.
21. Yassen K, Al Abdul Kareem A. Living donor liver transplantation: perioperative experience from Saudi Arabia. Int Anesthesiol Clin 2006; 44: 161-170.
22. Dondero F, Taille C, Mal H, Sommacale D, Sauvanet A, Farges O, Francoz C, Durand F, Delefosse D, Denninger MH, Vilgrain V, Marrash-Chahla R, Fournier M, Belghiti J. Respiratory complications: a major concern after right hepatectomy in living liver donors. Transplantation 2006; 81: 181-186.
23. Shah SA, Grant DR, Greig PD, McGilvray ID, Adcock LD, Girgrah N, Wong P, Kim RD, Smith R, Lilly LB, Levy GA, Cattral MS. Analysis and outcomes of right lobe hepatectomy in 101 consecutive living donors. Am J Transplant 2005; 5: 2764-2769.
24. Wakeno-Takahashi M, Nakao S, Ikeda S, Kaibori M, Yamamoto H, Yanagida H, Kamiyama Y, Shingu K. A case of suspected severe pulmonary embolism in a living-related liver transplantation donor. J Clin Anesth 2005; 17: 218-220.
25. Beavers KL, Sandler RS, Shrestha R. Donor morbidity associated with right lobectomy for living donor liver transplantation to adult recipients: a systematic review. Liver Transpl 2002; 8: 110-117.
26. Durand F, Ettorre GM, Douard R, Denninger MH, Kianmanesh A, Sommacale D, Farges O, Valla D, Belghiti J. Donor safety in living related liver transplantation: underestimation of the risks for deep vein thrombosis and pulmonary embolism. Liver Transpl 2002; 8: 118-120.
27. Ghobrial RM, Saab S, Lassman C, Lu DS, Raman S, Limanond P, Kunder G, Marks K, Amersi F, Anselmo D, Chen P, Farmer D, Han S, Durazo F, Goldstein LI, Busuttil RW. Donor and recipient outcomes in right lobe adult living donor liver transplantation. Liver Transpl 2002; 8: 901-909.
28. Hwang S, Lee SG, Lee YJ, Sung KB, Park KM, Kim KH, Ahn CS, Moon DB, Hwang GS, Kim KM, Ha TY, Kim DS, Jung JP, Song GW. Lessons learned from 1,000 living donor liver transplantations in a single center: how to make living donations safe. Liver Transpl 2006; 12: 920-927.
29. Lee SY, Ko GY, Gwon DI, Song HY, Lee SG, Yoon HK, Sung KB. Living donor liver transplantation: complications in donors and interventional management. Radiology 2004; 230: 443-449.
30. Maluf DG, Stravitz RT, Cotterell AH, Posner MP, Nakatsuka M, Sterling RK, Luketic VA, Shiffman ML, Ham JM, Marcos A, Behnke MK, Fisher RA. Adult living donor versus deceased donor liver transplantation: a 6-year single center experience. Am J Transplant 2004; 5: 149-156.
31. Chan SC, Fan ST, Lo CM, Liu CL, Wong J. Toward current standards of donor right hepatectomy for adult-to-adult live donor liver transplantation through the experience of 200 cases. Ann Surg 2007; 245: 110-117.
32. Boillot O, Dawahra M, Mechet I, Poncet G, Choucair A, Henry L, Boucaud C, Sagnard P, Scoazec JY. Liver transplantation using a right liver lobe from a living donor. Transplant Proc 2002; 34: 773-776.
33. Malago M, Testa G, Frilling A, Nadalin S, Valentin-Gamazo C, Paul A, Lang H, Treichel U, Cicinnati V, Gerken G, Broelsch CE. Right living donor liver transplantation: an option for adult

patients: single institution experience with 74 patients. Ann Surg 2003; 238: 853-862.
34. Miller C, Florman S, Kim-Schluger L, Lento P, De La Garza J, Wu J, Xie B, Zhang W, Bottone E, Zhang D, Schwartz M. Fulminant and fatal gas gangrene of the stomach in a healthy live liver donor. Liver Transpl 2004; 10: 1315-1319.
35. Wiederkehr JC, Pereira JC, Ekermann M, Porto F, Kondo W, Nagima I, Amaral W, Camargo CA, Moreira M. Results of 132 hepatectomies for living donor liver transplantation: report of one death. Transplant Proc 2005; 37: 1079-1080.
36. Akabayashi A, Slingsby BT, Fujita M. The first donor death after living-related liver transplantation in Japan. Transplantation 2004; 77: 634.
37. Malago M, Rogiers X, Burdelski M, Broelsch CE. Living related liver transplantation: 36 cases at the University of Hamburg. Transpl Proc 1994; 26: 3620-3621.
38. Coelho JC, de Freitas AC, Matias JE, de Godoy JL, Zeni Neto C, Parolin MB, Okawa L. Donor complications including the report of one death in right-lobe living-donor liver transplantation. Dig Surg 2007; 24: 191-196.
39. Liver donor dies in city hospital. The Hindu, January 10, 2007.
40. Liver donor's two dates with death. The Times of India, July 11, 2003.
41. Polido W Jr, Hoe LK, Siang NK, Chah TK. Acute myocardial infarction after live donor liver surgery. Liver Transpl 2007; 13: 154-156.
42. Ringe B, Petrucci RJ, Soriano HE, Reynolds JC, Meyers WC. Death of a living liver donor from illicit drugs. Liver Transpl 2007; 13: 1193-1194.
43. Silva M, Mirza DF. Live donor liver transplantation: is this really the way liver transplantation should be developed in India? Natl Med J India 2004; 17: 61-63.
44. Ibrahim S, Chen CL, Lin CC, Yang CH, Wang CC, Wang SH, Liu YW, Yong CC, Concejero A, Jawan B, Cheng YF. Intraoperative blood loss is a risk factor for complications in donors after living donor hepatectomy. Liver Transpl 2006; 12: 950-957.
45. Man K, Fan ST, Ng IO, Lo CM, Liu CL, Wong J. Prospective evaluation of Pringle maneuver in hepatectomy for liver tumors by a randomized study. Ann Surg 1997; 226: 704-711.
46. Nakamura S, Tsuzuki T. Surgical anatomy of the hepatic veins and the inferior vena cava. Surg Gynecol Obstet 1981; 152: 43-50.
47. Fan ST. Protection of the liver during partial hepatectomy. HBP Dis Int 2004; 3: 490-494.
48. Yong BH, Tsui SL, Leung CC, Lo CM, Liu CL, Fan ST, Young K. Management of postoperative analgesia in living liver donors. Transplant Proc 2000; 32: 2110.
49. Rostom A, Muir K, Dube C, Jolicoeur E, Boucher M, Joyce J, Tugwell P, Wells GW. Gastrointestinal safety of cyclooxygenase-2 inhibitors: a cochrane collaboration systematic review. Clin Gastroenterol Hepatol 2007; 5: 818-828.
50. Choi SJ, Gwak MS, Ko JS, Kim GS, Ahn HJ, Yang M, Hahm TS, Lee SM, Kim MH, Joh JW. The changes in coagulation profile and epidural catheter safety for living liver donors: a report on 6 years of our experience. Liver Transpl 2007; 13: 62-70.
51. Liu SS, Richman JM, Thirlby RC, Wu CL. Efficacy of continuous wound catheters delivering local anesthetic for postoperative analgesia: a quantitative and qualitative systematic review of randomized controlled trials. J Am Coll Surg 2006; 203: 914-932.
52. Fan ST, Lo CM, Lai EC, Chu KM, Liu CL, Wong J. Perioperative nutritional support in patients undergoing hepatectomy for hepatocellular carcinoma. N Engl J Med 1994; 331: 1547-1552.
53. Fan ST, Tsui SL. Perioperative care of patients with hepatocellular carcinoma undergoing hepatectomy. Dig Surg 1995; 12: 53-60.
54. Chan SC, Liu CL, Lo CM, Lam BKY, Lee EWM, Fan ST. Donor quality of life before and after adult-to-adult right liver live donor liver transplantation. Liver Transpl 2006; 12: 1529-1536.
55. Diaz GC, Renz JF, Mudge C, Roberts JP, Ascher NL, Emond JC, Rosenthal P. Donor health assessment after living-donor liver transplantation. Ann Surg 2002; 236: 120-126.
56. Walter M, Papachristou C, Pascher A, Danzer G, Neuhaus P, Klapp BF, Frommer J. Impaired psychosocial outcome of donors after living donor liver transplantation: a qualitative case study. Clin Transplant 2006; 20: 410-415.
57. Chan SC, Lo CM, Wong Y, Liu CL, Fan ST. Long-term biological consequences of donor right hepatectomy including the middle hepatic vein in adult-to-adult live donor liver transplantation. Liver Transpl 2006; 12: 259-263.
58. Hata S, Sugawara Y, Kishi Y, Niiya T, Kaneko J, Sano K, Imamura H, Kokudo N, Makuuchi M. Volume regeneration after right liver donation. Liver Transpl 2004; 10: 65-70.
59. Huang R, Schiano TD, Amolat MJ, Miller CM, Thung SN, Saxena R. Hepatocellular proliferation and changes in microarchitecture of right lobe allografts in adult transplant recipients. Liver Transpl 2004; 10: 1461-1467.
60. Ramcharan T, Matas AJ. Long-term (20-37 years) follow-up of living kidney donors. Am J Transplant 2002; 2: 959-964.

10. Recipient results

More than ten years have lapsed since the first successful adult-to-adult living donor liver transplantation (LDLT) was performed. There are now sufficient data to evaluate whether further pursuing of the operation is worthwhile.

Our results

From 1994 to 2006, we performed 273 adult-to-adult LDLT. Amongst them, 20 were left liver graft operations. The rest were operations utilizing the right liver grafts, all except one containing the middle hepatic vein (MHV). There has been an increase in the number of operations carried out in recent years. The overall hospital mortality rate was 4.7% (Table 10.1). During the period between 2000 and 2004, there were 110 consecutive right liver LDLT without hospital mortality. The median intensive care unit stay of the recipients decreased from 15 days to 3 days. Blood transfusion requirement has decreased from the median of 11 units in the early period to 1 unit in recent years. About 20% of the recipients did not require exogenous blood transfusion.

In our previous analysis of the first 100 cases of right liver LDLT, graft weight/estimated standard liver weight ratio ≤0.35, low body temperature recorded during operation, and MHV occlusion were independent significant factors in determining hospital mortality[1] (Figure 10.1). These factors are probably inter-related in causing mortality. For instance, hypothermia might have been caused by suboptimal graft function, massive blood transfusion and use of veno-venous bypass. Both small graft size and graft congestion contributed to suboptimal graft function. Graft congestion as a result of MHV occlusion led to massive bleeding from the liver transection surface, which in turn predisposed to hypothermia subsequent to massive blood transfusion. Hypothermia in turn impaired the platelet function. Hypothermia and the consequent metabolic disturbance were not easily corrected unless the graft regained function. All of these correlations attested to the importance of perfect venous outflow of the liver graft. Since veno-venous bypass carries other serious side effects, it is no longer performed nowadays.[2] In the subsequent years, ensuring a graft size of at least 35% of the estimated liver volume,

Table 10.1. Intraoperative and postoperative data of patients receiving right liver living donor liver transplantation at Queen Mary Hospital, The University of Hong Kong.

Year	Cases	MELD score (median)	Recipient hospital mortality	ICU stay (days) (median)	Blood transfusion (unit) (median)	Recipient without blood transfusion
1996	8	47	1	15	11	0
1997	0	-	-	-	-	-
1998	8	32	1	7	16.5	0
1999	12	26	4	6	15	0
2000	31	20	2	4	6	1
2001	30	25	0	4	6	5
2002	29	27	0	3	4	10 (34%)
2003	28	31	0	6	4.5	4 (14%)
2004	42	26	2	4	4	13 (31%)
2005	32	27	2	4	2.5	6 (19%)
2006	33	14	0	3	1	15 (45%)
	253		12 (4.7%)			

MELD, Model for End-stage Liver Disease; ICU, intensive care unit

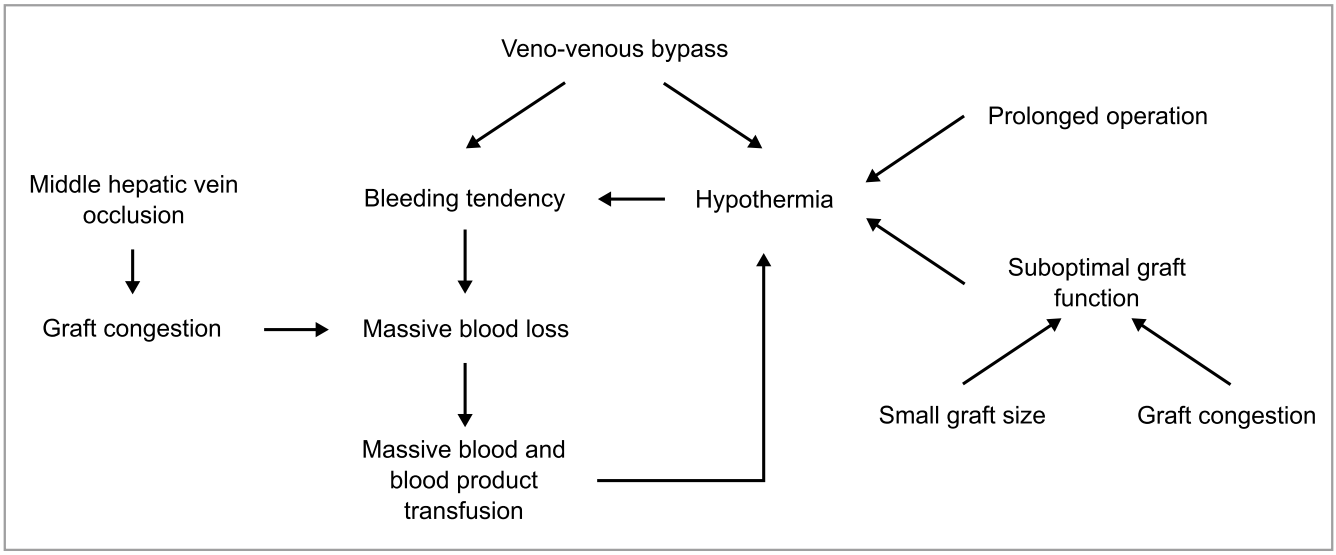

Figure 10.1. Interrelationship between various factors leading to hypothermia and massive bleeding.

attention to venous outflow reconstruction and meticulous attention to protect the patient from hypothermia resulted in reduction of the hospital mortality rate from 16% of the first 50 patients to 2.6% of the subsequent 150 patients. In these 150 patients, multivariate analysis indicated that high preoperative serum creatinine level is the only factor determinant of hospital mortality.

The long-term survival is satisfactory for right liver grafts. The 1-year and 5-year survival rates are 93.3% and 82.8%, respectively (Figure 10.2). Most of the late deaths are due to recurrence of hepatocellular carcinoma (HCC). Multivariate analysis indicates that preoperative diagnosis of HCC is the only independent significant factor determining late mortality (relative risk 3.0). If HCC patients are not included, the 5-year survival rate is 89%. For left liver graft adult recipients, the overall 5-year survival rate is 83.3%. The majority of dropouts of left liver graft recipients occurred in the early postoperative period.

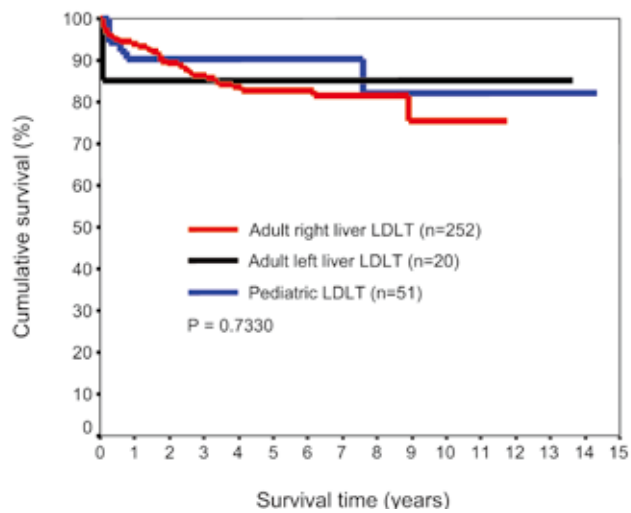

Figure 10.2. Survival curves of patients receiving right liver living donor liver transplantation (LDLT), left liver LDLT and pediatric LDLT.

Results of other centers

Early results of right liver LDLT appears satisfactory but long-term outcome reports are uncommon[3-11] (Table 10.2). The reports involving large series of patients are from the USA. They are surveys of patients operated in many centers. On the whole, a 1-year graft survival rate of 75%–80% is now attained.

LDLT vs DDLT

To assess the outcome of right or left living donor liver graft operation, the recipients of split or reduced deceased donor liver grafts of the corresponding side should be the subjects for comparison. However, the number of split or reduced liver grafts may not be sufficient for valid comparison. Thus, whole-graft deceased donor recipients would be the subjects for comparison with the right liver graft recipients.

Early studies from Western countries showed that despite selection of recipients with better health status before liver transplantation, right liver LDLT

Table 10.2. Survival rates of adult recipients after right liver living donor liver transplantation.

Author	Journal	Year published	No. of patients	Graft survival						Patient survival					
				3 mths	1 yr	2 yrs	3 yrs	4 yrs	5 yrs	3 mths	1 yrs	2 yrs	3 yrs	4 yrs	5 yrs
Ghobrial[3]	Liver Transpl	2002	20	–	85%	–	–	–	–	–	95%	–	–	–	–
Shiffman[4]	Liver Transpl	2004	23	–	–	82%	–	–	–	–	–	82%	–		–
Thuluvath[5]	Liver Transpl	2004	764	–	–	64.4%	–	–	–	–	–	80%	–		–
Abt[6]	Am J Transplant	2004	793	–	78.5%	–	–	–	–	–	87.4%	–	–	–	–
Malago[7]	Ann Surg	2004	74	–	75.3%	–	–	–	–	–	79.4%	–	–	–	–
Olthoff[8]	Ann Surg	2005		87%	81%	–	–	–	–	94%	89%	–	–		–
Maluf[9]	Am J Transplant	2005	69	–	78%	–	72.6%	–	72.6%	–	78.8%	–	73.4%		73.4%
Akamatsu[10]	Surgery	2006	83	–	–	–	–	–	–	–	91%	–	84%	–	84%
Terrault[11]	Liver Transpl	2007	181	–	–	–	68%	–	–	–	–	–	74%		–
Our series			253	95.3%	92.5%	88.9%	85.2%	81.9%	80.1%	95.6%	93.2%	89.6%	85.9%	82.6%	82.6%

did not result in better patient and graft survival rates compared with whole-graft deceased donor liver transplantation (DDLT).[5,6,12] Patients with high urgency status in the intensive care unit were at a higher risk of graft failure if they received LDLT. The conclusion from these studies is that adult-to-adult LDLT should be best applied in a more selected patient population. In Asian countries with a scarce availability of deceased donor grafts, LDLT is the only option for all types of patients. Yet the result is quite satisfactory, even for patients with high urgency status.[13] We demonstrated in a recent study[14] that despite smaller graft size and higher technical complexity, the graft (88% vs 84%) and patient (90% vs 84%) survival rates of patients having right liver LDLT are not different from those of patients receiving whole-graft DDLT[14] (Figures 10.3 and 10.4). The only difference is a higher incidence of biliary complications in the LDLT patients (25.8% vs 7.1%). Similar outcome was reported by Maluf et al,[9] though their patients were less ill and did not have the MHV in their grafts. The satisfactory outcome in our center even for patients with very high Model for End-stage Liver Disease (MELD) scores is likely related to our routine inclusion of the MHV in the graft and the short waiting time (Tables 10.3–10.5).

Right liver LDLT offers patients listed for liver transplantation an incremental benefit by tripling the transplant rate in our center. Based on the intention-to-treat analysis, i.e. all patients are included in the analysis once they are listed, LDLT offers a survival

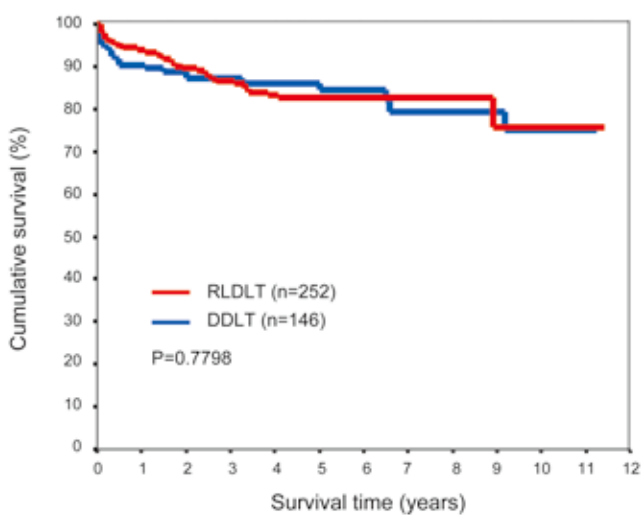

Figure 10.3. Cumulative patient survival of the right liver living donor liver transplantation (RLDLT) group (n=252) and the whole-graft deceased donor liver transplantation (DDLT) group (n=146).

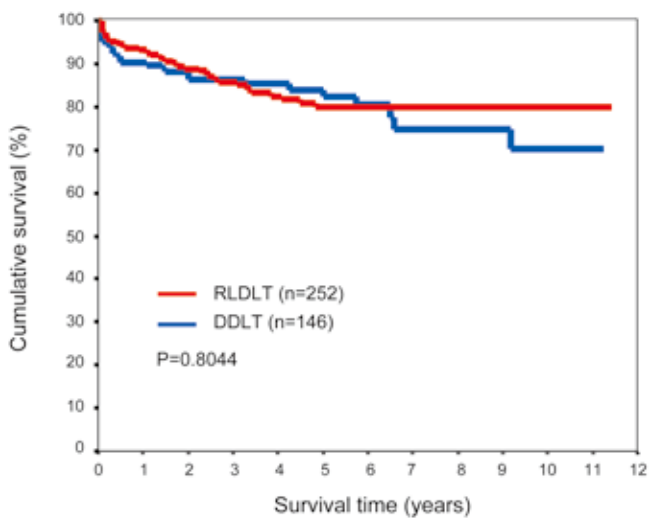

Figure 10.4. Cumulative graft survival of the right liver living donor liver transplantation (RLDLT) group (n=252) and the whole-graft deceased donor liver transplantation (DDLT) group (n=146).

Table 10.3. Preoperative clinical parameters of 252 patients who underwent right liver living donor liver transplantation (RLDLT) and those of 146 patients who underwent whole-graft deceased donor liver transplantation (DDLT) at Queen Mary Hospital, The University of Hong Kong. One re-transplant RLDLT is not included in the analysis.

Parameter	RLDLT	DDLT	P value
No. of patients	252	146	--
Male : female	199 : 53	108 :38	0.253
Age (year)	48 (17–68)	48 (19–66)	0.486
Chronic hepatitis B infection	205 (81.3%)	103 (70.5%)	0.013*
Hepatocellular carcinoma	74 (29.4%)	23 (15.8%)	0.002*
MELD scores	26 (6–59)	20 (6–56)	0.148
Fulminant hepatic failure	23 (9.1%)	5 (3.4%)	0.032*
Acute-on-chronic hepatic failure	90 (35.7%)	34 (23.3%)	0.010*
Patients in intensive care unit	90 (35.7%)	25 (17.1%)	0.000*
Patients on life support	44 (17.5%)	9 (6.2%)	0.001*
Serum total bilirubin (μmol/L)	169.5 (8–1209)	92 (8–984)	0.115
Serum AST (U/L)	92.5 (21–10000)	66.5 (11–3840)	0.000*
Blood ammonia (μmol/L)	74 (4–275)	56 (10–713)	0.004*
Prothrombin time (sec)	23.75 (10.8–110)	19.4 (11.1–110)	0.018*
Waiting time on list (days)	11.5 (0.42–1406)	181.5 (0.08–2617)	0.000*

* P<0.05
Continuous data are expressed as median with range in parentheses
MELD, Model for End-stage Liver Disease; AST, aspartate aminotransferase

Table 10.4. Operative data of 252 patients who underwent right liver live donor liver transplantation (RLDLT) and those of 146 patients who underwent whole-graft deceased donor liver transplantation (DDLT) at Queen Mary Hospital, The University of Hong Kong.

Parameter	RLDLT	DDLT	P value
Graft weight (g)	600 (320–1140)	1155 (708–1800)	0.000*
Graft weight / donor body weight	1.056 (0.73–1.73)	1.936 (1.09–2.78)	0.000*
Graft weight / recipient body weight	0.907 (0.49–1.95)	1.796 (1.04–3.11)	0.000*
Graft weight / recipient ESLV (%)	49.0 (28.4–89.4)	97.1 (59.3–160.5)	0.000*
Graft cold ischemic time (min)	110 (59–345)	403 (242–884)	0.000*
Operating time (min)	692.5 (400–1440)	545 (269–1246)	0.000*
Implantation time (min)	259 (149–628)	245.5 (22–577)	0.028*
Intraoperative blood product transfusion (unit)			
Red blood cell	5 (0–43)	5 (0–148)	0.119
Fresh frozen plasma	10 (0–48)	10 (0–49)	0.988
Platelet concentrate	8.5 (0–53)	10 (0–79)	0.039*
No. of patients without blood transfusion	55 (21.8%)	16 (11%)	0.006*

* P<0.05
Continuous data are expressed as median with range in parentheses
ESLV, estimated standard liver volume

Table 10.5. Postoperative data of 252 patients who underwent right liver living donor liver transplantation (RLDLT) and those of 146 patients who underwent whole-graft deceased donor liver transplantation (DDLT) at Queen Mary Hospital, The University of Hong Kong.

Parameter	RLDLT	DDLT	P value
Postoperative intensive care unit stay (days)	4 (1–124)	4.5 (1–125)	0.696
Postoperative hospital stay (days)	19 (7–183)	17.5 (0–1163)	0.484
Operative morbidity	105 (41.7%)	68 (46.6%)	0.341
Hospital mortality	12 (4.8%)	10 (6.8%)	0.380
Follow-up duration* (months)	41.5 (0.33–136.9)	45.7 (0–134.8)	0.782
Biliary complication	70 (27.8%)	16 (11%)	0.000†
Biliary leakage	15 (6%)	4 (2.7%)	0.222
Biliary stricture	61 (24.2%)	13 (8.9%)	0.000†
Actuarial graft survival on follow-up	211 (83.7%)	120 (82.2%)	0.693
Actuarial patient survival on follow-up	214 (84.9%)	123 (84.2%)	0.857

* Minimum follow-up duration for patients who were alive was 6 months
† P<0.05
Continuous data are expressed as median with range in parentheses

advantage over that of DDLT.[15] The survival benefit was confirmed by three subsequent reports.[16-18]

Acute liver failure

It has been suggested that right liver grafts from living donors are marginal grafts and right liver LDLT should not be performed in patients with poor preoperative health status, including those with fulminant hepatic failure, acute-on-chronic liver diseases, those who are intensive care unit-bound, and those who are on life support. However, our experience indicated that right liver LDLT is equally successful in patients with acute liver failure and cirrhosis, when compared with DDLT (Table 10.6 and Figure 10.5). A right liver graft containing the MHV could meet the metabolic demand of a patient with very high preoperative MELD score, sepsis, hepatorenal syndrome, and on hemodialysis. The adequate venous outflow of the right liver graft can also alleviate portal hypertension effectively, allowing the patient to recover from liver failure rapidly.

Left liver graft vs right liver graft

There are not many studies that compare the outcome of right liver graft LDLT with that of left liver LDLT. In an early report from Japan, Shimada et al[19] reported that despite larger graft size, the right liver graft (without MHV) did not provide a superior result to that of the left liver graft. Similar results were reported by Soejima et al.[20] In a recent analysis by Akamatsu et al,[10] the larger right liver grafts were transplanted into patients with higher MELD scores. The outcomes of right liver graft recipients were similar to those of left liver grafts (1-year survival rate 91% vs 93%). The authors therefore concluded that "a properly selected left liver graft can be used as safely as a right liver graft", and the left liver graft could be implanted in patients with

Table 10.6. Results of the right liver graft (including the middle hepatic vein) at Queen Mary Hospital, The University of Hong Kong for different types of liver disease.

	No. of transplants	MELD score	Graft weight to ESLW (%)	Graft weight to recipient body weight (%)	Hospital mortality
Cirrhosis	137	16 (6–41)	48.8 (31.5–79.5)	0.9 (0.55–1.41)	5 (3.6%)
Cirrhosis with acute deterioration	51	35 (15–59)	47 (28.5–68.9)	0.88 (0.49–1.34)	3 (5.9%)
Chronic active hepatitis acute flare	39	37 (23–52)	49.7 (35.1–86.9)	0.93 (0.6–1.95)	3 (7.7%)
Fulminant hepatic failure	23	36 (27–50)	53.6 (39.7–89.4)	1.01 (0.74–1.92)	1 (4.3%)

MELD, Model for End-stage Liver Disease; ESLW, estimated standard liver weight

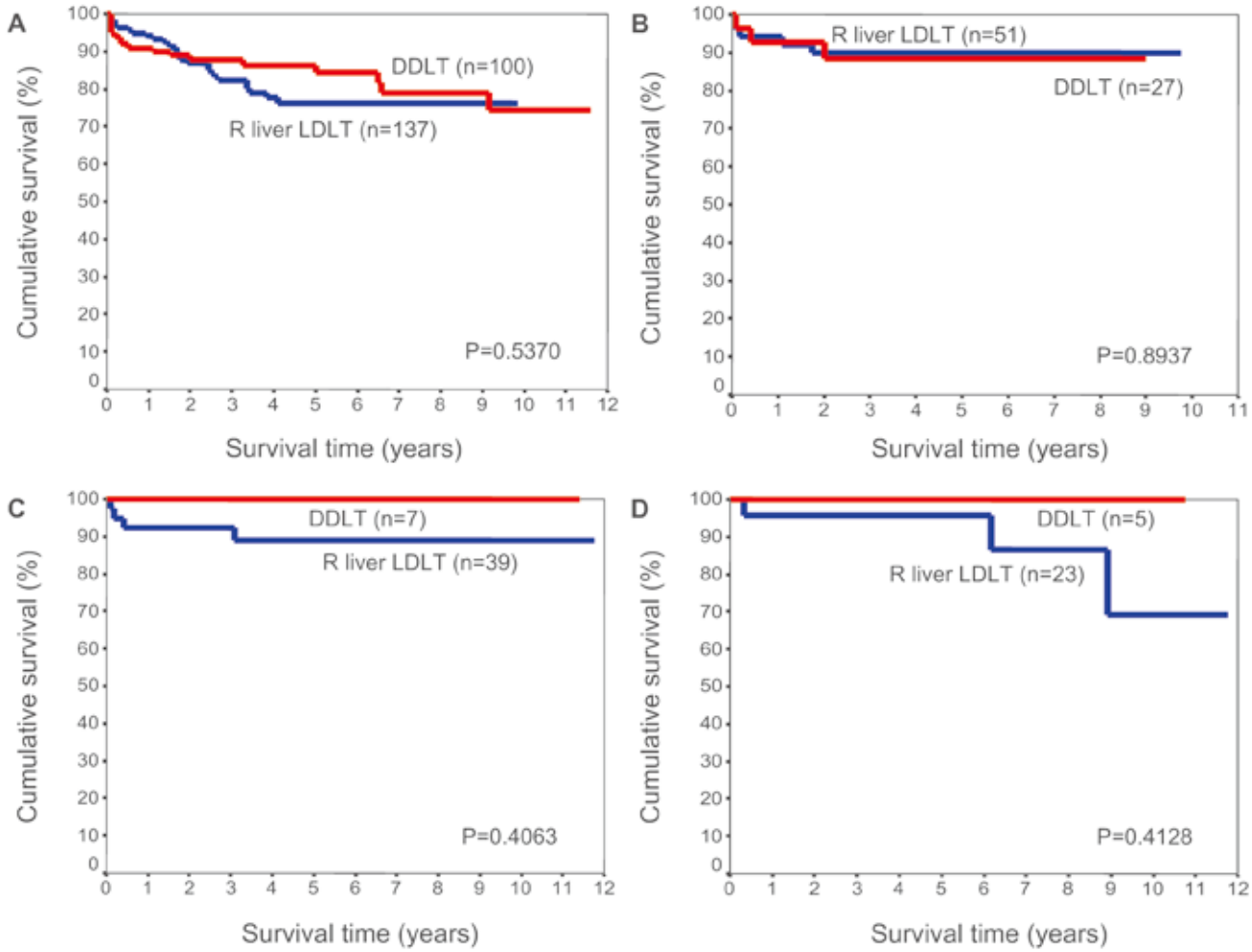

Figure 10.5A-D. Comparison of long-term survival of patients with cirrhosis **(A)**, cirrhosis with acute deterioration **(B)**, chronic hepatitis B with acute flare **(C)**, and fulminant hepatic failure **(D)** receiving right liver grafts (including the middle hepatic vein) with those receiving whole deceased donor grafts.

low MELD scores. However, the problem with Akamatsu's study is that about 80% of the right liver grafts did not contain the MHV, whereas the left liver graft contained the MHV routinely. The lack of MHV renders venous drainage of the right anterior sector poor, liver function suboptimal,[10] and liver regeneration impaired.[21] Perhaps the unsatisfactory design of the right liver graft renders the left liver graft appearing superior. In both Shimada's and Akamatsu's studies, the right and left liver grafts and their recipients were not strictly comparable. To provide a valid comparison, we chose patients receiving right and left liver grafts of a similar size and with the MHV in all grafts in our series for comparison. The two groups of patients did not differ in terms of donor age, recipient age, MELD score and proportion with Child-Pugh C liver function status.[22] For the donors, the operation time was longer, blood loss volume higher and postoperative serum alanine aminotransferase (ALT) levels higher in the left liver graft group. The higher serum ALT levels are explained by the larger volume of undrained segment V/VIII in left liver donation than the undrained segment IV in right liver donation. The postoperative complications, however, was lower in incidence (0% vs 6.9%), and postoperative international normalized ratio and serum bilirubin levels were lower than the right liver donors. The overall safety profile of donor left hepatectomy is higher. However, with gram-to-gram equivalence, the outcome in the left liver graft recipients was disappointing in that the hospital mortality was higher (18.8% vs 6.9%), the duration of intensive care unit stay was longer (8.5 days vs 4 days), hyperbilirubinemia was prolonged, and serum aspartate aminotransferase and ALT levels were much higher than the right liver recipients. The major reason accounting for the difference in recipient results

is graft injury during implantation and on wound closure. Because of the intrinsic problem of limited space in between the spine and costal arch, after graft expansion on portal vein reperfusion, the graft could not be accommodated wholly in the upper abdomen. The left liver graft, especially when it is globular in shape, is subjected to ischemic injury by the retractor or costal arch during hepatic artery and bile duct reconstruction and by the wound on closure[23] (Figure 10.6). Retractor placed over the liver hilum for exposure during hepatic artery and bile duct reconstruction compresses the portal vein as well as the caudal part of the liver graft against the rib cage. Sometimes, elevation of the left liver graft for hilar exposure may reduce the portal blood flow. On the other hand, the right liver graft is located in the spacious right subphrenic space and is free from any injury once it is implanted. Thus, we consider that the right liver graft (including the MHV) is preferred for the majority of adult-to-adult LDLT. The left liver graft is reserved for the occasional case that a large size donor can provide more than 40% of the estimated standard liver volume of the recipient or when there is vascular or biliary anomaly that precludes right liver donation,[24] and is preferably for low MELD score patients. If the left liver graft is chosen, attention should be paid to avoid all the aforementioned possible causes of graft injury. The left subcostal wound should be sufficiently long to allow upward retraction and accommodation of the left liver graft. It is tempting to rotate the left liver graft into the right subphrenic space, but venous outflow blockade may occur, and the left portal vein may be stretched and twisted as well. Doppler ultrasonography must be performed whenever necessary to determine the most optimal position of the left liver graft in the upper abdominal cavity.

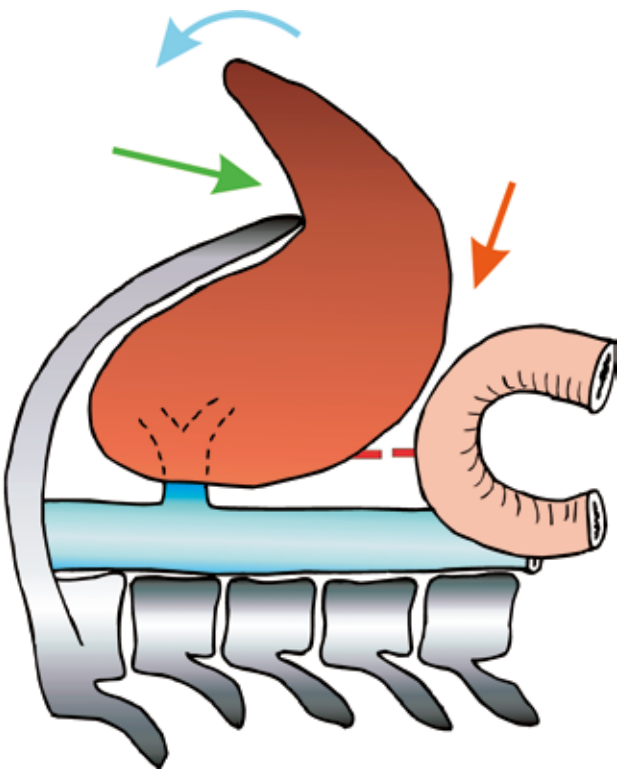

Figure 10.6. It is difficult to accommodate a large left liver graft in the upper abdominal cavity in between the costal arch and spine. The graft is subject to ischemic injury during exposure of the liver hilum for hepatic artery and bile duct reconstruction.[23]

Hepatocellular carcinoma

Hypothetical models suggested that LDLT is a good option for patients with HCC because definitive treatment could be carried out soon after transplant workup and tumor dissemination while waiting for a deceased donor graft could be avoided, especially for patients who are disadvantaged by allocation algorithm for grafts from deceased donors.[25,26] The model assumed that living liver donor supply is abundant. In practice, there is limitation in living liver donation. Only about 14%–41% of the donors after evaluation underwent donor operation eventually.[27-29] At present, there is no randomized trial showing that LDLT is superior to DDLT for HCC. Rather, retrospective studies suggested that LDLT may have worse results than DDLT.[30-32] Such comparison is not totally valid because patients having DDLT had longer waiting time than those with LDLT. The HCC patients with DDLT are a distinct and selected group because their counterparts are delisted due to HCC growth or dissemination while waiting. It is not unlikely that patients who eventually received DDLT had less aggressive HCC. This is reflected by the almost 100% HCC recurrence-free survival rate of DDLT patients in the two clinical studies[31,32] (Figure 10.7). On the other hand, patients with LDLT may have HCC of a wide range of aggressiveness because the transplant is done earlier and there is little selection based on the tumor growth rate. Better selection of patients based on biological behaviors may avoid the disappointing results of LDLT for HCC. Features that may predict more favorable biological behaviors include well

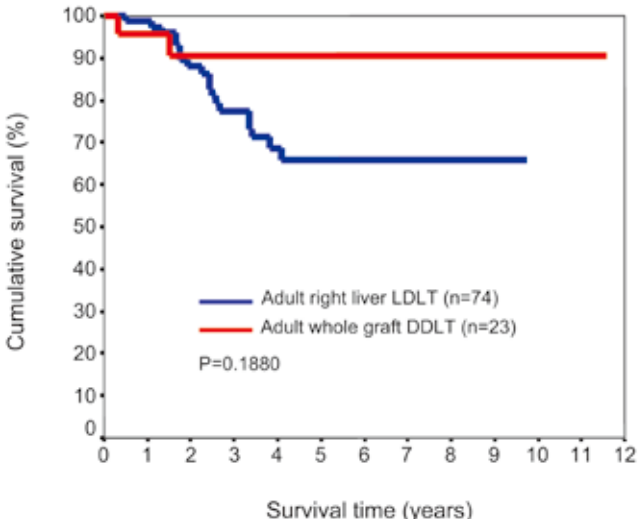

Figure 10.7. Comparison of survival rates of hepatocellular carcinoma patients receiving right liver living donor liver transplantation (LDLT) and whole-graft deceased donor liver transplantation (DDLT).

differentiation of the tumors and certain genome characteristics,[33] but tumor biopsy is required for the study and is not always feasible. Detection of circulating cancer cells may be more feasible, but at present, the available markers do not have very high specificity and sensitivity that allow routine clinical use.[34,35] A practical approach is to observe the tumor growth rate or its response to non-operative treatment. Whether this will lead to better survival outcome is not known.

There could be other reasons accounting for higher HCC recurrence after LDLT for HCC. During recipient hepatectomy, since the hepatoduodenal ligament and inferior vena cava have to be preserved, there may be less lymph node removal and more liver manipulation. It has been shown in previous studies that tumor compression could be responsible for appearance of circulating cancer cells in the blood.[36] Rapid liver regeneration of the partial liver graft may be accompanied by rapid HCC growth when such circulating cancer cells deposit in the new liver. A further possibility is related to small-for-size graft injury in which the endothelium is damaged by hyperdynamic portal blood flow.[37] In a clinical study, we showed that grafts that are less than 60% of the estimated standard liver volume are associated with higher HCC recurrence.[38-40] The enhanced inflammatory cascades within the liver (and probably outside the liver as well) together with rapid liver regeneration, leading to cell adhesion, angiogenesis, cell invasion and migration, confer a favorable microenvironment for the circulating cancer cells to deposit and grow[38-40] (Figure 10.8). Thus, treatment that ameliorates small-for-size graft injury may have the potential of reducing intrahepatic recurrence.

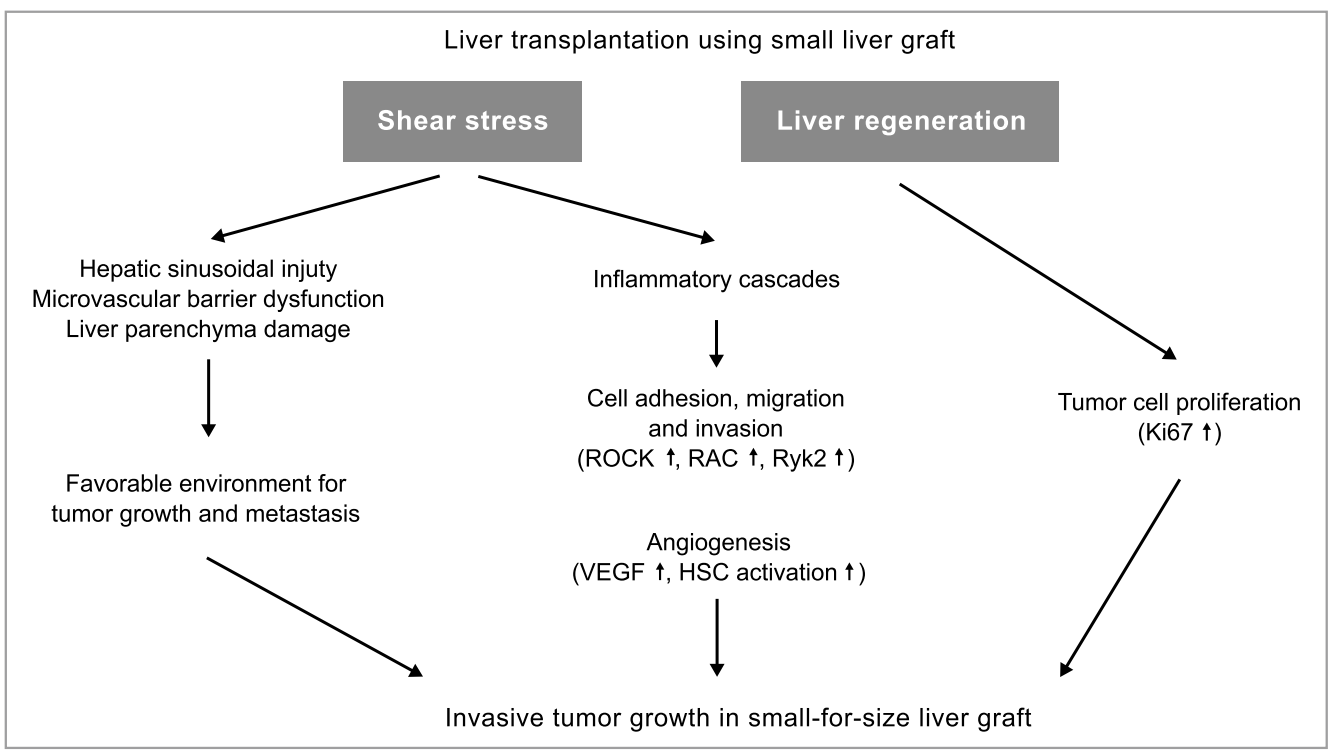

Figure 10.8. Possible factors of acute phase injury and late phase tumor recurrence.

Is the small living donor liver graft to be blamed for the unsatisfactory result and higher HCC recurrence? In the three recent clinical studies,[31,32,41] the living donor liver graft itself was not identified to be one of the independent significant variables in predicting HCC recurrence on multivariate analysis. Rather, the previous treatment that failed to control the HCC and thus the indication for liver transplantation is the risk factor. In other words, aggressive biological behavior remains to be an important factor for recurrence, be it DDLT or LDLT. In fact, Hwang et al[42] did not find a difference in the survival rates between patients who received LDLT and DDLT for HCC.

Despite the concern that LDLT patients may have a higher chance of HCC recurrence, LDLT continues to be performed regularly in Asia because this is almost the only option in some Asian countries. Todo et al[43] reported a 3-year survival rate of 68%. Hwang et al[42] reported a 5-year survival rate of 58%, and Lo et al[31] reported a 5-year overall survival rate of 58%. Takada et al[44] reported a 4-year survival rate of 66% for patients with HCC within the Milan criteria and 60% for patients beyond the Milan criteria. Soejima et al[45] reported a 3-year recurrence-free survival rate of 74% for patients whose HCC exceeded the Milan criteria. In the rest of the world, Jonas et al[46] reported a 3-year survival rate of 53% in patients with HCC not meeting the University of California San Francisco criteria. Gondolesi et al[47] employed neoadjuvant treatment and reported a 1-year survival rate of 75% for patients after LDLT who were beyond the United Network for Organ Sharing priority criteria. Although the survival rate is less than that of non-HCC LDLT, or DDLT for HCC, when one considers that there is no other option of treating inoperable HCC with Child C liver function status, a 4-year survival rate of 60%[44] or 3-year disease-free survival rate of 55%[43] for patients whose tumors did not meet the Milan criteria is still superior to any modality of non-surgical treatment for HCC, particularly for those with poor liver function. The only consideration is whether the donor would consider a 4-year survival rate of 60% acceptable after going through the agony of an ultra-major donor hepatectomy. Donor dissatisfaction is frequently related to recipient death.[48] Further improvement of the overall results including donor satisfaction, therefore, depends on better recipient selection. A biological criterion that predicts tumor aggressiveness and dissemination[35,49] may be more appropriate than immunological,[50] radiological,[51] or pathological criteria.[52] However, highly accurate biological criteria are still lacking.[49]

Hepatitis B

The overall survival rate of hepatitis B patients without HCC in their explants receiving LDLT is comparable with similar patients receiving DDLT with non-HCC hepatitis B patients receiving LDLT (Figure 10.9). The incidence of hepatitis B virus recurrence in our patients who received lamivudine monotherapy only [without hepatitis B immunoglobulin (HBIG)] (defined as mutant breakthrough) is about 12%. The peculiar feature of hepatitis B patients after liver transplantation is the spontaneous development of hepaitits B surface antibody (HBsAb) in 46% and transient disappearance of hepatitis B surface antigen in about 90% of patients (Table 10.7). The phenomenon, though transient, occurs in the absence of HBIG and in the presence of lamivudine monotherapy. It is probably due to the fact that many donors themselves are HBsAb positive, either from previous infection or vaccination. Lymphocytes that are capable of producing HBsAb are transferred with the grafts to the recipients.[53] LDLT is therefore more advan-

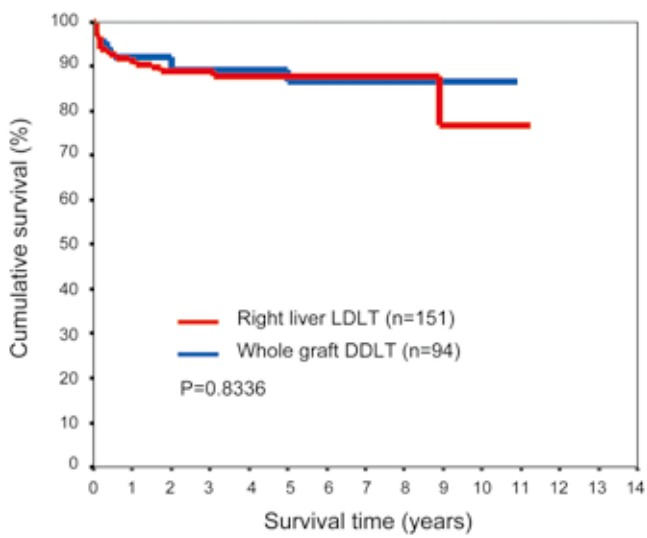

Figure 10.9. Comparison of survival rates of non-hepatocellular carcinoma hepatitis B surface antigen patients receiving right liver living donor liver transplantation (LDLT) and whole-graft deceased donor liver transplantation (DDLT).

Table 10.7. Results of hepatitis B virus (HBV) patients receiving lamivudine monoprophylaxis.

	Adult-to-adult LDLT (n=194)		DDLT (n=98)
HBeAg+ before transplant	55		26
HBV DNA+ before transplant	101		42
Overall survival rate	162 (83.5%)		88 (89.8%)
Causes of mortality			
HBV related	0		0
Others	32		10
Acute pancreatitis and aspergillosis	1	Aspergillosis	1
Biliary stenosis	1	Bacterial endocarditis	1
Candidiasis	1	Cardiac failure	1
Thrombotic thrombocytopenic purpura	1	Graft failure and rejection	2
Congestive heart failure	1	Hepatic vein thrombosis	1
Dissecting aortic aneurysm	1	Intracerebral hemorrhage	1
Empyema thoracis	1	Malignant cachexia	1
Suicide	1	Pneumonia	1
Gastrointestinal bleeding	1	Respiratory failure	1
Hepatic vein stenosis	1		
Legionnaire's disease	1		
Malignant cachexia	14		
Multiorgan failure	1		
Myeloblastic leukemia	1		
Necrotizing pancreatitis	1		
Non-occlusive mesenteric ischemia	1		
Peritonitis and subarachnoid hemorrhage	1		
Primary graft nonfunction	1		
Respiratory failure	1		
HBV breakthrough (YMDD mutation)	23 (11.9%)		16 (16.3%)
HBsAg– after transplant	179 (92.3%)		81 (82.7%)
HBsAb+ after transplant	90 (46.4%)		40 (40.8%)

LDLT, living donor liver transplantation; DDLT, deceased donor liver transplantation; HBsAg, hepatitis B surface antigen; HBsAb, hepatitis B surface antibody

tageous than DDLT because the potential donors can be vaccinated before the operation and render themselves HBsAb positive. By this strategy, a greater extent of protection from hepatitis B recurrence in the recipients could be assured and the cost of HBIG eliminated.[54]

Hepatitis C

Hepatitis C cirrhosis is one of the most common indications for LDLT in North America and Europe. There are data suggesting that hepatitis C might recur earlier and the incidence of severe recurrence was higher for hepatitis C patients undergoing LDLT,[55,56] but other recent data showed that the outcome was approximately equal to that of DDLT.[4,11,57,58] Perhaps, the early unsatisfactory result is due to technical problems leading to graft damage, rather than early reinfection of the liver graft by hepatitis C.[59] In the early cases, venous drainage reconstruction of the right liver graft might be defective. It is difficult to differentiate on histology whether the graft damage is due to outflow obstruction, hyperdynamic damage, or hepatitis C reinfection.

Conclusion

The overall result of LDLT is satisfactory. The current benchmark for comparison is DDLT. In fact, the right liver graft (especially with the MHV) should be a more reliable graft than the deceased donor graft. However, the current result of LDLT in adults is tainted by the higher recurrence rate of HCC in the recipients. The direction to improve the result further is to design a strategy to reduce HCC

recurrence and perhaps small-for-size graft damage, which would allow a wider applicability to the patients who are not considered appropriate candidates in the current era.

References

1. Fan ST, Lo CM, Liu CL, Yong BH, Wong J. Determinants of hospital mortality of adult recipients of right lobe live donor liver transplantation. Ann Surg 2003; 238: 864-870.
2. Fan ST, Yong BH, Lo CM, Liu CL, Wong J. Right lobe living donor liver transplantation with or without venovenous bypass. Br J Surg 2003; 90: 48-56.
3. Ghobrial RM, Saab S, Lassman C, Lu DS, Raman S, Limanond P, Kunder G, Marks K, Amersi F, Anselmo D, Chen P, Farmer D, Han S, Durazo F, Goldstein LI, Busuttil RW. Donor and recipient outcomes in right lobe adult living donor liver transplantation. Liver Transpl 2002; 8: 901-909.
4. Shiffman ML, Stravitz RT, Contos MJ, Mills AS, Sterling RK, Luketic VA, Sanyal AJ, Cotterell A, Maluf D, Posner MP, Fisher RA. Histologic recurrence of chronic hepatitis C virus in patients after living donor and deceased donor liver transplantation. Liver Transpl 2004; 10: 1248-1255.
5. Thuluvath PJ, Yoo HY. Graft and patient survival after adult live donor liver transplantation compared to a matched cohort who received a deceased donor transplantation. Liver Transpl 2004; 10: 1263-1268.
6. Abt PL, Mange KC, Olthoff KM, Markmann JF, Reddy KR, Shaked A. Allograft survival following adult-to-adult living donor liver transplantation. Am J Transplant 2004; 4: 1302-1307.
7. Malago M, Testa G, Frilling A, Nadalin S, Valentin-Gamazo C, Paul A, Lang H, Treichel U, Cicinnati V, Gerken G, Broelsch CE. Right living donor liver transplantation: an option for adult patients: single institution experience with 74 patients. Ann Surg 2003; 238: 853-862.
8. Olthoff KM, Merion RM, Ghobrial RM, Abecassis MM, Fair JH, Fisher RA, Freise CE, Kam I, Pruett TL, Everhart JE, Hulbert-Shearon TE, Gillespie BW, Emond JC; A2ALL Study Group. Outcomes of 385 adult-to-adult living donor liver transplant recipients: a report from the A2ALL Consortium. Ann Surg 2005; 242: 314-325.
9. Maluf DG, Stravitz RT, Cotterell AH, Posner MP, Nakatsuka M, Sterling RK, Luketic VA, Shiffman ML, Ham JM, Marcos A, Behnke MK, Fisher RA. Adult living donor versus deceased donor liver transplantation: a 6-year single center experience. Am J Transplant 2005; 5: 149-156.
10. Akamatsu N, Sugawara Y, Tamura S, Imamura H, Kokudo N, Makuuchi M. Regeneration and function of hemiliver graft: right versus left. Surgery 2006; 139: 765-772.
11. Terrault NA, Shiffman ML, Lok AS, Saab S, Tong L, Brown RS Jr, Everson GT, Reddy KR, Fair JH, Kulik LM, Pruett TL, Seeff LB; A2ALL Study Group. Outcomes in hepatitis C virus-infected recipients of living donor vs. deceased donor liver transplantation. Liver Transpl 2007; 13: 122-129.
12. Russo MW, LaPointe-Rudow D, Kinkhabwala M, Emond J, Brown RS Jr. Impact of adult living donor liver transplantation on waiting time survival in candidates listed for liver transplantation. Am J Transplant 2004; 4: 427-431.
13. Liu CL, Fan ST, Lo CM, Wei WI, Yong BH, Lai CL, Wong J. Live-donor liver transplantation for acute-on-chronic hepatitis B liver failure. Transplantation 2003; 76: 1174-1179.
14. Liu CL, Fan ST, Lo CM, Wei WI, Chan SC, Yong BH, Wong J. Operative outcomes of adult-to-adult right lobe live donor liver transplantation: a comparative study with cadaveric whole-graft liver transplantation in a single center. Ann Surg 2006; 243: 404-410.
15. Liu CL, Lam B, Lo CM, Fan ST. Impact of right-lobe live donor liver transplantation on patients waiting for liver transplantation. Liver Transpl 2003; 9: 863-869.
16. Russo MW, Brown RS Jr. Adult living donor liver transplantation. Am J Transplant 2004; 4: 458-465.
17. Shah SA, Levy GA, Greig PD, Smith R, McGilvray ID, Lilly LB, Girgrah N, Cattral MS, Grant DR. Reduced mortality with right-lobe living donor compared to deceased-donor liver transplantation when analyzed from the time of listing. Am J Transplant 2007; 7: 998-1002.
18. Dumortier J, Adham M, Ber C, Boucaud C, Bouffard Y, Delafosse B, Sagnard P, Boillot O. Impact of adult-to-adult living donor liver transplantation on access to transplantation and patients' survival: an 8-year single-center experience. Liver Transpl 2006; 12: 1770-1775.
19. Shimada M, Shiotani S, Ninomiya M, Terashi T, Hiroshige S, Minagawa R, Soejima Y, Suehiro T, Sugimachi K. Characteristics of liver grafts in living-donor adult liver transplantation: comparison between right- and left-lobe grafts. Arch Surg 2002; 137: 1174-1179.
20. Soejima Y, Taketomi A, Yoshizumi T, Uchiyama H, Harada N, Ijichi H, Yonemura Y, Shimada M, Maehara Y. Feasibility of left lobe living donor liver transplantation between adults: an 8-year, single-center experience of 107 cases. Am J Transplant 2006; 6(5 Pt 1): 1004-1011.
21. Akamatsu N, Sugawara Y, Kaneko J, Sano K, Imamura H, Kokudo N, Makuuchi M. Effects of middle hepatic vein reconstruction on right liver graft regeneration. Transplantation 2003; 76: 832-837.
22. Chan SC, Fan ST, Lo CM, Liu CL. Effect of side and size of graft on surgical outcomes of adult-to-adult live donor liver transplantation. Liver Transpl 2007; 13: 91-98.
23. Inomoto T, Nishizawa F, Sasaki H, Terajima H, Shirakata Y, Miyamoto S, Nagata I, Fujimoto M, Moriyasu F, Tanaka K, Yamaoka Y. Experiences of 120 microsurgical reconstructions of hepatic artery in living related liver transplantation. Surgery 1996; 119: 20-26.
24. Liu CL, Lo CM, Chan SC, Tso WK, Fan ST. The right may not be always right: biliary anatomy contraindicates right lobe live donor liver transplantation. Liver Transpl 2004; 10: 811-812.
25. Cheng SJ, Pratt DS, Freeman RB Jr, Kaplan MM, Wong JB. Living-donor versus cadaveric liver transplantation for non-resectable small hepatocellular carcinoma and compensated cirrhosis: a decision analysis. Transplantation 2001; 72: 861-868.
26. Sarasin FP, Majno PE, Llovet JM, Bruix J, Mentha G, Hadengue A. Living donor liver transplantation for early hepatocellular carcinoma: A life-expectancy and cost-effectiveness perspective. Hepatology 2001; 33: 1073-1079.
27. Valentin-Gamazo C, Malago M, Karliova M, Lutz JT, Frilling A, Nadalin S, Testa G, Ruehm SG, Erim Y, Paul A, Lang H, Gerken G, Broelsch CE. Experience after the evaluation of 700 potential donors for living donor liver transplantation in a single center. Liver Transpl 2004; 10: 1087-1096.
28. Verna EC, Hunt KH, Renz JF, Rudow DL, Hafliger S, Dove LM, Kinkhabwala M, Emond JC, Brown RS Jr. Predictors of candidate maturation among potential living donors. Am J Transplant 2005; 5: 2549-2554.
29. Lo CM, Fan ST, Liu CL, Chan SC, Wong J. The role and limitation of living donor liver transplantation for hepatocellular carcinoma. Liver Transpl 2004; 10: 440-447.
30. Kulik L, Abecassis M. Living donor liver transplantation for hepatocellular carcinoma. Gastroenterology 2004; 127(5 Suppl 1): S277-S282.
31. Lo CM, Fan ST, Liu CL, Chan SC, Ng IO, Wong J. Living donor versus deceased donor liver transplantation for early unresectable hepatocellular carcinoma. Br J Surg 2007; 94: 78-86.

32. Fisher RA, Kulik LM, Freise CE, Lok AS, Shearon TH, Brown RS Jr, Ghobrial RM, Fair JH, Olthoff KM, Kam I, Berg CL; and the A2ALL Study Group. Hepatocellular carcinoma recurrence and death following living and deceased donor liver transplantation. Am J Transplant 2007; 7: 1601-1608.
33. Marsh JW, Finkelstein SD, Demetris AJ, Swalsky PA, Sasatomi E, Bandos A, Subotin M, Dvorchik I. Genotyping of hepatocellular carcinoma in liver transplant recipients adds predictive power for determining recurrence-free survival. Liver Transpl 2003; 9: 664-671.
34. Kamiyama T, Takahashi M, Nakagawa T, Nakanishi K, Kamachi H, Suzuki T, Shimamura T, Taniguchi M, Ozaki M, Matsushita M, Furukawa H, Todo S. AFP mRNA detected in bone marrow by real-time quantitative RT-PCR analysis predicts survival and recurrence after curative hepatectomy for hepatocellular carcinoma. Ann Surg 2006; 244: 451-463.
35. Cheung ST, Fan ST, Lee YT, Chow JP, Ng IO, Fong DY, Lo CM. Albumin mRNA in plasma predicts post-transplant recurrence of patients with hepatocellular carcinoma. Transplantation – in press.
36. Liu CL, Fan ST, Cheung ST, Lo CM, Ng IO, Wong J. Anterior approach versus conventional approach right hepatic resection for large hepatocellular carcinoma: a prospective randomized controlled study. Ann Surg 2006; 244: 194-203.
37. Man K, Fan ST, Lo CM, Liu CL, Fung PC, Liang TB, Lee TK, Tsui SH, Ng IO, Zhang ZW, Wong J. Graft injury in relation to graft size in right lobe live donor liver transplantation: a study of hepatic sinusoidal injury in correlation with portal hemodynamics and intragraft gene expression. Ann Surg 2003; 237: 256-264.
38. Yang ZF, Poon RT, Luo Y, Cheung CK, Ho DW, Lo CM, Fan ST. Up-regulation of vascular endothelial growth factor (VEGF) in small-for-size liver grafts enhances macrophage activities through VEGF receptor 2-dependent pathway. J Immunol 2004; 173: 2507-2515.
39. Man K, Lo CM, Lee TK, Li XL, Ng IO, Fan ST. Intragraft gene expression profiles by cDNA microarray in small-for-size liver grafts. Liver Transpl 2003; 9: 425-432.
40. Drixler TA, Vogten MJ, Ritchie ED, van Vroonhoven TJ, Gebbink MF, Voest EE, Borel Rinkes IH. Liver regeneration is an angiogenesis- associated phenomenon. Ann Surg 2002; 236: 703-712.
41. Chao SD, Roberts JP, Farr M, Yao FY. Short waitlist time does not adversely impact outcome following liver transplantation for hepatocellular carcinoma. Am J Transplant 2007; 7: 1594-1600.
42. Hwang S, Lee SG, Joh JW, Suh KS, Kim DG. Liver transplantation for adult patients with hepatocellular carcinoma in Korea: comparison between cadaveric donor and living donor liver transplantations. Liver Transpl 2005; 11: 1265-1272.
43. Todo S, Furukawa H; Japanese Study Group on Organ Transplantation. Living donor liver transplantation for adult patients with hepatocellular carcinoma: experience in Japan. Ann Surg 2004; 240: 451-461.
44. Takada Y, Ito T, Ueda M, Egawa H, Tanaka K. Living donor liver transplantation for patients with HCC – Single center experience with 114 cases. Hepatogastroenterology 2005; 52(Suppl I): A132.
45. Soejima Y, Taketomi A, Yoshizumi T, Uchiyama H, Aishima S, Terashi T, Shimada M, Maehara Y. Extended indication for living donor liver transplantation in patients with hepatocellular carcinoma. Transplantation 2007; 83: 893-899.
46. Jonas S, Mittler J, Pascher A, Schumacher G, Theruvath T, Benckert C, Rudolph B, Neuhaus P. Living donor liver transplantation of the right lobe for hepatocellular carcinoma in cirrhosis in a European center. Liver Transpl 2007; 13: 896-903.
47. Gondolesi GE, Roayaie S, Munoz L, Kim-Schluger L, Schiano T, Fishbein TM, Emre S, Miller CM, Schwartz ME. Adult living donor liver transplantation for patients with hepatocellular carcinoma: extending UNOS priority criteria. Ann Surg 2004; 239: 142-149.
48. Barr ML, Belghiti J, Villamil FG, Pomfret EA, Sutherland DS, Gruessner RW, Langnas AN, Delmonico FL. A report of the Vancouver Forum on the care of the live organ donor: lung, liver, pancreas, and intestine data and medical guidelines. Transplantation 2006; 81: 1373-1385.
49. Marubashi S, Dono K, Nagano H, Sugita Y, Asaoka T, Hama N, Miyamoto A, Takeda Y, Umeshita K, Monden M. Detection of AFP mRNA-expressing cells in the peripheral blood for prediction of HCC recurrence after living donor liver transplantation. Transpl Int 2007; 20: 576-582.
50. Yang SH, Suh KS, Lee HW, Cho EH, Cho JY, Cho YB, Kim IH, Yi NJ, Lee KU. A revised scoring system utilizing serum alphafetoprotein levels to expand candidates for living donor transplantation in hepatocellular carcinoma. Surgery 2007; 141: 598-609.
51. Yang SH, Suh KS, Lee HW, Cho EH, Cho JY, Cho YB, Yi NJ, Lee KU. The role of (18)F-FDG-PET imaging for the selection of liver transplantation candidates among hepatocellular carcinoma patients. Liver Transpl 2006; 12: 1655-1660.
52. Cillo U, Vitale A, Bassanello M, Boccagni P, Brolese A, Zanus G, Burra P, Fagiuoli S, Farinati F, Rugge M, D'Amico DF. Liver transplantation for the treatment of moderately or well-differentiated hepatocellular carcinoma. Ann Surg 2004; 239: 150-159.
53. Luo Y, Lo CM, Cheung CK, Lau GK, Fan ST, Wong J. Identification of hepatitis B virus-specific lymphocytes in human liver grafts from HBV-immune donors. Liver Transpl 2007; 13: 71-79.
54. Lo CM, Fung JT, Lau GK, Liu CL, Cheung ST, Lai CL, Fan ST, Wong J. Development of antibody to hepatitis B surface antigen after liver transplantation for chronic hepatitis B. Hepatology 2003; 37: 36-43.
55. Zimmerman MA, Trotter JF. Living donor liver transplantation in patients with hepatitis C. Liver Transpl 2003; 9: S52-S57.
56. Garcia-Retortillo M, Forns X, Llovet JM, Navasa M, Feliu A, Massaguer A, Bruguera M, Fuster J, Garcia-Valdecasas JC, Rimola A. Hepatitis C recurrence is more severe after living donor compared to cadaveric liver transplantation. Hepatology 2004; 40: 699-707.
57. Guo L, Orrego M, Rodriguez-Luna H, Balan V, Byrne T, Chopra K, Douglas DD, Harrison E, Moss A, Reddy KS, Williams JW, Rakela J, Mulligan D, Vargas HE. Living donor liver transplantation for hepatitis C-related cirrhosis: no difference in histological recurrence when compared to deceased donor liver transplantation recipients. Liver Transpl 2006; 12: 560-565.
58. Schmeding M, Neumann UP, Puhl G, Bahra M, Neuhaus R, Neuhaus P. Hepatitis C recurrence and fibrosis progression are not increased after living donor liver transplantation: a single-center study of 289 patients. Liver Transpl 2007; 13: 687-692.
59. Carrion JA, Forns X. Living donor liver transplantation and hepatitis C: lessons from the learning curve? Liver Transpl 2007; 13: 18-20.

Index

A
Abdominal distension, 22, 46
Abscess, 38, 103, 118
Accelerated immune reaction, 109
Acquired factor V deficiency, 63
Activated protein C resistance, 10
Acyclovir, 24
Adhesion molecules, 109, 111
Adiponectin, 111
Adrenal gland, 40, 51, 56, 67
Alagille syndrome, 16
Alanine aminotransferase (ALT), 16, 52, 79, 115, 116, 121, 129
Albumin, 22, 46, 52, 73
Allograft inflammatory factor-1, 110
Alpha1-antitrypsin, 10
ALT. *See* Alanine aminotransferase (ALT)
Ampulla, 99, 102
Anaphylaxis, 15, 18
Anastomosis,13, 32, 37, 39, 40, 42-45, 50, 51, 55, 57, 59, 65, 67, 69-72, 78, 79, 85, 89, 90, 99, 101-104
  arterial, 43, 45
  continuous, 100
  duct-to-duct, 45, 50, 51, 66, 72, 98-100, 102, 103, 105
  hepatic artery, 45, 51, 71, 73
  intrahepatic venous, 77
  portal vein, 42, 44, 51, 70, 73
  venoportal, 44
Anatomy, 2, 7, 12, 59, 76, 79, 85, 89, 117
  biliary, 15, 28, 91, 93, 105
  biliary tract, 28, 91
  hepatic artery, 12, 15
  hepatic duct, 34, 93
  hilar, 4
  portal vein, 13
Anemia, 9
Anesthesia, 16, 23, 27, 47, 119, 120
Angiogenesis, 109, 131
Antibiotic, 35, 45, 50, 53, 64, 72, 73, 120
  prophylactic, 27, 47, 117
Anticoagulant, 53
AntiHCV. *See* Hepatitis C antibody (AntiHCV)
Antimitochondrial antibody, 10
Antinuclear antibody, 10
Antiphospholipid antibodies, 10
Antithrombin III, 10
Anti-tuberculosis drugs, 9
Anti-viral prophylaxis, 9
Apolipoprotein, 10
Artery, 11-13, 15, 29, 30, 32, 38, 39, 45, 47, 50, 51, 57, 62, 65-71, 73, 78, 82, 85, 103-105, 110, 112, 118, 120, 130
  gastroduodenal, 71, 89
  gastroepiploic, 71
  left gastric, 11, 12, 89
  left hepatic (LHA), 2, 11-13, 27, 29, 30-32, 47-51, 57, 66, 67, 71, 89, 100
  radial, 71
  right gastric, 89
  right hepatic (RHA), 11-13, 50, 51, 53, 54, 56, 57, 59, 62, 66, 67, 71, 89, 90, 98, 100
  segment II/III hepatic, 12
  segment IV hepatic, 12, 13, 53, 54
  superior mesenteric, 12, 13
Ascites, 14, 46, 52, 72, 73, 83, 107, 117, 118
Aspartate aminotransferase (AST), 16, 52, 79, 84, 115, 116, 121, 127, 129
AST. *See* Aspartate aminotransferase (AST)
Atresia,
  biliary, 1, 22, 38, 39, 41, 42, 43, 45
  portal vein, 43
Avulsion, 41, 59

B
Benzafibrate, 17
Biliary stricture, 115, 128
Bilioscopin, 16, 91
Blood transfusion, 73, 114, 118, 119, 124, 127
BMI. *See* Body mass index (BMI)
Body mass index (BMI), 9, 16, 114
Brain-dead deceased donor, 22
Branched-chain amino acid-enriched solution, 120

C
Cannula, 34, 49, 54, 64
  cystic duct, 33, 51, 53, 64, 72
  Fr 3.5, 50
  nasal, 72
Cannulation, cystic duct, 27, 50, 101
Cantlie line, 57, 76
Caroli's disease, 1
Catheter, 32, 53, 65, 118, 119
  balloon, 92, 96
  central venous, 72, 73
  cholangiography, 28
  fine, 31, 35
  Fr 3.5 Argyle, 27, 47
  pulmonary artery, 73
  urinary, 72
Cellcept. *See* MMF (Cellcept)

Central venous pressure, 44, 48, 53, 62, 72, 119
Ceruloplasmin, 10
Cholangiogram, 15, 16, 28, 30, 31, 33, 34, 49, 50, 53, 54, 59, 61, 62, 66, 72, 90-101, 104
Cholangiography, 16, 23, 27, 28, 30, 34, 47, 51, 91, 96
Choledochoscopy, 99
Choledochotomy, 93
Chronic active hepatitis acute flare, 85, 128
Chronic hepatitis B, 2, 22, 127, 129
Chronic liver disease, 9, 10, 128
Circulation, 45
  retroperitoneal, 42
  splanchnic, 68
  systemic, 78
Cirrhosis, 22, 78, 79, 84, 128, 129
  biliary, 2, 96, 118
  hepatitis C, 133
Clamp, 28, 32, 38, 41, 42, 51, 61, 63, 68-70, 98
  Acland microvascular, 38, 39, 50, 71
  atraumatic bulldog vascular, 28, 30
  atraumatic vascular, 53
  Blalock vascular, 50, 51, 68
  bulldog vascular, 28, 32, 42, 47, 51, 54, 62, 63, 70
  right-angle, 48, 66
  Satinsky vascular, 68, 69
  thin-blade, 70
  Ulrich-Swiss, 51, 68
  vascular, 32, 33, 35, 38, 41, 42, 51, 61, 63, 66-70, 72
Clamp crushing technique, 61
Classification,
  Clavien, 115, 116
  Nakamura, 82
Coagulation, 10, 46, 61, 99, 102, 109
  argon beam, 56, 63, 95
  congenital abnormalities of, 9
  tissue, 45
Coagulopathy, 104, 107
Cold ischemic time, 16, 112, 127
Collaterals, 41, 45, 56, 77, 81, 89
Colonoscopy, virtual, 9
Complication, 7, 16, 18, 22-24, 73, 103, 104, 115-119
  bile duct, 24
  biliary, 30, 89, 99, 100, 101, 104, 105, 126, 128
  operative, 9
  postoperative hepatic artery, 104
  postoperative, 11, 115, 119, 129
  rate, 7, 9, 19, 22-26, 72, 80, 89-101, 105, 115, 117
Computed tomography (CT), 8, 11-13, 15, 16, 23, 28, 29, 35, 39, 46, 49, 55, 56, 67, 71, 75-79, 81-83, 85, 91, 104, 107, 120, 121
Congestion, 15, 41, 45, 51, 55, 56, 63, 64, 75, 77, 80, 82, 86, 110
  bowel, 39, 51, 68
  graft, 55, 77, 124
  sinusoidal, 107
Congested volume, 3
Creatinine, 22, 120, 121, 125
Cross-clamping, 30
CT. *See* Computed tomography (CT)
Cytomegalovirus, 8, 9, 24, 104

D

DDLT. *See* Deceased donor liver transplantation (DDLT)
Deceased donor liver transplantation (DDLT), 1, 66, 73, 79, 84, 89, 125-128, 130-133
Deep vein thrombosis, 8, 9, 27, 47, 53, 117, 118
Demarcation line, 48, 56, 60
Donation, 3, 4, 7-11, 13-18, 22-27, 45, 85, 91, 121, 130
  autologous blood, 53
  deceased liver, 1
  left liver, 1, 115, 129
  living kidney, 7, 121
  organ, 1, 10, 22, 24
  right liver, 2, 12, 14, 86, 129, 130
Donor death, 16, 23, 116, 121
Donor operation, 2, 7, 9, 10, 12, 13, 16, 18, 19, 23, 25-27, 29, 35, 37, 47, 49, 53, 66, 75, 115, 119, 120, 121, 130
Donor safety, 3, 4, 86
Donor selection, 4, 86, 91
Donor workup, 8, 18
Doppler signal, 71
Doppler ultrasonography, 13, 27, 44, 45, 52, 54, 63, 69, 72, 73, 77, 120, 130
Double inferior vena cava (IVC) technique, 85
Drainage, 50, 76, 80, 84, 86, 104, 119
  abdominal, 35, 51
  venous, 27, 38, 48, 59-61, 75, 76, 79, 80, 82, 83, 86, 89, 129, 133
Dual-graft operation, 16
Duct, 15, 28, 30, 31, 33, 34, 49, 50, 53, 54, 59, 60, 62, 67, 90-104, 119
  bile, 23, 24, 32, 64, 93, 95, 96, 117, 118, 121
  caudate hepatic, 31, 49, 60, 67, 95, 98
  common bile, 28, 30, 33, 45, 47, 53, 54, 64, 72, 92-94, 96, 99
  common hepatic, 16, 28, 30, 31, 50, 51, 53, 54, 66, 67, 90, 92, 93, 95, 96, 98, 100, 101
  cystic, 23, 27, 28, 33, 47, 50, 51, 53, 54, 64, 66, 72, 90, 91, 94, 99, 101
  intrahepatic, 28, 30, 34, 47, 53, 91-93, 104
  left hepatic (LHD), 18, 27, 30, 31, 33, 34, 47, 48, 53, 54, 89, 91-93, 95, 96
  right hepatic (RHD), 13, 15, 17, 18, 30, 33, 34, 53, 54, 62, 89-91, 94, 95, 97, 99, 100, 103
Ductoplasty, 72, 99, 102
Ductus venosum, 30-32, 35, 41, 48, 68
Duodenal ulcer, 115, 117, 118

E

Early growth response-1, 109
Elderly donors, 7
Electrocardiogram, 8, 12
Electrocautery, 29, 30, 63
Electron microscopy, 108, 109
Encephalopathy, 107, 118
Encrustation, 101, 102
Endoscopic retrograde cholangiopancreatography (ERCP), 16, 104

Endothelial cells, 108, 109
Endothelial denudation, 107
Endothelin-1, 109
Endothelium, 45, 131
ERCP. *See* Endoscopic retrograde cholangiopancreatography (ERCP)
ESLV. *See* Estimated standard liver volume (ESLV)
ESLW. *See* Estimated standard liver weight (ESLW)
Estimated standard liver volume (ESLV), 2, 13, 14, 79, 85, 107, 111, 112, 127
Estimated standard liver weight (ESLW), 13, 14, 86, 107, 124, 128, 130, 131
Exacerbated inflammatory response, 109

F

Factor II gene mutation, 10
Factor V Leiden, 10
Fatty change, 4, 16, 17, 89
Fatty liver, 4, 9, 16, 17
Ferritin, 10
Fibrin glue spray, 63
Fibroblast replication, 104
Fibrosis, 1, 101, 104
Fistula,
  arterio-portal, 104
  arterio-venous, 18
  duodeno-caval, 115, 117, 118
FK409, 111
FK506 (Tacrolimus), 24, 45, 52
Flk-1-dependent macrophage migration, 109
Fluconazole, 24
Fluid collection, 22, 45
Fluid deficit, 73
Fluid retention, 14, 73, 120
Fresh frozen plasma, 73, 119, 127
FTY720, 111
Fulminant hepatic failure, 2, 84, 85, 127-129
Fulminant Wilson disease, 2

G

Gilbert's syndrome, 16
Graft, 1-4, 7, 11, 13, 15, 16, 18, 22-24, 27, 30, 32, 33, 37, 39, 42-45, 47-52, 55, 58, 59, 62, 63, 65, 68-72, 77-79, 82, 86, 90, 92-97, 99-104, 107, 108, 110-112, 114, 118, 119, 124-133
  congestion, 55, 77, 124
  hypoperfusion, 112
  implantation, 16, 65, 112
  left liver, 2, 47-49, 51, 52, 75, 96, 100, 124, 125, 128-130
  liver, 1, 9, 14, 16, 18, 22-24, 32, 37-39, 41-45, 49-51, 59, 63, 65-68, 70, 75, 86, 99, 104, 107-110, 112, 124, 125, 130, 131, 133
  living donor liver, 1, 9, 89, 107, 108, 125, 132
  loss, 65, 78, 110
  quality, 4, 111, 112
  right liver, 2, 3, 11-13, 15, 48, 52, 53, 59-62, 65, 67, 69, 72, 75, 77-82, 84-86, 90, 114, 121, 124, 125, 128-130, 133
  segment II and III, 1, 27, 30, 32, 33, 35-37, 42, 47, 49
  side, 13, 32, 49, 62, 63, 70, 71, 95, 97
  size, 2, 14, 16, 52, 78, 83, 86, 107, 108, 110-112, 124, 126, 128
  small-for-size, 45, 78, 107-112, 131, 134
  weight, 13, 14, 79, 85, 107, 124, 127, 128
Groove, 49
  inferior vena cava (IVC), 65
  Rouviere, 55
Growth failure, 22

H

H_2-receptor antagonist, 27, 45, 47, 53, 117
Harmonic scalpel, 61
HBcAb. *See* Hepatitis B core antibody (HBcAb)
HBIG. *See* Hepatitis B immunoglobulin (HBIG)
HBV DNA, 9, 133
HCC. *See* Hepatocellular carcinoma (HCC)
Heart disease, ischemic, 8
Hematoma, 29, 120
  perihepatic, 73
  subcapsular, 77
  wound, 119
Heme oxygenase-1, 111
Hemobilia, 18, 104
Hemodialysis, 1, 73, 128
Hemofiltration, veno-venous, 73, 120
Hemoperitoneum, 115, 117
Hemostasis, 42, 51, 56, 60, 63, 72, 86, 95, 104, 119
Heparinization, 63
Heparin-saline, 51, 69
Hepatectomy, 8, 9, 26, 40, 41, 48, 62, 117, 119, 120, 121, 131
  donor, 9, 23, 25, 62, 117, 119, 132
  laparoscopic donor, 4
  left, 2, 129
  left liver donor, 114
  major, 7, 9, 120
  right, 2, 58, 61, 80, 115
  right liver donor, 17, 121
Hepatic angiography, 15
Hepatic arteriogram, 23
Hepatic coma, 22
Hepatico-jejunostomy, 51, 72, 96, 99, 102-105
Hepatitis B core antibody (HBcAb), 8, 9
Hepatitis B immunoglobulin (HBIG), 132, 133
Hepatitis B surface antibody, 8, 9, 133
Hepatitis B surface antigen, 8, 9, 132, 133
Hepatitis B, 2, 9, 18, 22-24, 127, 129, 132, 133
Hepatitis C antibody (AntiHCV), 8, 9
Hepatitis C, 8, 9, 22, 23, 133
Hepatitis virus, 9
Hepatocellular carcinoma (HCC), 22, 68, 111, 125, 127, 130-132
Hepatocyte ballooning, 107
Hepatocytes, 108, 109
Hepatorenal syndrome, 128
Herbal medicine, 16
Hernia, 23, 118
  incision, 116-118
Herniation, 40, 42

Hilar plate, 13, 30, 31, 33, 48-50, 57-61, 64, 66, 67, 89, 90, 93, 95, 98, 104
Histidine-tryptophan-ketoglutarate (HTK) solution, 32, 49, 65
HIV. *See* Human immunodeficiency virus (HIV)
Hospital mortality, 7, 79, 85, 117, 124, 125, 128, 129
HTK. *See* Histidine-tryptophan-ketoglutarate (HTK) solution
Human immunodeficiency virus (HIV), 8, 9, 23
Human leukocyte antigen typing, 8
Human Organ Transplant Board, 7, 10, 18, 23
Hyperbilirubinemia, 16, 104, 129
Hypercholesterolemia, 9
Hyperlipidemia, 9
Hypersplenism, 121
Hypertension, 8, 24
  portal, 3, 78, 83, 111, 112, 128
Hypertrophy, 78
Hypotension, 104
Hypothermia, 27, 47, 124, 125

I

Ileus, 46, 73, 118, 119
Immunosuppressive,
  medications, 22, 24
  protocol, 24, 45, 52
Incentive spirometry, 72, 120
Indocyanine green clearance test, 10
Inducible nitric oxide synthase, 110, 111
Infection, 8, 22-24, 46, 57, 63, 68, 72, 73, 117, 119, 132, 133
  candida, 24
  chest, 72
  cytomegalovirus, 24, 104
  hepatitis B, 9, 127
  occult, 9, 73
  pulmonary, 8
  wound, 9, 23, 24, 35, 50, 64, 117
Inferior vena cava (IVC), 14, 29, 30, 32, 36, 38-42, 44, 45, 47-51, 55, 56, 59, 61, 63, 65, 67-70, 72, 76, 82, 84, 85, 95, 99, 110, 112, 119, 131
  infrahepatic, 39, 42, 51, 68, 69
  retrohepatic, 57
  suprahepatic, 27, 29, 38, 41, 42, 47, 51, 53, 68
Infiltration, 107-110
Inflammatory cells, 107
Inflow vasculature, 38
Informed consent, 1, 8, 17, 18
Inhibitor,
  calcineurin, 73
  cyclooxygenase-2, 119
  proton pump, 45, 72
Injury, 14-16, 30, 32, 38, 41, 45, 47-49, 53, 65, 83, 90, 92, 95, 96, 100, 107-112, 118-131
  brachial plexus, 27, 47, 53, 118
  hyperdynamic, 78
  ischemic, 38, 47, 53, 55, 130
  ischemia-reperfusion, 16, 65, 107-109
  mechanical, 109
  shear stress, 45, 109
  small-for-size graft, 48, 107-111, 131
  thermal, 95
  traction, 104
Inotropes, 73
INR. *See* International normalized ratio (INR)
Insulin infusion, 73
Intensive care unit, 18, 22-24, 45, 51, 72, 73, 114, 120, 124, 126-129
Interleukin-10, 110, 111
Interleukin-2 receptor antagonist, 45, 52
International normalized ratio (INR), 8, 9, 22, 45, 52, 59, 72, 73, 79, 82, 86, 120, 129
Intrahepatic recurrence, 131
Iodipamide meglumine, 91
Ischemia, 31, 65, 99, 104, 108, 112, 120, 133
  duct, 101
Ischemic time, 16, 104, 112, 127
Ischemia-reperfusion, 16, 65, 107-109, 111
Ischemic heart disease, 8
IVC. *See* Inferior vena cava (IVC)

J

Jaundice, 1, 22, 103, 107
Jehovah's Witness patients, 3
Jejunojejunostomy, 38, 102
Jejunum, 45, 102, 103

K

Karnofsky Performance Scale, 121
Kasai operation, 38
Kidney disease, 8
Kidney transplantation, 7
Kupffer cells, 109

L

Lamivudine, 9, 24, 132, 133
Laparoscopy, 23
Laparotomy, 13, 17, 23, 46, 52, 73, 91, 103-105, 118, 120
LDLT. *See* Living donor liver transplantation (LDLT)
Leakage, 49-51, 64, 95, 101, 102, 104, 105, 118
  bile, 23, 27, 31, 33, 38, 50, 60, 61, 63, 64, 66, 67, 72, 73, 86, 90, 93-95, 98, 99, 103, 104, 118, 119
  biliary, 89, 90, 101, 128
Left lateral sector, 29
Left lateral segment, 23
Leukocytes, 109
LHA. *See* Artery, left hepatic (LHA)
LHD. *See* Duct, left hepatic (LHD)
LHV. *See* Vein, left hepatic (LHV,)
Liga clip, 27, 30, 33, 34, 37, 47, 53, 62, 63, 66, 91-93
Ligament, 40, 41, 56
  falciform, 27, 28, 30, 33, 64, 76, 119
  hepatoduodenal, 42, 66-68, 104, 131
  inferior vena cava (IVC), 40, 50, 56, 67
  triangular, 27, 29, 39, 48, 55, 67
LigaSure, 61
Ligation, 14, 29, 31, 32, 38, 44, 46, 56, 60, 66

splenic artery, 110, 112,
Liver failure, 9, 18, 23, 25, 26, 38, 64, 72, 77, 118, 120, 128
acute,18, 22, 128
acute-on-chronic, 78
chronic, 18
Liver biopsy, 8, 16, 18, 19, 23, 120
Liver hilum, 13, 27, 37, 38, 45, 46, 50, 51, 53, 54, 56, 57, 59, 66, 73, 76, 89, 92, 95, 98, 100, 105, 119, 120, 130
Liver parenchyma, 31, 48, 58, 77, 89, 121
Liver regeneration, 16, 56, 73, 80, 86, 109, 111, 120, 121, 129, 131
Liver remnant, 9, 12, 15, 17, 23, 38, 45, 49, 52, 72, 75, 80, 82, 119-121
Liver rotation, 55, 56, 64, 119
Liver segments, 1, 4, 14
Liver size, 14, 107
Liver tissue, 37, 41, 56-58, 61, 89, 90
Liver transection, 13, 14, 23, 27-33, 35, 37, 47-50, 55-59, 61-65, 71, 73, 89, 90, 95, 104, 117, 119, 124
Living donor liver transplantation (LDLT), 1-4, 7, 8, 11, 14, 16, 18, 19, 23-26, 28, 68, 70, 73, 75, 79, 83, 84, 86, 89, 102, 103, 107, 108, 111, 121, 124-128, 130-133
LPV. *See* Vein, left portal (LPV)

M

Magnetic resonance cholangiopancreatography (MRCP), 15, 16, 91
Magnetic resonance imaging (MRI), 15, 18, 77, 86
Malignancy, 8-10
Medium-chain triglyceride, 120
Meglumine iotroxate, 91
MELD. *See* Model for End-stage Liver Disease (MELD)
Mental illness, 8
Mesenteric gap, 102
Mesentery, 103
Mesocolon window, 102
Metabolic acidosis, 120
Metabolic demand, 78, 86, 121, 128
Methylene blue, 33, 49, 51, 64, 72, 90, 95, 99, 105
MeVis software, 15, 16, 91
MHV. *See* Vein, middle hepatic (MHV)
Microvascular surgery technique, 1, 72
Microvilli, 108, 109
Milan criteria, 132
Mitochondrial swelling, 108, 109
MMF (Cellcept), 24
Model for End-stage Liver Disease (MELD), 22, 23, 78, 85, 104, 110, 124, 126-130
Molecular Adsorbent Recirculation System, 73, 120
Morbidity, 7, 9, 15, 17, 19, 115, 117, 128
Mortality rate, 7, 11, 78, 115-117, 124, 125
MPV. *See* Vein, main portal (MPV)
MRCP. *See* Magnetic resonance cholangiopancreatography (MRCP)
MRI. *See* Magnetic resonance imaging (MRI)
Mycophenolate mofetil, 52
Myocardial disease, 18

N

Nausea, 72, 119
Necrosis, 53, 73, 101, 104, 108, 111, 120
Necrotizing fasciitis, 9
Neonates, 2
Nephropathy, 15, 18
Nephrotoxic agents, 73
Nephrotoxicity, 15
Nystatin, 24

O

Obese donors, 9
Obesity, 9, 111
Obstruction, 44, 69, 102, 111, 112, 118, 133
biliary, 67
intestinal, 64, 115, 117
Occlusion, 13, 32, 37-39, 53, 55, 56, 62, 68, 70, 71, 77, 81, 92, 124
inflow vascular, 30, 48, 58, 61, 62, 119
outflow, 78
Ohm's law, 112
Oliguria, 120
Omega-3 polyunsaturated fatty acid supplementation, 17
Omentum,
greater, 63, 64
lesser, 29, 48, 56, 67
Orifice, 33, 34, 36, 38, 42, 51, 62, 64, 65, 69, 70, 71, 95, 99, 101
cuff, 42
duct, 15, 30, 31, 34, 49, 59, 60, 91, 94, 97, 99, 100, 102, 103
ductal, 31, 49, 72, 93, 96, 97, 99, 100-102, 104
hepatic duct, 15, 30, 34, 49, 59, 90, 91, 94, 97, 100, 102, 103
hepatic vein, 32, 37, 38, 49, 51, 68, 69, 71, 72
single, 13, 14, 29, 65, 70, 100
single duct, 30, 99
Orthotopic liver transplantation, 1
Overweight, 9
Oxygenation, 52, 120

P

Pain relief, 72,119
Pancreas, 39, 47, 53
Parabiliary venous plexus, 89
Paracentesis, 52
Parenteral nutrition, 117, 120
Patency, 71, 73, 86
Pediatric End-stage Liver Disease (PELD), 22, 23
Pediatric patients, 1, 2, 22, 24, 38, 45
Pedicle, 30, 33, 58-61, 63, 93, 95, 98
PELD. *See* Pediatric End-stage Liver Disease (PELD)
Peptic ulcer, 8, 119
Percutaneous transhepatic biliary drainage (PTBD), 104, 105
Perforation, 38, 45, 46, 118
Perfusion, 44, 45, 57, 120
Peridochal tissues, 67, 98
Peritonitis, 17, 18, 22, 38, 133
Phosphate, 16, 120
Platelet concentrate, 119, 127
Platelet count, 9, 73, 119
Pleural effusion, 24, 117, 118
Pneumonia, 23, 24, 118, 133
Portal inflow, 110-112

Portal pressure, 78, 110-112
Portal venous pressure, 110
Position, 13, 24, 27-29, 32-34, 42, 45, 47, 48, 53, 56, 63, 76, 92-99, 130
  Anti-Trendelenburg, 64
  Trendelenburg, 28
Prednisolone, 24
Pregnancy, 2, 8
Premorbid condition, 3, 104
Pressure sores, 24, 47, 53
Primary graft non-function, 24
Pringle maneuver, 61, 62
Pro-inflammatory cytokine, 109
Prothrombin time, 80, 115, 116, 119, 127
Pseudoaneurysm, 103, 104
PTBD. *See* Percutaneous transhepatic biliary drainage (PTBD)
Pulsatility, 44, 69, 71, 72
Pyrexia, 46

R

Reconstruction, 11, 13, 70, 71, 84-86, 104, 105, 112, 125 ,133
  bile duct, 130
  biliary, 45, 51, 72, 97, 104
  duct-to-duct, 104
  hepatic artery, 1, 51
  middle hepatic vein (MHV) tributary, 86
  outflow tract, 44
  portal inflow, 111
  three-dimensional, 8, 12, 15
Renal failure, 24, 73, 118
Reperfusion, 27, 51, 70, 71, 107-110
  hepatic artery, 69, 70, 78, 82
  hepatic vein, 78
  portal vein, 78, 82, 119, 130
Respiratory depression, 119
Retractor, 45, 119, 130
  Bookwalter, 53, 66
  self-retaining, 27, 45, 47, 55
Retroperitoneum, 41, 42, 46, 50, 51
RHA. *See* Artery, right hepatic (RHA)
RHD. *See* Duct, right hepatic (RHD)
RHV. *See* Vein, right hepatic (RHV)
Right anterior sector, 48, 75, 83, 84, 86, 111, 119
Right lateral sector, 3, 4
Right posterior sector, 75, 78, 83
Risk factors, 132
  cardiovascular, 9
RPV. *See* Vein, right portal (RPV)
Rummel tourniquet, 39, 68, 69

S

Seizure, 115, 118
Sepsis, 24, 45, 52, 73, 78, 104, 118, 128
Septrin, 24
Shunt,
  porto-caval, 67, 110
  spontaneous, 45
  superior mesenteric vein-inferior vena cava, 110
Shunting operation, 112
Sinusoidal epithelium, 108
Sinusoids, 109, 111
Sleep apnea, 9
Sludge formation, 102
Small-for-size, 14, 45, 65, 78, 107-112, 131, 134
Smokers, 8
Smooth muscle antibody, 10
Sodium bicarbonate cover, 8, 12
Sodium salicylate, 110
Somatostatin, 110
Space of Disse, 108, 109
Splenectomy, 110, 112
Splenomegaly, 121
Spontaneous bacterial peritonitis, 17, 18, 22
Sputum, 8
Stapler, 27, 37, 38
  vascular, 27, 32, 35, 37, 49, 63
Steatohepatitis, 17, 118
Steatosis, 16, 17, 107, 108
Stenosis, 45, 57, 58, 90, 96-105, 118, 133
Stent, 45, 51, 72, 100, 102
Steroid, 45, 52, 101, 103, 119
Stump, 32-34, 38, 42, 49-51, 62, 63, 67, 68, 90-92, 94, 95, 97, 99, 100, 104, 119
Subcutaneous heparin, 8
Survival rate, 7, 16, 23, 79, 84, 111, 125, 126, 128, 130-133

T

T-tube, 72, 95, 99
Tacrolimus. *See* FK506 (Tacrolimus)
Terminal liver disease, 2
Thrombectomy, 70
Thrombocytopenia, 121
Thrombosis, 1, 8, 9, 24, 27, 39, 41, 43-45, 47, 53, 70, 73, 104 , 112, 115-118, 133
TissueLink, 61
Transposition,
  cavo-portal, 43-45
  portal-caval, 71
Tuberculosis, 8, 9
Tumor necrosis factor-alpha, 111

U

Ultrasonic dissector, 30, 32, 48, 58, 61, 62, 82, 95, 119
Ultrasonography, 13, 16, 27, 44, 45, 47, 52, 54, 56, 57, 63, 69, 71-73, 76, 77, 82, 120, 130
Umbilical fissure, 13, 14, 27-31, 47, 81
United Network for Organ Sharing, 18, 78, 132
University of California San Francisco criteria, 132
Upper endoscopy, 8, 9, 115
Uridine diphosphate glucuronosyltransferase 1, 16
Urinalysis, 8

V

Varicella zoster virus, 8

Vascular endothelial growth factor (VEGF), 109, 110
Vasoconstrictive genes, 109
VEGF. *See* Vascular endothelial growth factor (VEGF)
Vein, 8, 9, 13, 27, 32, 37, 38, 41-43, 47, 49, 50, 53, 55, 56, 58-61, 65, 68, 70, 71, 81, 86, 110 ,117, 118
coronary, 44
diaphragmatic, 68
hepatic, 8, 12, 15, 24, 27-29, 31, 32, 35-40, 42-45, 48-51, 55-61, 63, 65, 67-73, 75-77, 79-82, 84-86, 112, 114, 119, 120, 133
left hepatic (LHV), 27, 29-32, 35, 37, 38, 41, 42, 44, 45, 47-51, 59, 68, 75, 76, 84, 85, 119
left phrenic, 48
left portal (LPV), 13, 14, 29, 31-33, 38, 40-45, 47-49, 51, 59, 63, 67, 68, 70, 84, 130
main portal (MPV), 29, 38, 43, 51, 67, 70
middle hepatic (MHV), 2, 3, 11, 12, 14, 15, 29, 30, 32, 35, 36, 38, 41, 42, 48-51, 53, 56-72, 75-86, 94, 98, 112, 114, 118, 119, 121, 124, 126, 130, 133
phrenic, 41, 48, 51
portal, 8, 13, 14, 24, 29, 32, 33, 35, 38, 39, 41-45, 47, 50, 51, 55, 57, 65, 67, 68, 70, 71, 73, 78, 82, 83, 99, 103, 104, 110, 112, 114-118, 120, 130
right hepatic (RHV), 4, 11, 12, 40-42, 48, 50, 51, 55, 56, 63-70, 72, 76-79, 81, 83, 85, 86, 112
right portal (RPV), 13, 29, 38, 40, 41, 43, 48, 51, 53, 54, 57, 59, 63, 65, 67, 68, 70, 76
saphenous, 84
superficial femoral, 84
umbilical, 27, 28, 75, 76, 80, 81, 84
Venoplasty, 13, 29, 32, 36, 43, 49, 59, 64-66, 68-71, 82, 85, 86, 112
Venous outflow, 78, 79, 86, 111, 112, 124, 125, 128, 130
Veno-venous bypass, 66, 68, 124
Visceral angiogram, 8
Volume, 2-4, 7, 8, 13-15, 17, 47, 48, 52, 62, 76, 79, 86, 107, 110, 111, 114, 119, 121, 124, 127, 129-131
Volunteer, 7, 18
Vomiting, 72, 115, 119
Von Willebrand factor activity, 10

W

Waterjet dissector, 61
Wilson disease, 2, 22
Wound pain, 4, 119, 120

X

Xiphisternum, 27
Xiphoid process, 53, 66